YALE

MEDICAL LIBRARY



Digitized by the Internet Archive
in 2012 with funding from
Open Knowledge Commons and Yale University, Cushing/Whitney Medical Library

http://archive.org/details/workonoperatived00blac



Yours truly
G. V. Black

Black:

A WORK

ON

OPERATIVE DENTISTRY

IN TWO VOLUMES.

VOLUME ONE,

THE PATHOLOGY OF THE HARD TISSUES OF THE TEETH.

GLOSSARY AND INDEX.

---

187 ILLUSTRATIONS.

BY

G. V. BLACK, M.D., D.D.S., Sc.D., LL.D.

DEAN AND PROFESSOR OF OPERATIVE DENTISTRY, DENTAL PATHOLOGY AND BACTERIOLOGY
NORTHWESTERN UNIVERSITY DENTAL SCHOOL.

1908.
MEDICO-DENTAL PUBLISHING COMPANY,
CHICAGO

Entered, according to Act of Congress, in the year 1908,
by G. V. Black,
in the Office of the Librarian of Congress, Washington, D. C.

Entered at Stationers' Hall,
London, Eng.

RK501



THE HENRY O. SHEPARD CO., PRINTERS, CHICAGO.

PREFACE.

The original intention in writing this book was to confine it strictly to a consideration of dental caries and its treatment, but later atrophy and erosion of the teeth were added. Atrophy of the teeth seems now to have been completely made out both as to its causation and the principal forms of the injury to the hard tissues of the teeth, and it was thought best to place this information on record in permanent form. Much of the detail as to these injuries may, however, be discovered in the future. Our information regarding erosion is far from complete and it now seems probable that much time may elapse before its investigation will develop satisfactory results. Its apparent increase in frequency and the great damage it is doing, calls for the closest study that the profession can give.

Otherwise than the presentation of these two conditions, this book will be confined strictly to the consideration of dental caries and its treatment. This comprises the main features of Operative Dentistry, though in fact it is only one department of our daily work at the chair. Diseases of the dental pulp, diseases of the peridental membranes, alveolar abscess, and the whole group of pathological conditions of the soft tissues, are subjects for another volume. The time has passed for including in one book all of the subjects of dentistry.

While I have not been unmindful of the needs of the general practitioner in the preparation of the book, it has been planned especially for use of students in dental schools. The subjects are introduced and carried forward step by step, from the simpler to the more complex, with complete explanations of the nomenclature for the beginner in the work of preparing cavities and filling teeth. In the treatment of this subject, the questions of the pathology of caries applicable to the prevention of recurrence of decay after fillings have been made, and the conditions under which operations should or should not be done, have been repeated often in order to keep these matters constantly before the mind of the student.

In the arrangement of the matter, the logical order usually observed in books has been followed. That is, the pathology has been presented first and the treatment later. This is not

always the best order in teaching, and especially when the subjects are presented in that detail that is necessary to completeness. In order to read most understandingly of the pathology of typhoid fever, for instance, one must have had much practical observation of the disease. The more prominent facts should be obtained first and the more intimate detail added later, when personal observation has given a wider view. In the study of dental caries and its treatment, I have usually preferred to adopt such a plan in teaching. With that view, the second volume would be given to the student first. Following this thought, an outline of the principal points of the pathology involved is usually given with or preceding the treatment of each class of dental caries. In the first study by which the student is prepared for the beginning of the practical observation and treatment of caries, this answers the purpose. The more serious study of the pathology of dental caries is then undertaken later. If this plan is adopted, the first parts of the second volume would be given the student in the operative technic course in the freshman year. This would be reviewed and completed in the junior year. The first volume would then belong to the senior year. The book may be used, however, in either order. In the order as arranged, the more serious study of the pathology coming first, the reminders introduced in the second volume will be of direct advantage.

With but few exceptions, the illustrations are original. Those illustrating the preparation of cavities are reproductions of pictures made by my own brush, and the photographs and photomicrographs have been made by Dr. F. B. Noyes from specimens of my personal preparation from material I have gathered myself, which remained under my personal observation and study during the entire process. I am under especial obligation to Dr. Noyes for the excellent assistance he has given in the photographic work, and to my son, Dr. Arthur D. Black, for very valuable assistance and suggestions in the preparation and arrangement of the manuscript.

G. V. BLACK.

Chicago, Ill., June 22, 1908.

CONTENTS OF VOLUME I.

PATHOLOGY OF THE HARD TISSUES OF THE TEETH.

	PAGE
Introduction	1
Atrophy of the Teeth	6
Etiology	11
Histological Characters in Atrophy of the Teeth	14
Atrophy of the First Permanent Molars	23
Treatment of Atrophied Teeth	25
Pits in the Enamel	30
Other Deformities of the Enamel	32
General Deformity of Enamel	32
White Spots in the Enamel	34
White Enamel	35
Erosion of the Teeth	39
Diagnosis of Erosion	40
Frequence of Erosion	41
Forms of Erosion	42
Etiology of Erosion	49
Treatment of Erosion	57
Caries of the Teeth	60
Historical	60
General Statement	65
Caries of Dentin	68
Caries of Enamel	74
Penetration of Enamel in Pits	76
Penetration of Enamel in Proximal Surfaces of Incisors	77
Superficial Spreading of Caries in Proximal Surfaces of Bicuspids and Molars	81
A Closer Examination of the Injury to the Enamel	83
The Relation of Occlusion to the Localization of Caries	85
Penetration of Enamel in Buccal and Labial Surfaces	90

PAGE

Caries as a Whole. Its Clinical Features 91
Occlusal Surface Decays in Molars 92
Proximal Surface Decays in Molars 93
Occlusal and Proximal Surface Decays in Bicuspids 97
Misplacement of Beginning Proximal Decays 100
Secondary Extensions Gingivally of Proximal Decays 101
Injuries by Interproximal Wear 104
Proximal Surface Decays in Incisors and Cuspids 107
Gingival Third Decays in Labial and Buccal Surfaces 109
Spreading of Decay Around the Teeth 113

Systemic Conditions 115
Physical Characters of the Teeth 118
General Summary of Results of Physical Examinations of the Teeth 120
The Hardness and Softness of the Teeth 122
Faults in the Structure of the Enamel 124
Physiological and Pathological Differences between Bone and Dentin 126
Studies by Dr. J. Leon Williams 128
Sialo-semeiology 129
The Saliva 132
Acidity of the Saliva, Viscidity of the Saliva, Glutinous Deposits from the Saliva, Signs of Susceptibility and Immunity to Dental Caries.
Microörganisms of the Mouth 138

Utility of Studies of Dental Caries 142
Vital Phenomena in Caries 144
Sensation in Dentin 146
Obtunding Sensitive Dentin 148
Thermal Sensitiveness 150

Management of Patients 153
Cleanliness 154
Cleaning which Patients should do for Themselves, The Tooth Brush, Mouth Washes, Tooth Powders, The Toothpick, Ligature, Tape and Rubber Bands.

PAGE

The Force Used in Mastication in Relation to the Strength and Health of the Peridental Membrane 161
The Force Used in Chewing Foods 161
Gnathodynamometer Records.
The Force Required in the Mastication of Food 165
Phagodynamometer Records.
Sensitiveness of the Peridental Membrane 168

Management of Light and Care of the Eyes 172

Examinations of the Mouth 178

Treatment of Dental Caries 188
Prophylactic Treatment of Caries by Artificial Cleaning 188
Treatment of Dental Caries by Filling 190
Curative Effect of Fillings 193
Selection of Filling Material 198

Management of Cavities by Classes 203
Classification 203
Cavities of the First Class 204
Cavities of the Second, Third and Fourth Classes 208
Limitation of Extension for Prevention 214
Thermal Sensitiveness 219
Lodgments of Food in the Interproximal Space 220
Prophylactic Value of Form in Proximal Fillings 222
Cavities of the Fifth Class 225
Caries in Cases of Recession of the Gums 230
Esthetic Considerations 232

Management of Children's Teeth 235
Relation of Growth and Shedding of the Deciduous Teeth to their Treatment 237
Premature Eruptions of Teeth 238
Absorption of the Roots of the Deciduous Teeth 239
Accidents During Absorption of Roots of the Deciduous Teeth 241
Treatment of Caries of the Deciduous Teeth 247
Treatment of Decays of the Deciduous Incisors and Cuspids ... 248
Treatment of Decays in the Deciduous Molars 253

PAGE

THE CHILDHOOD PERIOD OF THE PERMANENT TEETH 258
Growth of the Roots of the Permanent Teeth 258
Intercusping of the First Permanent Molars 262
Special Functions of the First Permanent Molars 263
Caries of Permanent Teeth During the Childhood Period 265
First Permanent Molars, Lingual Pits of Lateral Incisors, Proximal Cavities in the Incisor Teeth, Proximal Surface Decays of Lateral Incisors, Open Apical Ends of Root Canals, The Pulps of the Lateral Incisors.

GLOSSARY 279

INDEX 307

LIST OF ILLUSTRATIONS.

NUMBER

ATROPHY OF THE TEETH 1-47
Incisors and cuspids 1, 2, 3, 4, 5, 6, 7, 8, 18, 19, 26
Diagram showing positions of atrophy marks at various ages .. 9
Diagram showing lines of Ritzeus 10
Sections of incisors and cuspids showing zones of atrophy .. 11, 12, 13, 14, 15, 16, 20, 23, 24, 25, 27, 28, 29
Diagram showing zones of atrophy, *Zsigmundy* 17
Zone of injury from atrophy mid-length of root 21, 22
Cast showing atrophy of first permanent molar 30
Sections of first permanent molars showing zones of atrophy 31, 32, 33
Pits in the enamel 34, 35
General deformity of the enamel 36, 37, 38, 39, 40, 41, 42, 43
White enamel 44, 45
White spots in the enamel 46, 47

EROSION OF THE TEETH 48-62
Dish-shaped areas 48, 49, 61
Wedge-shaped areas 50, 51, 52
Flattened areas 53, 54, 55
Irregular areas 56
Figured areas 57, 58, 59, 60
Gold crown cut by erosion 61
Proximal surface erosion 62

CARIES OF THE TEETH 63-145

CARIES OF DENTIN 63-74
Dializer 63, 64
Salts dialized from saliva 65
Crystals of sugar 66
Tooth split to show area of decay 67
Occlusal surfaces of molars 68, 69, 70
Split teeth 71, 72
Dentinal tubules containing microörganisms 73, 74

NUMBER

CARIES OF ENAMEL....75-103
Occlusal surfaces, pit decays, split teeth....75, 76, 77
Proximal surface decays in incisors:
Proximal surface.... 78
Split teeth....79, 80, 81
Photomicrographs of sections....82, 83, 84, 85
Proximal surface decays in bicuspids and molars:
Proximal surfaces....86, 87, 88, 89, 90, 91
Cross cuts....92, 93, 94, 95
Photomicrographs of sections showing the injury to the enamel by caries....96, 97, 98
Relation of occlusion to the localization of caries:
Buccal view of bicuspids and molars.... 99
Occlusal view of bicuspids and molars.... 100
Normal occlusion, buccal view.... 101
Occlusal views of upper and lower teeth....102, 103

CARIES AS A WHOLE. ITS CLINICAL FEATURES....104-145
Occlusal surface decays in molars, split teeth....104, 105, 106
Proximal surface decays in molars, split teeth..107, 108, 109, 110, 111
Occlusal and proximal surface decays in bicuspids:
Split teeth....112, 113, 114, 117, 118
Photomicrographs of sections....115, 116
Misplacement of beginning decays, central incisor....119, 120
Secondary extensions gingivally of proximal decays, photomicrographs of sections....121, 122, 123
Injuries by interproximal wear....124, 125, 126, 127, 128
Proximal surface decays in incisors and cuspids:
Proximal surfaces....129, 130
Split teeth....131, 132, 133
Gingival third decays of buccal and labial surfaces..134, 135, 136, 137, 138, 139, 140, 141
Spreading of decay around the teeth....142, 143, 144, 145

SYSTEMIC CONDITIONS....146-158
Physical characters of the teeth, photomicrographs of sections of enamel....146, 147, 148, 149, 150
Physiological and pathological differences between bone and dentin, photomicrographs:
Cross section of bone.... 151
Lengthwise section of bone.... 152
Cross section of root of tooth showing absorption.... 153

NUMBER

Section of bone, showing absorption 154
Section of root of tooth, showing repair of absorption by cementum 155
Plaques on the teeth, photomicrographs of sections of teeth and plaques. *Williams* 156, 157, 158

VITAL PHENOMENA IN CARIES.....159-161
Diagram illustrating sensation without nerves in dentin..... 159
Split incisors, showing abrasion.....160, 161

FORCE OF MASTICATION.....162-166
Gnathodynamometer, for measuring strength of bite.....162, 163
Dynamometer, with micrometer attachment for determining stress a substance will bear without crushing, also the compression under stress 164, 165
Phagodynamometer, for measuring force required to chew food. 166

TREATMENT OF DENTAL CARIES BY FILLING, PHOTOMICROGRAPH OF SALTS DIALIZED FROM SALIVA..... 167

CARIES IN CASES OF RECESSION OF THE GUMS, TREATMENT BY SILVER NITRATE 168, 169, 170, 171

MANAGEMENT OF CHILDREN'S TEETH.....172-186
Diagram showing calcification of the deciduous teeth..... 172
Diagram showing absorption of the roots of the deciduous teeth 173
Apex of root of deciduous incisor forced through gum by permanent tooth 174, 175, 176
Treatment of caries of the deciduous teeth:
Labial view of deciduous incisors..... 177
Lingual view of deciduous incisors..... 178
Proximal decays of deciduous incisors treated by filing and silver nitrate 179, 180, 181, 182
Proximal decays of deciduous molars treated by cutting and silver nitrate.....183, 184, 185, 186

CHILDHOOD PERIOD OF THE PERMANENT TEETH.
Diagram showing calcification, period of eruption, and time of completion of roots of the permanent teeth..... 187

Pathology of the Hard Tissues of the Teeth.

INTRODUCTION.

THE injuries which occur to the hard tissues of the teeth during their development, and which occur to them by accident or disease after they have grown, are peculiar to the enamel and dentin. They have no apparent relation or natural kinship with similar developmental or acquired injuries or diseases of other tissues of the body, except some atrophic injuries to the hair and nails. This is made so by the histological structure of these tissues, in that they have no power of repair and recovery from injuries. The hair, nails, and the continuous growing teeth of a few animals, while having no means of repair of developmental or acquired injuries, dispose of the injured parts by the provision for the wearing away of the substance, and with this the defects. Growth continues to supply new material, and in this negative way may effect a repair.

The soft tissue appendages of the teeth, however, as the pulps, peridental membranes, alveolar processes, gums, etc., are developed under similar histological, physiological and pathological laws as other soft tissues and bones; and possess similar powers of repair.

The developmental injuries are confined to failure in development of parts of the enamel and dentin because of general systemic conditions which interfere with nutrition at a time when some particular part of the tooth is being formed, or is growing, and the injury is confined to that part. Other tissues have the power of repair of such injuries later. Since the enamel and dentin do not have this power of self-repair, such injuries in them are permanent. There is a similar failure of self-repair in these tissues when injured by accident or disease after they have been formed, or have grown and completed their development, such as accidental breakage of parts or injuries by erosion or by caries. As these tissues are not subject to inflammation,

nor to physiological or pathological changes in the same sense in which these occur in soft tissues and the bones, and as they are amenable to treatment only by artificial repair, it seems especially fit and desirable that these be considered in a group to themselves.

Those conditions that occur in the form of malformations or misbuildings, such as supernumerary teeth, odontomes, malformed teeth, etc., belong to a different class and require totally different treatment.

Atrophy of the teeth is met with so frequently in the practice of operative dentistry, and the injuries of the teeth are often so severe, that it has seemed to me that the facts gathered by recent investigations should be placed in permanent form in our literature. Until very recently little had been accurately known of the forms of these lesions, and many errors are being made in the treatment which may be avoided by a closer study of the conditions. While in many cases but little can be done to improve the appearance of atrophied incisors, a large proportion of the first molars which are now lost may be protected and remain useful in mastication, as well as to serve their full purpose in the development of the features.

On the subject of erosion, much greater interest is being manifested in recent years than formerly; the interest in its pathology has been increased by recent investigations and the continuance of these should be stimulated with the hope that its causation may become more definitely known and some satisfactory cure or preventive discovered.

The subject of dental caries and its treatment is and must remain the most important subject in conservative dentistry. No great improvement in its treatment can be had without improvement in the understanding of its causation, the conditions of the beginnings of caries of the enamel and the means to be employed in the prevention of its recurrence about the margins of fillings. To this end, extensive studies have been made of this particular phase of the subject with the view of placing that which is now known in systematized, usable form, for both students in dental schools and for practitioners. This feature of operative dentistry has been deemed of so much importance to the dental profession and to our people that, in writing of technical procedures in filling teeth, it has been held continuously before the mind of the student and practitioner by frequent explanations and repetitions. This has seemed necessary because of the general disregard of the study of dental caries in its rela-

tion to treatment by filling shown by most recent writers. It is intrinsically wrong to treat the subject of filling teeth simply from the mechanical standpoint; it is wrong in that it tends to produce in the minds of students the idea that filling teeth is a purely mechanical pursuit. This is far from the proper conception of the facts. In filling teeth, the closest use of our knowledge of the pathology of dental caries and of the local conditions of its occurrence, and of its recurrence after fillings have been made, should be put to full use in every case, in order that the greatest benefit may be derived from filling operations. To state this in the fullest detail has been a special object.

To this end, studies have been made of dental caries and the various forms it assumes in its beginnings in the enamel, spreading of colonies of microörganisms on the surface of the enamel, carrying with them the spreading of beginnings of caries into the surface of the enamel, and the manner of penetration of the enamel. These have been carefully illustrated by photographs and photomicrographs, beginning with the simplest forms, and, by careful arrangement, proceeding to the more complex through the different phases. There have been included, so far as seemed possible by this method, illustrations of the directions of this spreading and the local conditions which favor it and which hinder or prevent it. The areas of the surfaces of the teeth relatively most susceptible to the beginnings of caries, as differentiated from the immune or relatively immune areas, have also been illustrated. On account of the extreme importance in the practical operations of filling teeth of this particular phase of the subject, it has been illustrated, with two or three exceptions only, by photographs and photomicrographs reproduced by the half-tone method without any retouching or artificial modification in any way. To these a few diagrammatic illustrations have been added.

The fact has been kept prominent that immunity to dental caries, which may be complete, or which will approach completeness, even in persons, who, as children, were very susceptible to caries, will become established in early adult life in the larger proportion of cases in which effective protection has been given by filling operations, by continuance of active mastication of food, and reasonable care as to cleanliness. This matter, which was neglected because of previous misinterpretation of observed facts, is, with continued observation, assuming greater importance in dental practice. The systemic conditions producing the changes in the saliva on which susceptibility and immunity are

based, while making progress, has not yet assumed any such exactness of definition as to be of immediate use in practice.

In the technical procedures in filling teeth, the details of the adaptation of instruments to the work of cavity preparation have been brought into close systematization through notes of practical work at the chair representing actual operative experience. This has been expressed in forms of nomenclature that are simple, systematic and effective in teaching, in pointing out definitely the instruments for use and the manner of use of each. Every detail of cavity form is systematized and brought under a system of nomenclature comprised under a very few efficient rules, which render it simple and effective for teaching purposes and for general use by practitioners of dentistry. All of this has been systematized and improved through many years of actual work in teaching and has proven sufficiently flexible to cover all kinds and varieties of cases presented. The careful classification of cavities and of instrument forms adapted to each make it possible to teach cavity preparation in a way that it is easily learned; cavities may be more easily prepared, the time consumed is shortened, the operation is more definite in its results. Taken altogether, these mark an improvement in the effectiveness of operative dentistry.

Improvements that seem to have been but little thought of heretofore have been made subjects of careful study and systematization. Operative dentistry, particularly when closely pursued for years together, is extremely taxing upon the nervous system of the operator, and many men break themselves down purely through assuming positions at the chair that are unnecessarily fatiguing. This arises from assuming wrong positions in the beginning and the failure to obtain that relief which is clearly and easily possible by change and the rest that change brings, without ceasing or slowing the work at the chair. Systematization of these matters and bringing them under forms of nomenclature in which they may be taught and discussed understandingly should result in great good.

Dentistry has its own nomenclature which has become distinct from the nomenclature of comparative dental anatomy. The nomenclature of dental anatomy from the standpoint of dentistry and of operative dentistry belongs distinctively to dentistry, and should in no case be confounded with the nomenclature of comparative dental anatomy, nor the one used in the place of the other, nor should any effort be made to harmonize them. When the human teeth are under consideration from the

comparative anatomy standpoint, the nomenclature of comparative anatomy, which is suited to the description of the teeth of animals in general, should be used. In that nomenclature we do not speak of buccal and lingual surfaces of teeth but of inner and outer surfaces, the bicuspids in dental nomenclature become premolars in comparative dental anatomy. While there are points of coincidence in these nomenclatures, there are wide differences that could not be reconciled without positive injury to both.

ATROPHY OF THE TEETH.

ILLUSTRATIONS: FIGURES 1-47.

THE term "atrophy" includes two distinct ideas; the one is a failure of the development of a local part because of a failure of nutrition, the other is a wasting of a part because of a local failure in the nutritive processes. Atrophied teeth belong to the first class; they have never been fully formed. They come through the gums in the condition of deformity in which they are afterward seen, and do not, as some seem to suppose, waste away after having taken their places in the arch. The deformity is a result of incomplete formation. The term "hypoplasia" has of late been widely used in the German language in the same sense and is being adopted by some writers in English. The author has preferred to use the older term which has been used to designate this condition since it was first spoken of in the English language.

In the human teeth there is no process of repair and the deformity is permanent. Similar phenomena occur in the finger nails and the hair. During an illness that interferes seriously with nutrition, the portion of the finger nail then forming will be dwarfed, which will appear later as a groove across the nail. This, like the marking of the teeth, is not remedied by any reparative process. But the nail is continuously growing and the groove moves on over the length of the nail and disappears.

During a severe illness that interferes with nutrition, a section of hair is imperfectly formed, and when in the process of growth this section arrives at the surface of the skin and is subjected to bending, it breaks and the hair suddenly falls away. These are common phenomena following severe cases of typhoid fever. The hair follicles are not injured and the hair is replaced by the regular process of growth.

In the continuously growing teeth of the rodents such an injury would be finally removed and remedied in the same way as the grooving seen upon the finger nails, but this can not occur in the human teeth.

The deformity, though much varied in different cases, is, when closely analyzed, always similar in character. It always

Fig. 1.

Fig. 2.

Fig. 3.

Fig. 4.

Fig. 1. Atrophy of the cutting edge of the central incisors, forming a central notch or scar. This is usually called "Hutchinson's tooth." In connection with this form of atrophy, the occlusal surfaces of the first molars are also badly marked.

Fig. 2. Atrophy of the cutting edge of the central and lateral incisors. When this occurs, some portions of the occlusal surfaces of the first molars will also be injured.

Fig. 3. Atrophy marks on the incisors and cuspids. In this case there is a pitted groove around the crown of each tooth atrophied. The first molars have a similar groove on their axial surfaces.

Fig. 4. Atrophy marks on the incisors, showing the inverted fingernail scar on the lateral incisors.

Fig. 5.

Fig. 6.

Fig. 7.

Figs. 5, 6 and 7. Single teeth, the crowns of which have been badly dwarfed by atrophy. Each of these show two zones of injury. The dotted lines are intended to show the normal outlines of the crowns. Figures 5 and 6 are different views of the same tooth.

consists in a failure of the formation or an imperfect formation of some specific portion of the tooth and of several teeth together. The portion of the several teeth affected is always that portion of each that was in process of formation or growth at the same period in the person's existence. To understand this well one should study closely the calcification of the crowns of the teeth and the contemporaneous lines of calcification of the different teeth. This will be more fully explained in considering the histological changes occurring in atrophy. In the incisors the deformity is oftenest seen in the form of a groove, smooth or pitted, running across the labial surface from mesial to distal, and close inspection will generally show that it encircles the tooth completely, though it is most prominent upon the labial surfaces where the enamel is thickest. It is seen more often on the incisal half of the length of the crown. It may be near the cutting edge of the tooth or anywhere from that point toward the gingival line. It is also found occasionally in the roots of extracted teeth. There may be a single groove or pitted line, or there may be two or even three or more of these. The teeth affected are the incisors, cuspids and first molars of the permanent set, and very rarely the first bicuspids. If it is very close to the cutting edge on the central incisors it may not appear on the laterals, but the occlusal surfaces of the first molars will be atrophied. This is because these parts of these teeth are in process of formation at the same time. If the groove is a little further removed from the incisal edge of the centrals, the lateral incisors will also be similarly affected. If it is a little higher still, the four incisors, upper and lower, the cuspids and the first molars will be affected, but the bicuspids will be free from injury. It is exceedingly rare that the bicuspids or the second or third molars are affected by atrophy, for the reason that the enamel and dentin of these teeth generally have not begun to form until after the age at which these effects are most liable to occur. But few cases occur in which the first bicuspids are marked. The time of the occurrence of these injuries seems to be confined mostly to the first five years of a child's life, but some cases occur later.

In the engravings the endeavor has been to illustrate some of the more severe types of these deformities and to explain by illustration the histological defects. Figure 1 represents what is known as the typical Hutchinson tooth, from the claims of Mr. Hutchinson, a specialist in venereal diseases in London, England, who insisted that this deformity was the result of inherited syphilis. In such cases, it has formerly been supposed that the middle

lobe has failed of formation, resulting in this peculiar scar, but more recent investigation seems to show that the whole incisal edge has failed in most of these cases, and that the angles of the tooth have been drawn together over the injury, giving the outline of the tooth this rounded appearance. Certainly many of these teeth are much shorter than normal. Generally an ugly deformity of the occlusal surfaces of the first molars accompanies this type. In the molars little spiculæ of cusps are likely to be sticking up much too close together, while the rest of the occlusal surfaces are much too small, crumpled together and sunken into the crown, which, other than this, will be of full size and form. These teeth decay quickly in case there is a tendency to caries in the individual.

Of the incisors shown in this illustration, only the centrals are affected. The calcification of the cutting edges of these is occasionally just begun at birth, and if not begun then, is usually begun within one year. The injury, therefore, occurs soon after the birth of the child from some cause which interferes with nutrition. A very curious fact in pathology is rendered prominent in this form of atrophy. It is this: when the nutrition of any single part of the enamel organ is so impaired that its function is stopped or very seriously disturbed, that particular part does not recover, and no additional enamel is formed by that part. This will appear more prominently in the histological specimens. It is for this reason that these teeth have the peculiar rounded appearance of the cutting edge. The enamel organ of that part is arrested in its work at the very beginning of the calcification, and therefore the immediate incisal edge fails entirely. The rest of the organ goes on with its work after the recovery and the tooth is drawn in over the scar. In the incisors this form of atrophy is apt to be attacked by decay in this incisal pit very soon after the teeth have taken their places in the arch. They should be filled at once if decay is discovered. This particular form of atrophy is seen less frequently than others.

The occlusal surfaces of the first molars are occasionally badly atrophied when the incisors have escaped. Usually these have just begun their calcification at birth, and occasionally the calcification of the central incisors does not begin for one year after birth. In such cases a severe illness may injure the molars and not injure the incisors.

Much the more common forms are those illustrated in Figures 2 and 3, the illustrations showing rather bad cases. In Figure 2 the deformity is confined to the cutting edges, appar-

ently, of the central and lateral incisors above and below, and the four first molars. In the case here illustrated the whole of the incisal edge of each of the incisors above and below is dwarfed and shortened. This dwarfed portion ends abruptly toward the gingival. This is common in these cases. In many there is more or less rounding down of the well-formed part of the crown to the deformed part, but often it is so abrupt as to form a square shoulder along which there is apt to be a series of sharp, deep pits. In the case from which Figure 2 is taken there are no pits whatever, and the deformity consists purely in the dwarfing of the incisal edges. But the entire occlusal surfaces of the molars were in very bad condition because of dwarfing that presented many abrupt fissures in which decay began almost immediately after they had come through the gums. In such cases as this the appearance of the incisor teeth may be much improved by grinding away the dwarfed portion and shortening the cuspids a little to correspond with them. The teeth may appear a little short, but that is sometimes much less noticeable than the blemish.

In other cases, occurring in the same locality and affecting the same teeth, there may be but little dwarfing of the incisal edges of the incisors. The effect may be but a slight groove that may be smooth or more or less pitted, or in cases of a still milder type the distinct groove may be lacking and a row of fine pits in the enamel will be the only deformity. Generally, the effect is more marked in the occlusal surfaces of the first molars than in the incisors.

In the case illustrated in Figure 3 the injury has occurred later, when the child was between three and four years old. The incisal portion of the incisors had been formed, and, therefore, there is no dwarfing of this portion of these teeth. But there is a very marked groove encircling the crowns of the incisors and cuspids, marked with pits, with smoothly rounded bottoms. Both the groove and the pits in the groove are abrupt toward the gingival and thin away toward the incisal. This is a constant characteristic of these deformities, which will be readily understood by a study of the histological sections and the calcification lines of Ritzeus. The circular form of this deformity, as it passes from tooth to tooth across the front of the mouth, is well marked in Figure 3; indeed, it presents rather more of the circular form than usual, indicating especially that the cuspids were a little later than usual in their calcification, and for that reason the mark is nearer the incisal edge in proportion to the position on the incisors than it would otherwise have been.

It is not frequent that we see so severe a mark as here shown so high upon the labial surfaces of the incisors. It seems to be a general rule that the higher upon the teeth the less marked is the deformity. Pretty generally, in this position on the centrals, the mark is a shallow groove, more or less pitted, or a row of pits without a distinct groove. In all of these cases the lower teeth bear marks similar to those in the upper.

In Figure 4 a case is illustrated that is somewhat out of the usual form in several particulars. When the impression for the cast from which the illustration was made was taken, the cuspids had not come through the gums, but one of the first bicuspids had erupted, and, to my surprise, showed a deep mark encircling the point of the buccal cusp. Also the history of the case shows that the lateral incisors did not erupt for two years after the centrals had taken their places. In the centrals the incisal edges are fully formed, but there is a deep groove with rounded pits encircling the crowns at nearly mid-length, while nearly the whole incisal half of the laterals is badly deformed. This indicates that the beginning of the calcification of these teeth was late, as compared with that of the centrals. This particular form of deformity of the lateral incisors is not very frequent, but yet a considerable number have been seen, quite enough to indicate a tendency to this particular deformity. In the common vernacular this has been called the *inverted finger nail deformity.* If we imagine the finger nail taken up and turned with the convex side down and set back in the end of the finger, we would have something very like this deformity. The whole appearance of this case at the time of my observation of it, indicated unusual irregularity of the time of calcification and eruption of the different teeth. The first molars, both above and below, had already been destroyed by decay, beginning in the deformity of the occlusal surfaces.

Figures 5 and 6 show a lower incisor with a double deformity. Figure 5 is a view of the labial surface, and Figure 6 of the mesial surface. The dotted lines show the normal tooth form. The two, taken together, show the extent of the dwarfing of the crown of the tooth. In this case the surface of the enamel was smooth and without pits.

Figure 7 shows an upper central very badly deformed. This is also a double deformity and was further injured by decay starting in pits in the abrupt portion of the groove nearest the incisal. The sharp, deep pits shown along the line of the second groove have not been caused by decay, but were there when the tooth came through the gums. These teeth are from different



Fig. 8.

Fig. 8. Atrophy of incisors and cuspids showing no discoloration. Photographed direct from mouth of girl eighteen years of age.

persons, and in both cases were extracted in order to remedy the defect with artificial teeth. This seems to have been done under the mistaken notion that the roots of the teeth would not be good for artificial crowns. Extended observation shows that the roots of such teeth are as apt to be well developed and as good for crowning as those of any other teeth. When the crowns are so badly deformed as to render such proceedings necessary, artificial crowns should be resorted to, rather than the removal of the teeth. There is a hope that in the future such teeth may be restored to a comely appearance by means of porcelain. In case the crowning involves the removal of the pulp, this should be delayed as long as possible in order that the roots may be fully formed and the apical foramen reduced to a small size. One should wait until the patient is sixteen to eighteen years old, and twenty would be still better. In many cases of considerable actual deformity of the teeth from atrophy the color remains very perfect, and in this case, if the incisal edges of the incisors are fairly complete, the deformity is not prominently noticeable, as is shown in Figure 8, from a photograph taken directly from the mouth.

Etiology.

Atrophy of the teeth is always caused by some illness that has interfered with nutrition at the time the particular parts of the teeth affected were in process of calcification. My attention was strongly called to this through a controversy between Mr. Hutchinson of London, and Dr. Magitot, of Paris, who took opposite views some thirty or forty years ago. From Mr. Hutchinson's observations he was led to believe at first that all of these cases of atrophy were caused by inherited syphilis, while Dr. Magitot had come to the conclusion that they were due to eclampsia. This controversy led to a closer study of this whole subject, and finally Mr. Hutchinson yielded the point so far as to say that inherited syphilis was a frequent cause, and for many years held that the type shown in Figure 1 was always caused by inherited syphilis. That form, therefore, has been called the Hutchinson tooth. As showing how errors are liable to be perpetuated, most of the books on general medicine, surgery and venereal diseases, which mention these deformities at all, ascribe them to inherited syphilis, following the first writings of Mr. Hutchinson without further investigation. They are continually accusing innocent persons of crime.

The author has followed this subject pretty carefully ever since Mr. Hutchinson wrote, adding observation after observa-

tion, and has arrived at the conclusion that there is no special form of disease that is especially blamable for this affliction, but that any form of disease that seriously interferes with nutrition is liable to bring about this result, i. e., that it is not the particular form of disease, *but that it is the condition of malnutrition that is the cause,* no matter what the disease which has induced that condition. I have seen cases of typical Hutchinson teeth which were certainly in no way connected with a syphilitic taint of any kind.

Some of these observations may be of interest. Mr. and Mrs. B., known by the author intimately from childhood, had a child which seemed healthy at birth, but soon afterward became anemic and did very badly for two years. Growth was a failure during that time, and it was with great difficulty that the child was kept alive. In its third year, however, the child recovered and became strong and healthy and developed well. When the permanent teeth came through the gums, almost the incisal third of the centrals and laterals was badly dwarfed, the points of the cuspids had failed and the occlusal surfaces of all of the first molars were badly atrophied.

In another case a kinswoman was visiting at my house with a little girl two and a half years old. The child had not been very well for some time, though she showed no particular form of illness. She would play much of the time, but seemed to get very tired. One day I was suddenly called to her and found her apparently dead, a condition that had been preceded by a violent clonic spasm. I instituted artificial respiration at once, and after a few moments there was a sigh and directly another, and within a few minutes the respiration and circulation were reëstablished. The child dropped to sleep almost immediately, while yet in my arms, and seeing that the breathing was sufficiently full and regular, I laid her on a couch and left her mother to watch her. She slept three hours, and when she awoke she was ready to play again. She remained rather dull for a month, when the condition seemed to pass away. There was but the one spasm. But when the permanent teeth came through they were deeply marked, corresponding with the time of this occurrence.

I attended a child two and a half years old through a severe case of typhoid fever. When the permanent teeth came through they were marked with a deep groove, irregularly pitted, similar to Figure 3, but not so high up on the crowns.

An English woman brought her child to me on account of a very ugly marking of the incisors which had just come through

the gums. In reply to my inquiries she could not remember that the child had had an illness of any kind. The boy had always been healthy and had escaped all of the infantile diseases. Being convinced that something had occurred that would have been noted, I asked her if the child had had any kind of an injury. This quickly brought out the statement that the child had had a severe burn, a scald, on the side and back, that had healed slowly after much suppuration. Indeed, the child had been very ill with septicemia for a month or six weeks. The time corresponded with the marks upon the teeth.

Cases like these, but every one different in detail, could be multiplied almost indefinitely. Scarlet fever, measles and whooping-cough come in for a large share in producing these marks. My observations for some time led me to believe that scarlet fever and measles are most often to blame for the rows of fine pits, but of late I have found so many of these following other forms of disease that I am led to doubt the distinguishing features of these marks. Certainly, hereditary syphilis comes in for its full share of these cases.

On the other hand we can not say, at least I can not, that marked teeth will result from this or that illness. If the hair falls out or the finger nails show a groove after an illness we are apt to find the teeth marked also. Very many of the cases that I have noted and watched for the coming of the permanent teeth have presented teeth without a blemish. Indeed, among all of the cases that I have noted and watched, the marked teeth have been the exception rather than the rule. Still, it remains true that when I have been able to obtain a satisfactory history, the marked teeth have coincided in time with some form of disease that might well have interfered seriously with the nutritive processes. The history is not always easy to get, even among intelligent people. I once remarked to a lady in my chair that she had been very sick with scarlet fever when she was about two years old. She was very sure she had not, for she had never been told of such an occurrence. When I explained that accurate knowledge of the facts was of considerable scientific value she said she would question her mother regarding it. The next day I received a note saying her mother's story agreed with my supposition, both as to the particular disease and the date of the illness. I have seen many of these cases, however, in which I could find no history of the illness causing them.

As an assistance in searching for the cause that has led to atrophy in cases coming before us, I introduce a diagrammatic

chart, or index, indicating by lines across the incisors, cuspids and first molars, the positions the grooves across the teeth assume because of disease occurring at different ages of the child. Figure 9. These lines have been varied a little from the true contemporaneous calcification lines to suit better the apparent positions upon teeth that are shortened by severe atrophy. This chart will point out the age at which any injury occurred as well, perhaps, as it can be done in a chart of this character, which, of course, is founded upon averages. Pretty wide variations will occur in the time of the calcification of the teeth of individuals, and also between the several teeth of the same individual. There is certainly as much variation as eighteen months in the time of the beginning of the calcification of the central incisors, and a greater range possibly with all of the other teeth, except the first molars. These latter are perhaps the most constant. But these certainly vary from the twenty-fifth week of uterine life to something near six months after birth.

The chart is intended only to give a general average as to the time of the illness that has caused these injuries.

Histological Characters in Atrophy of the Teeth.

In presenting the histological characteristics in atrophy of the teeth, it may be stated that all of the cases thus far examined by myself, no matter how different their outward appearance, present one plan of departure from the normal arrangement of tissues. The differences are due only to position, the number of zones of injury and in the details of severity. This plan is inseparably linked with the plan of development of the dental tissues. There are, however, other forms of deformity of the enamel in a degree simulating atrophy, which are entirely different in histological characters. Some of these will be noted later.

Except in the pits that often accompany it, the zones of injury in atrophy rigidly follow the lines of Ritzeus. In the diagram, Figure 10, the lines of Ritzeus are made especially prominent to recall distinctly their direction on different parts of the enamel cap of the crown of the tooth. In microscopic observation these are usually clearly seen in some parts of the enamel cap, particularly in central labio-lingual sections. They vary, however, indefinitely in prominence in different sections, and in different parts of the same section. Generally, they do not show clearly in all parts of a section, and those who have not studied them carefully should refresh their memory as to the course of

these lines in different positions on the crown of the tooth. These lines are the index to the growth of the enamel cap. They are the real lines of accretion and show distinctly the order in which the enamel cap is built up, layer after layer, in its growth. This growth begins at the dento-enamel junction, in positions which represent the cutting edge (or points of the cusps in molars and bicuspids) and grows from within outward, while the dentin begins its growth at the same point and progresses from without inward. The growth of dentin is always a little in advance of the enamel as it grows from the incisal edge of the front teeth (or the points of the cusps of other teeth) toward the gingival line.

Atrophy, in all cases, consists of an arrest, or partial arrest, of growth of both enamel and dentin in the particular zone or part of enamel and dentin, being developed at the particular time. In the milder cases growth is imperfect, leaving certain definite markings outlining the particular parts of the tissue then being formed. In all the severe cases the growth of both enamel and dentin is arrested. There seems to be no recovery of the part of the enamel organ that was at the time in active function. No more enamel whatever is formed over the area affected after recovery from the condition of malnutrition, except as the new formation is telescoped over the area of the old. The dentin pulp, however, rebegins its growth function apparently immediately the condition of malnutrition has passed. But the parts of the tooth which should have been formed during that period are not formed at all. A certain part of the tissue which should have constituted the perfect tooth has been left out, and the distortion of form which we so often see results from patching the second growth onto the first and the total failure of particular portions of the enamel. This total failure of the enamel is not in the direction of the thickness, but is always on the lines of Ritzeus. Therefore, as we shall see later, there is not a failure of the total thickness of the enamel at any point, except in a few cases in which the injury occurs at a time when calcification was just about to begin, as sometimes occurs in the so-called Hutchinson tooth, and may, rarely, occur in others. For instance, in the diagram, Figure 10, there are four layers of enamel represented over the incisal edge. If total arrest of growth should occur at the time the first two layers are completed, the third and fourth layers will never be formed. The enamel will remain over the incisal edge with only these two layers. Then perhaps the fifth and sixth layers shown, more or

less, will also fail, and the seventh and eighth layers will overlap the first and second somewhere near half their length, because the formed part of the incisal edge sinks into the dentin pulp. The dentin pulp has also stopped its growth at the same time and the part that failed of growth is left out of the final tooth form. These are the fundamental propositions presented in the explanation of the histological groupings of tissue and the shortening of the tooth crown found in these cases.

In Figures 11 and 13 I present photomicrographs* made with a very low power, of labio-lingual sections from two atrophied teeth, so that the entire form of the crown of each may be seen. Figure 12 is another photomicrograph from the same section from which Figure 11 was made, but with greater amplification. The one presents two zones of injury, while the other has but one. In each of these the malnutrition was so severe as to arrest the growth of both enamel and dentin. In each an injury has occurred, affecting the incisal edge of the tooth. By comparing these with the diagram it is easily seen that when a certain thickness of growth of enamel had formed over this part, development was arrested and no more enamel was formed. In each case the enamel is thickest at the incisal edge and thins away to the groove which encircles the tooth crown, which is here presented in section. A band of very dark growth is seen under the new after-growth of enamel following the lines of Ritzeus on down to the dento-enamel junction. A comparison now with the diagram shows that the growth has been arrested on the lines of accretion or lines of Ritzeus, as you may please to call these lines, Figure 10, in both cases. Also, it is seen that the second injury in Figure 11 is similar in plan to the first, differing in detail only because of the changed direction of the lines of accretion. In Figures 11 and 12 the incisal edge is broken, as usually occurs in these thin edges, but Figure 13 is from a tooth extracted soon after it came through the gums and all of the tissue formed is present.

Figure 14 is an illustration with a much higher power of the labial side of the first zone of injury shown in Figures 11 and 12. Figure 15 is from the second zone of injury on the labial side, and Figure 16 is from the second zone of injury on the lingual side. In these, the tissues and the lines of Ritzeus are fairly well

* NOTE.— In this work any photographic illustration made by reflected light will be called a photograph, even when moderately magnified. But when transmitted light through a thin section has been used, it will be called a photomicrograph. It has not been thought necessary to mention these terms in every instance.

Fig. 11.

Fig. 11. Section of an incisor showing two zones of atrophy, or two grooves in section. Magnified eight diameters.

Fig. 12.

Fig. 12. Same as No. 11, but with greater amplification.



Fig. 13.

Fig. 13. Section of a cuspid showing a single very severe zone of atrophy, or a single groove in section. Magnified eight diameters. This case shows well the sinking of the incisal edge into the body of the crown of the tooth.



Incisal end.

FIG. 14.



Incisal end.

FIG. 15.

FIG. 14. Atrophy. A photomicrograph of a portion including the first zone of injury on the labial, i. e., that nearest the incisal edge, from the same section shown in Figures 11, 12, with a higher magnification. In this the lines of Ritzeus may be seen in the enamel, also the dark line of junction between the enamel of first formation and enamel of second formation, reaching from the dento-enamel junction, with the enamel of second formation overlapping that of the first. The line of interglobular spaces in the dentin, running almost parallel with the line of the dento-enamel junction, is well shown.

FIG. 15. Atrophy. A portion including the second zone of injury seen in Figures 11, 12, with a higher magnification. In this position the lines of Ritzeus diverge more sharply from the direction of the line of the dento-enamel junction, and the overlapping of the third growth of enamel onto the second is shorter. The discoloration is greater. The line of interglobular spaces is broader, and in this position diverges more sharply from the line of the dento-enamel junction. Otherwise it is similar in plan with the first zone of injury shown in Figure 14.



Incisal end.

FIG. 16.

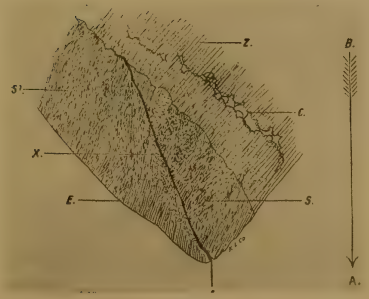

FIG. 17.

FIG. 16. Atrophy. The second zone of injury on the lingual side from the section shown in Figure 11. It will be seen that while differing slightly in detail, all of its parts are similar to the portions shown in Figures 14, 15.

FIG. 17. Lengthwise section through portion of crown of an atrophied tooth. A. Direction toward the crown. B. Direction toward the root. Z. Dentin. C. Interglobular spaces. E. Enamel. S. Wedge-shaped piece separated by line of injury. X. Line of injury. S1. Full thickness of enamel. *Zsigmundy.*

Fig. 18.

Fig. 19.



Incisal end.

Fig. 20.

Fig. 18. Labial surface of a central incisor, photographed to show the appearance of the groove. The dark color in parts of the groove makes it appear deeper than it really is. A part of a section cut from this tooth is shown in Figure 20.

Fig. 19. Photograph of the lingual surface of the same tooth shown in Figure 18.

Fig. 20. A photomicrograph of a portion of a section from labial portions of the central incisor, Figures 18, 19, showing a milder sort of injury from atrophy, in which the growth of the enamel was interrupted but not permanently stopped. The line of interglobular spaces literally divides the dentin of first formation from that of the second. The section was broken and the parts placed in position. A scrap of enamel was lost in preparation, as represented by the dotted line.

shown, and by studying the photomicrographs carefully, the relations of the tissues formed before and after the injury may be made out. It will be noted in Figure 14 that the one particularly dark band, which represents the surface of the enamel formed over the incisal edge, is continued under the enamel of second formation to the dento-enamel junction. Beginning a little farther from the incisal, a line of interglobular spaces appears in the dentin, and running almost parallel with the dento-enamel junction, continues on toward the incisal edge. Faint traces of these appear even in the small picture, Figure 12. With sufficient amplification, this line of interglobular spaces is found to continue to the incisal edge and join with the similar line from the opposite or lingual side; that is, in the whole tooth it is a sheet or zone of interglobular spaces passing throughout the full extent of the dentin, of which this is a section. This line represents the injury in the dentin. It also represents more. It marks the boundaries of the old and the new formation of dentin and is the line on which these have been patched together. On the other hand, the one dark line in the enamel marks the line on which the new formation of enamel is patched onto the old. After a very careful study of sections from many of these teeth, it becomes clear that the part of the tooth which should have formed during the stoppage of growth was not formed at all. The enamel organ was destroyed through its whole thickness to the point where the dark line limiting the first enamel formation reaches the dento-enamel junction, and when the second formation began it was telescoped over the old and laid down upon it, as shown in the illustration. The crown of the tooth was shortened that much, certainly, and may have been shortened very much more. When we study carefully Figure 13, with its single line of injury, and note how the little part of the incisal edge formed before the injury is literally sunken into that portion formed later, we must conclude that the shortening is much greater than that shown by the apparent telescoping of the parts. In the dentin the same thing occurs, only that it is expressed differently because of the different character of the tissue. The line of interglobular spaces shows where the second growth was telescoped *into* the first.

A study of Figures 15 and 16 shows the same plan in the arrangement of the tissue in the second zone of injury, including the overlapping of the new enamel onto the old and the accompanying line of interglobular spaces in the dentin. The shorter overlapping of the enamel at the point of injury is due to the

changed direction of the lines of growth. The actual shortening of the tooth may have been much greater. When we study the short and stumpy forms of many of the crowns of these atrophied teeth, we must conclude that the shortening is often very much greater than this overlapping. It is this shortening and telescoping together of the different parts that is responsible for the greater part of the distortion of form so often observed in these teeth. It appears certain that the tendency is to form each of the parts on the lines that each would have had at the specified time of growth if there had been no interruption of the growth.

We may gain another view of this by studying the lines of the labial dento-enamel junction. In the study of sections of many human incisor and cuspid teeth, this line is found to form a continuous curve from the incisal edge to the gingival line, as seen in the diagram, Figure 10. The amount of curve may vary indefinitely, but it is always a continuous curve in every normal tooth. In studying sections of atrophied teeth, this curve is found broken by a recurve at the zone of injury in every case, even in the lighter forms in which growth seems not to have been completely arrested. This disturbance of the direction of this line seems to be due to the effort to form the second part on the lines that would have been laid down at that time if the growth had been going on regularly, and the larger and smaller are patched together. In the dentin the growth has been in abeyance and the growth begins on the lines on which it was left off. But immediately the tendency is to enlarge to the greater outline of the tooth as it would have been at the time had the growth not been interrupted. This causes a recurve in the line of the dento-enamel junction. In the enamel, the telescoping seems to be actual. That part of the enamel organ that had not arrived at the period of enamel building is uninjured and is pushed forward over the previously formed enamel and lays down its layers of the second growth of enamel thus far over the old. No other explanation of the phenomena is presented after the study of numerous cases.

The discoloration that occurs in these teeth would seem to be an essential characteristic, if it were judged entirely by the teeth obtained for making sections. This material is very difficult to find. Only extracted teeth can be used, of course, and few of them are extracted until so badly decayed that they are useless, except those that are so badly discolored that patients and their friends urge their removal on that account. Examinations



Fig. 21. Fig. 22.

Figs. 21, 22. Root of tooth parted on lines of growth. Photographed from the specimen extracted by the author. Photographs of a bicuspid tooth which had a zone of injury from atrophy mid-length of the root, and which was pulled apart in telescope form along the line of injury, i. e., the line of interglobular spaces. In Figure 21 the parts are photographed in normal position. In Figure 22 the two parts are separated, showing how they are telescoped together.

in the mouth reveal many cases of very considerable deformity without notable discoloration, as the photograph, Figure 8, taken from the mouth, attests. Many of the zones of injury show no discoloration.

Many writers have given short descriptions of atrophied teeth, scattering back for a hundred years. Most of these have dealt with the outward appearance only. Very few have published any studies of the histological characters, and most of these have been very brief and imperfect. Among the better should be mentioned Wedl, 1870; Baume, 1882; Walkoff, 1885. But by far the most important of the studies that have appeared is that by Dr. Otto Zsigmondy, of Vienna, Austria, in a paper presented at the World's Columbian Dental Congress in Chicago in 1893. Unfortunately for Americans, no translation into English has been published. I personally examined many of Dr. Zsigmondy's sections and learned further of his conclusions in conversation. The one thing that impressed me then, and impresses me now, as I reread his paper, is his conviction that the tissue distortion has been produced by a condition that has been of very short duration, because the apparent zones of injury in the dentin were often — nearly always, indeed — so very narrow when considered in their relation to the developmental lines. He could not, therefore, account for the marked deformity of these teeth. At the time he wrote he did not have the advantage of photomicrographic reproductions, and his illustrations were very meager and insufficient. One of the best of them is reproduced in Figure 17.

Figure 20 is a photomicrograph of a section of the labial portion of a zone of injury of the milder sort apparently, occurring in a central incisor. In this there was considerable discoloration of the enamel occurring irregularly along the line of injury in the labial surface, as shown in the photograph of the tooth, Figures 18 and 19. The discoloration in the line of the groove has the effect of a shadow in the photograph and makes the groove appear deeper in the discolored portions, which is not the fact. The particular section from which Figure 20 was made was chosen from a part showing the least discoloration. In this case the only distortion of the crown apparent in a superficial view of the tooth is the groove encircling the tooth and the discoloration. Also, the section shows that there was not a complete arrest of growth of the enamel. With a good light the enamel rods may be traced with the microscope through the darkest lines of the section, and they are seen to be well formed.

There is no appearance of the telescoping process. The groove in the enamel appears much less pronounced in the section when highly magnified as shown, than it does in the photographs of the tooth. In the dentin, however, the injury is very severe, as shown by the clean-cut continuous line of interglobular spaces, which literally cut the dentin first formed from that formed later, and in the examination of the labial line of the dento-enamel junction in the full section, it is found to be distorted by a recurve, showing the interference with growth to have been profound and that some real shortening of the tooth must have occurred.

As a further illustration of the possibilities in this class of injuries, I present two photographs, Figures 21 and 22, of a bicuspid tooth showing the separation of the telescoped parts in an injury of this kind occurring mid-length of the root. I extracted this tooth myself. The patient, a stranger, applied for relief from caries of bone of the upper jaw, and this tooth was situated on the border of the carious area in such position that it seemed to be best to remove it, though the tooth and its individual alveolar process were otherwise in good condition. At the moment of removing the tooth, it was noticed that the apical portion of the root did not come away, but was pulled from its place and remained loose in the alveolus. Laying the tooth on the bracket with the forceps, this apical portion was picked out with the foil pliers and laid with the tooth for after examination, because it seemed to be a very curious break. The operation was completed and the patient dismissed with an appointment to return later for further treatment. On examination, this tooth and root were found to have pulled apart like a telescope tube, and the telescoping was on the lines of growth of the dentin. Figure 21 shows the tooth and root placed together in the normal form, in which *a* marks the line of break. In Figure 22 the two parts are separated, showing how the apical portion telescopes into the body of the root. I suppose there was some severe illness of short duration at the time this part of the root was developing, which prevented the deposit of calcium salts, and a sharp, distinct and continuous line of interglobular spaces occurred. At the time, the root was developed only as far as shown in the lower section of Figure 22, and had the broad conical opening shown at *b*. The internal diameter at the point to which the end of the apical portion reaches was of the size shown by the end of that piece. The result was that the solid dentin formed at that time represented only the lower

Fig. 23.

Fig. 23. A portion of a section through a central incisor, showing atrophy of the severer sort. The plan of the injury, and the telescoping together of the parts, is seen to be the same as in Figures 14, 15, but the discoloration is much less. The thin incisal edge had been ground away before extraction in an effort to improve the appearance.



Fig. 24.

Fig. 24. Portion of a section from an incisor showing a zone of atrophy and the plan upon which the parts are telescoped together. The thin incisal edge had been ground away before extraction.



Incisal end.

FIG. 25.

FIG. 25. A photomicrograph from labial portion of a section from an incisor tooth which showed but faint traces of an atrophy mark on the surface of the enamel. The markings in both the enamel and dentin are such as are found in the milder forms of atrophy.

Fig. 26.

Fig. 27.

Fig. 26. Photograph of a bicuspid, showing imperfectly a slight groove from atrophy near the junction of the middle and gingival thirds of the crown. See Figures 27, 28.

Fig. 27. The bicuspid shown in Figure 26 split mesio-distally and the cut surface photographed as an opaque object. Note a broad zone of shadow in the dentin, extending in a semi-circular form from the groove on the mesial to the groove on the distal side. See also Figure 29.



Fig. 28.

Fig. 28. A photomicrograph from a portion of a section of the bicuspid shown in Figures 26, 27, showing zone of shadow in the dentin as a result of interference with nutrition. Markings of this character are found in the mildest forms of interference with nutrition that show atrophy marks.



Fig. 29.

Fig. 29. A photomicrograph from section of atrophied tooth cut diagonally to the zone of injury and serving to exaggerate the width of the zone of interglobular spaces in the dentin. This gives a stronger representation of the real injury to the dentin.

square end of the upper piece. This was broken in the effort to extract and the root pulled apart on the line of the area of interglobular spaces, the line representing the lines of the process of growth.

The patient failed to keep his appointment for further treatment and was not seen again. The opportunity to inquire into the nature of the nutritional disturbance that had caused this rare form of injury was lost. The specimen, however, tells its own story clearly. This case shows that the root of a tooth may also be injured by atrophy, though such an extreme occurrence as this must be rare.

I have noted a considerable number of cases in which a zone of injury occurred in the dentin beginning below the gingival line, as in the case shown in Figures 21, 22, though they are far more rare than those occurring in the crown of the tooth. In Figure 11 there is such a zone of injury which may be seen even in that slight amplification, in the disturbance of the outlines of the enamel and some faint shadows representing the lines of interglobular spaces. With medium powers of the microscope, these latter are prominent objects.

Figure 23 represents another case of atrophy of the graver sort, occurring in a central incisor, in which but little discoloration is apparent. The wide overlapping of the new onto the older enamel, the complete breakage of the enamel rods along the line of junction of the two, the change in the course of the enamel rods in the two formations of enamel and the profound disturbance of and recurving of the labial dento-enamel junction, all point to a long suspension of nutrition and account for the grave distortion of the form of the tooth. This is much like that shown in Figure 13. The line of interglobular spaces is sharp and severe, but very narrow, and the dentin is normal immediately on either side. The incisal edge had been ground away in the endeavor to improve the appearance before the tooth, with the other incisors, was extracted. About one-third of the normal length of the crown had been missing.

Figure 24 represents another similar case, but with rather more discoloration. The incisal edge of this had also been ground away in the effort to improve the appearance before resorting to extraction. In this the main features are again repeated; it shows the same line of demarkation between the old and new enamel, the same distortion by recurve of the labial dento-enamel junction and the same sharp line of interglobular spaces. In this particular case the character of the

line of interglobular spaces is almost obscured by being filled with balsam in mounting the section.

Figure 25 represents a case that was apparently of the mildest description. The only outward appearance was a band of slightly dark color across the labial surface of the tooth. One not searching for cases of this character might have passed the tooth as normal. The tissue reveals a pronounced disturbance in the same particulars as in the more severe cases, only not so grave. The enamel rods pass through all of the darkened lines without a break, and there are almost no interglobular spaces in the dentin. A sharp curve and recurve in the dentinal tubules give the appearance of a very distinct line of injury, however. The line of the labial dento-enamel junction is also considerably disturbed.

The next case is very curious in several respects. It is a bicuspid tooth that showed a very slight groove in the enamel not far from the gingival line. It was covered by the overlapping gum margin, except on the buccal surface. The whole tooth was, perhaps, as white as any normal tooth and was without any discoloration along the line of the groove, except that caused by a deposit of dark, closely adherent serumal calculus at several points. A photograph of this groove was but a partial success, as is shown in Figure 26. The tooth was then divided mesio-distally, preparatory to grinding sections. In examining the halves with a pocket lens, a curious zone of injury in the dentin was discovered, which was photographed at once as an opaque object, which is represented in Figure 27. Two sections, two thousandths of an inch thick, were prepared and mounted without removing them from the cover glass on which they were ground. The sections were beautiful. No one would suspect that there was any zone of injury in either dentin or enamel. The disturbance of the line of the dento-enamel junction and in the one section a clinging bit of serumal calculus were the only abnormalities discoverable by microscopic examination. The only way I could explain this was that the something that had been seen and photographed had become obscured by the balsam. The balsam was dissolved out and the section dried. A zone of fine interglobular spaces was then found with another singular appearance in the form of a broad line of demarkation, that could not be explained. The section was remounted in a very stiff balsam without using anything to clear the dentin, with the expectation of making a photomicrograph the same evening. Something prevented, and by the next evening, the day having

been unusually warm, the interglobular spaces were again filled with balsam. The shadow, however, remained, and is presented in Figure 28. It has since been found that the condition presented is common to a considerable number of the slighter atrophic injuries.

Figure 29 is a photomicrograph of a labio-lingual section cut from near the mesial side of an atrophied tooth so that the line of interglobular spaces is cut through diagonally. This gives an exaggerated view of the zone of injury to the dentin, but will serve to impress the fact that these injuries are very severe.

This presents this subject from its gravest to its slightest degree, in sufficient variety of cases to render the conditions intelligible.

Atrophy of the First Permanent Molars.

Atrophy of the first permanent molars should receive some special consideration because of its greater frequence and because it so generally leads to early and rapid caries beginning in the atrophied portion. The plan of injury does not differ from that in atrophy of the anterior teeth, but the details of the injury are different because of the wide difference in the form of the tooth. The greater frequence of the occurrence of atrophy of these teeth is due to the earlier beginning of calcification. In dissections of the jaws of the fetus at term, I have usually found the calcification of this tooth just begun on the points of the cusps. Sometimes there are only small spiculæ, in other cases a more considerable part of the cusps is calcified, but I have never seen the calcification so advanced at birth that the cusps were united by calcified tissue, and evidently they are not so united until much later. On the other hand, it was only occasionally that the least bit of calcification had occurred on the central incisors. More often calcification does not begin on these until about the end of the first year. Therefore, an illness that brings about serious malnutrition during the first year of the child's life is liable to wreck the occlusal surfaces of the first molars, while all of the other teeth escape injury.

Atrophy of these teeth occurring so early is very characteristic if seen soon after the eruption of the teeth and before further injury has occurred by breaking away the sharp spiculæ representing the malformed cusps or by caries. But it is exceedingly difficult to obtain specimens from which to make illustrations. If the atrophy has occurred very early, or before the enamel plates forming the lobes of the teeth have joined together,

the spiculæ of cusps will stand much closer together than the cusps of the normal tooth. The whole of the occlusal surface of the tooth is dwarfed, often discolored and sunken into the tooth crown. The pulp chamber will be nearer to the occlusal surface than in the normally developed tooth in proportion to the sinking of this part into the body of the crown. Figure 30. All around this the enamel of second formation wells out in the form of a broad collar to the normal size of the tooth crown at or about the base of what would have been the normally developed cusps. The whole of the injured area is apt to be rough and pitted, and the pits and grooves are very apt to be wide open. This condition gives unusual opportunity for the beginning of caries and the early exposure of the pulp. It is for this reason particularly that they are so often destroyed very early. In cases occurring a little later, but before the completion of the occlusal surface, the conditions inviting the beginning of caries are equally bad. The cusps will stand further apart, are stronger, but the central part of the occlusal surface and the outer slopes of the cusps are in very bad shape. At a still later date, after the completion of the occlusal surface, the injury appears as a groove around the crown of the tooth and is generally of less consequence.

In all of these cases the zone of injury in the dentin is one of the very grave features, for the reason that caries reaching this zone of interglobular spaces spreads through it quickly. It has been exceedingly difficult to get material for the illustration of this for the reason that very generally the occlusal surfaces of these teeth are destroyed by caries before their removal, rendering them useless for this purpose. Figures 31, 32 and 33, with their descriptions, serve, however, to illustrate the condition of the tissue injuries fairly well, though neither of them are of the severer forms of atrophy. Figure 31 particularly shows the line of interglobular spaces in the dentin extending across the occlusal surface and dipping down gingivally along the axial portions of the dento-enamel junction. This figure also shows well the shortening of the crown between the pulp of the tooth and the occlusal surface. From the position of the injuries in atrophy, it will be realized, from a careful study of the lines of the injury to the dentin, that the total shortening of the crown of the tooth is between the pulp and the occlusal surface in the molars. It is also between the pulp and the incisal edge, where it occurs in the incisors and cuspids. This is the reason that pulps are so frequently exposed in the preparation of cavities



FIG. 30.

FIG. 30. Photograph of cast showing atrophy of a first molar. Note that the occlusal portion of the tooth is much reduced in size. This is best appreciated by comparison with the second molar. Normally the occlusal surface of the first molar is the larger of the two.

FIG. 31.

FIG. 31. A photomicrograph from a perpendicular bucco-lingual section through the crown of an atrophied lower first molar. The injury to the enamel is slight as compared with the injury to the dentin. Notwithstanding this, the shortening of the crown has been very great, as will be seen by the short distance from the occlusal surface of the tooth to the pulp. This is a common characteristic of atrophied teeth. The line of interglobular spaces in the dentin follows close to the dento-enamel junction under the whole of the occlusal surface. It then dips down along the axial surfaces, as shown at both the lingual and buccal margins of this section. Through most of its course this appears as a sharp, but jagged, dark line of interglobular spaces, which are better shown with the greater amplification in Figure 32. All of this dark part of the line is made up of interglobular spaces that open the one into the other. These are filled with air when the section is dried. At several points the balsam used in mounting the section has run through this, partially obscuring it.

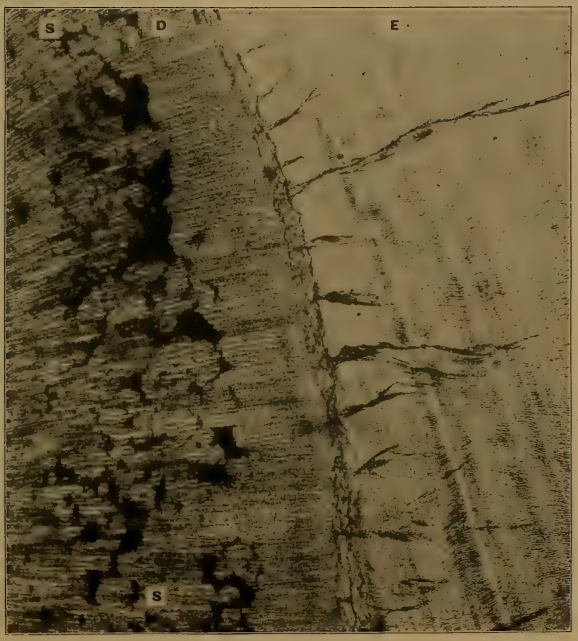

Fig. 32.

Fig. 32. A photomicrograph with a much higher power from another tooth with a similar atrophy to that shown in Figure 31, in which the section was cut horizontally or crosswise. The section through the interglobular spaces is, therefore, through that portion of the line showing in Figure 31, which dips toward the gingival at the buccal and lingual portions of the section. E. Enamel. D. Dentin. S. S. Line of interglobular spaces appearing as irregular dark blotches connecting the one with the other in every direction.

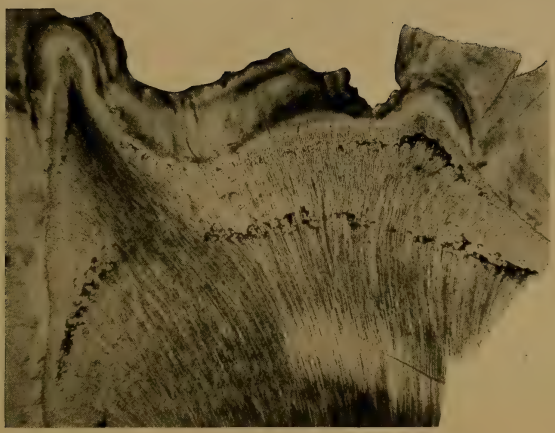

FIG. 33.

FIG. 33. A photomicrograph from a portion of a mesio-distal section of a first molar showing in the section two zones of interglobular spaces. It shows only a part of the mesial half of the section. Note that the line of interglobular spaces nearest the enamel, the first line, follows closely the dento-enamel junction. This follows the prominence of the mesial marginal ridge of dentin (on the left in the picture) and then dips down to the gingival. The line of injury to the enamel also rounds over this prominence and again touches the dentin just above the point of ending of the injury to the dentin. The second, and more marked zone of injury to the dentin, swings out quickly from the dento-enamel junction, on the left in the picture, and runs across much deeper in the tooth, showing the amount of dentin formed before this occurred.

in atrophied teeth. Dentists generally have not realized that the pulps were so close to the surface. When it is realized that these sheets of interglobular spaces, of which the line of atrophy in the dentin showing in Figure 31 and in Figure 33 is a section, spread through the entire area of the crown of the tooth, forming openings through which microörganisms may readily grow, it will be understood why it is so difficult to prevent the destruction of these teeth by caries. It will also be understood how decay may quickly undermine the entire enamel cap, allowing it to fall away, exposing a blackened stump of dentin in all of the central portion with jagged enamel upon its margins, with decay persisting around the circumference where the line, or sheet, of interglobular spaces dips to the gingival near the dento-enamel junction. In the child, one is prohibited from forming a cavity of such depth as required to hold such a broad filling because of the nearness of the pulp of the tooth.

The grave significance of this lies in the fact that caries beginning in the imperfections of the occlusal surface quickly reaches this zone of interglobular spaces and spreads rapidly through it, undermining and destroying the whole occlusal portion of the tooth. It often happens that the whole of this has been swept away so quickly that the area is uncovered before decay has proceeded further toward the pulp. The decaying area is then fully exposed to the fluids of the mouth, and the progress of the caries is arrested. In this case, the tooth remains as a blackened stump that soon rises in its alveolus and occludes with its fellow, which is generally in a similar condition, and both do good service. More often, however, decay continues in that portion of the zone of injury referred to, that dips under the strong enamel around the margins of the crown. Being thus protected, it continues to burrow, finally reaching the pulp and completing the destruction. This is the general fate of atrophied first permanent molars. Case after case comes before me in the great clinic of Northwestern University Dental School, showing atrophy of the anterior teeth in young people. The rule is that the first molars have already been lost. Children from eight to twelve years old are coming often to have these teeth extracted.

Treatment of Atrophied Teeth.

First molars. Such treatment of atrophied first molars as will prevent the results detailed above, is exceedingly desirable. The treatment is required as early as the eighth year, often in the seventh. A few cases may be successfully filled. Cases

which promise good results and in which the child can be controlled to do this work, the fissures should be properly prepared and filled with gold at once when discovered. Generally, however, it will be found impracticable to make the proper preparation and the fillings at so early an age because of failure to control the child. As the rule, it would be necessary to do this during the seventh or eighth year. A large proportion of these cases are too badly decayed before the ninth year for filling, and many of them are decayed to exposure of the pulp, or the occlusal surface is lost during the seventh or eighth year. Ordinarily they will be seen first by the dentist when the child is brought for consultation regarding the deformity of the incisor teeth, the parents not having noticed the deformity of the first molars. Even at that time, in many cases, the first molars will be found badly decayed. This very early appearance of caries in these cases, and the fact that the pulp of the tooth is so often exposed by a decay that seems not to be very deep, greatly increases the difficulty of treatment.

When the teeth can be seen very early, or as soon as they have come through the gums, and the occlusal surfaces are found badly deformed, showing many wrinkles and deep fissures, it is generally best to grind away any small, sharp spiculæ of cusps that are liable to be broken in chewing food. Then, if decay has not actually begun in the fissures, these may be dried out and filled at once with oxyphosphate of copper cement without further preparation. Often such a course will be necessary in order to do anything that will be of service to the child. A good article of this cement is often very adhesive and will remain for a considerable time in a very slight crevice and seems to prevent the beginning of decay. In the deeper fissures in which decay starts earliest, it will do excellent temporary service. When decay has made some progress the softened material should, if possible, be removed after breaking away any undermined enamel, and the cavity thus formed filled with oxyphosphate of copper. In many of these cases even this slight preparation will appear impracticable. The child will need encouragement and a gradual building up of confidence, and often much may be done by making the filling without any excavation that will cause pain and defer the excavation to another time. Such fillings should be examined after a month to note the result and, when necessary, something further may be done. Many children will become proud of what they can do in the dental chair and after a few visits will bear a considerable operation.

In any case, oxyphosphate fillings should be examined as often as once in three months to see that they are doing well and to mend up any failures. In this way these teeth can often be tided along and serious decay prevented until such time as permanent operations can be made.

Those cases in which the condition of the occlusal surface is still worse and in which decay seems to start in spite of the effort to prevent it in this way, a gold cap may be made to cover in the entire exposed part of the crown. After grinding down the more prominent points that will cause the cap to interfere with the occlusion, an impression should be taken in modeling compound. This may be taken in the little impression cups used in crown work. Often these may be cut down considerably to decrease their bulk, which, in the mouth of the little child, is a serious objection. The arrangement should be made to obtain a very sharp impression very quickly. To this end, the softened modeling compound should be placed in the cold cup and allowed to partially stiffen. Then the surface should be warmed quickly over a Bunsen or alcohol flame and quickly conveyed into the mouth and pressed over the tooth. It should be held in position for several minutes, if practicable, so that the mass may become hard enough not to be drawn or marred in its removal. By this plan a very sharp impression can be obtained. From this a gold cap can be formed to cover in the occlusal surface of the tooth and may be cemented in place. There should be no attempt to make a full gold shell crown. It should only overlap the axial surfaces sufficiently to hold it in place. A renewal later, when it can be slipped further over the tooth, should be expected in many of the cases. The gum will cover much of the crown at the age of seven or eight years, and the child will be very sensitive about any pushing away of the soft tissues.

Sometimes it will be impossible to place these without some interference with the occlusion. This will not be of much importance if the interference is not very considerable, for the occlusion is quickly accommodated by movement of the teeth in early childhood. Special attention should be given to the intercusping of these caps that the teeth may not be caused to slide out of position during the process of shedding the deciduous teeth. (See article on the intercusping of the first molars in Management of Children's Teeth.) These caps can often be improved by filling in deep grooves and by some broadening of the occlusal surfaces of the models before they are swedged; and, in doing this, the intercusping can be studied and arranged. Generally

the crowns will have to be made rather flat and the cusps short in order to prevent raising the bite excessively, especially if this must be done after the teeth have come into full occlusion.

These caps should be regarded as a temporary expedient. When the child is older the time will come when the teeth may be permanently filled with gold and the repair made permanent. In the bad cases, requiring considerable gold building, this should not be attempted before the person is eighteen or twenty years old. The pulp is so near the occlusal surface that it will be much endangered if this building of gold with sufficient anchorage be undertaken earlier. In the meantime a careful guard must be kept to see that decay does not begin on the axial surfaces along the gingival margins of these caps and cause trouble. Caps put on in this way at from seven to ten years of age, even if they reach fully under the free margin of the gum at the time they are placed, will be some distance from the free margin of the gum after a few years. If decay occurs, a new cap may be made to cover it.

It is the duty of every dentist having families in his charge to see to it carefully that these atrophied molars are taken care of in this way, or some similar way, very early. After the patient has grown older and the teeth have come further through the gum, other devices may be used if thought necessary.

Some cases may be successfully treated by grinding away a considerable part of the injured enamel and thus gain a smooth surface that will be kept clean by the excursions of food in mastication. This may often be employed advantageously after considerable decay has occurred. For little children it should be done little by little, having them come to the office frequently for this purpose. Particularly this should be the case if any sensitiveness has developed.

Incisors and cuspids. The treatment of incisors and cuspids should be along different lines. In a very large proportion of these cases, no treatment whatever is necessary, for these teeth are not much inclined to decay because of atrophy. Yet, sometimes decay does occur, and if the atrophy is confined pretty closely to the incisal edge, it may usually be treated by grinding away. Often the atrophied portion may be ground away so that the tooth will look fairly well. It will be a little bit short, but the inclination will be to protrude further through the gums and increase its length in that way. If necessary, other teeth in the neighborhood may be ground also, shortening them a little, and in this way the esthetic in appearance may be satisfied,

removing much, sometimes all, of the atrophied portion. Often teeth that are marked by grooves may be made to look very well by grinding the enamel smooth and level, making in this way a fairly good tooth form, being careful, however, not to expose the dentin on the labial surface. Exposure of the dentin on the cutting edge is not very objectionable.

Frequently much harm is done to these atrophied teeth by attempting to fill blackened pits. At the points where these occur, the teeth are often very thin and an injudicious effort to excavate results in cutting through to the lingual surface, and after removing perhaps considerable material to gain the proper anchorage, the operator finds the incisal portion of the tooth too weak to stand. No filling should be made for the purpose of closing up blackened pits, unless it is first found that there is abundant tooth material for strength after the excavation has been made. Also it must be remembered that the pulps of these atrophied incisors are very near the incisal edge as a rule, and exposure of this organ in the excavation is very liable to occur.

Incisor teeth that are very badly atrophied so as to give a bad appearance, should not be treated hurriedly. They should be tided along until such time as the pulps may be removed, not only with safety, but that the roots may be filled in such a manner that they may do service for the lifetime. If they can be kept in position without other treatment than that intended as temporary, until the patient is eighteen to twenty years old, it is very much better that it should be done. Then the crowns can be cut away and artificial crowns put on with the best prospect for future service. Certainly no crowning operations should be undertaken in these teeth before the patient is sixteen years old, and eighteen to twenty is very much better.

Long observation of the removal of the pulps and filling roots for young people shows that these teeth do not do well. It is true that we can remove the pulps and fill the roots of the central incisors at twelve years old in very many cases with results that, within the first year or two, seem perfect, but it is also true that these teeth tend to break down, the roots to split, or some catastrophe is very likely to happen to them before the patient is twenty-five years old, and the teeth are lost.

Many of them suppurate after they have been apparently in perfect health for several years after the root filling has been made. All of these considerations unite to advise that the removal of crowns for the purpose of placing artificial crowns

be delayed as long as possible. The roots of these teeth are just as good for the purpose of artificial crowns as the roots of fully developed teeth; in fact, all of that portion of the tooth root-wise of the atrophied part is normally developed as a rule. In all of this work there is an opportunity for the exercise of great skill and taste in bringing about excellent esthetic effects.

Pits in the Enamel.

Pits in the enamel are a common accompaniment of atrophy of the teeth, but not in any way a necessary part of it, as is shown by the many cases of even the severer injuries in which they are absent. Indeed, in reckoning up the cases coming under my notice, enamel pits seem not to have been present in more than one-fourth of them. Further, these enamel pits occur in teeth that are otherwise normal. It is not very rare to find a single pit in the enamel of some one tooth of an otherwise perfect set of teeth. In exposing such pits by cutting sections, the same histological characters are found as shown by the pits accompanying atrophy. They mark an imperfection, or partial failure, in the development of the enamel rods, confined to a small area, usually round, and evidently are most apt to occur in cases where there has been some marked difficulty in enamel development, resulting in atrophy. Hence, they are a frequent accompaniment of atrophy. Not infrequently, the rows of pits in the enamel are the only signs of injury to the teeth as a result of an illness. In this case the rows of pits form zones on the parts of the teeth contemporaneous in development, as one of the expressions of atrophy. When they occur in the absence of atrophy, they may occur in any part of the enamel, showing no especial preference as to teeth or locality on any tooth.

The pit marks the failure of development of the enamel rods at a point, leaving a hole of more or less depth. This is generally filled, or party filled, with an amorphous material, dark in color, varying from a yellowish hue to a deep black. I have never yet made a section of one of these in which the dentin was exposed, though some are as deep or deeper than the normal thickness of the enamel. In all of these cases of very deep pits there is a depression in the dento-enamel junction, as shown in Figure 34, and a lining of enamel, in which the enamel rods are arranged in a segment of a whorl, all pointing to the center like the spokes of a wheel, in the bottom of the pit. When the enamel rods forming these whorls have grown about a certain length, growth ceases, and an opening is left, and this may extend as an open

pit to the outer surface of the enamel, leaving an opening the full depth. Or this may be filled in part by a dark material not resembling enamel. Or, again, the surrounding enamel rods may close over it, partially or completely obscuring the pit, so as to form a smooth enamel surface over it. In Dr. Callow's case, described later, the deformity consists mostly in numerous examples of these whorls, many of them extending deeply into the dentin. In Figure 34 the enamel rods close over the whorl of rods imperfectly, but leave a ragged pit in the surface of the enamel. That these whorls are sometimes closed over so as to give a perfect enamel surface, is shown in Figure 42, from the occlusal surface of a bicuspid from Dr. Callow's case. These definite whorls are at the dento-enamel junction, or actually partly within the dentin. But many pits are formed within the usual thickness of the enamel without disturbance of the line of the dento-enamel junction, as shown in Figure 35. In most of these cases there is much disturbance of the direction of the enamel rods in the immediate neighborhood as the rule. In some there seems to be a failure of the enamel organ to perform its function of rod formation at the particular spot. In and about many of these pits there is deep discoloration. Many times the dark color is confined to the pit itself, which is partially filled with a substance strongly resembling the chittinous covering of insects in appearance and in which no enamel rods can be made out. In other cases the dark color extends broadly in, or among, the enamel rods about the pit.

In these pits the disturbance follows the general direction of the enamel rods in the locality. This is as true of the pits that accompany atrophy as those that occur without atrophy. In this the pit is distinctly different from the other injuries to the enamel in atrophy, for these as uniformly follow the lines of Ritzeus, i. e., the lines of accretion.

I have been unable to form any idea of the pathology concerned in the formation of these pits. Their special prevalence in atrophy cases indicates that they are due to disturbances of nutrition. They consist essentially in a failure in the formation of enamel rods. But such remarkable disturbances as those shown in Dr. Callow's case, described next, indicate that there may be some other pathological element not yet understood. Histologically, they seem to be a very distinct form of atrophy. The rule is that these pits need no treatment. They rarely decay, but as there is a slight opening and the tissue is often black or dark colored for a little bit around it, dentists frequently

cut them out and make fillings. There is no reason for doing this unless softening has occurred, or in other words, unless decay has actually begun. Of course in that case the filling is the proper procedure, but not otherwise.

Other Deformities of the Enamel.

In examining the teeth of many people, other deformities of the enamel than atrophy and the pits above described are occasionally met. It is desirable that these be distinguished and separated from typical atrophy. Generally, this is easy if we keep the typical forms of atrophy in mind. Atrophy, due to suspension of nutrition, affects certain parts of certain teeth, following the lines of contemporaneous development, and when this is seen in any one tooth, certain parts of certain other teeth are marked and all others have escaped. Therefore, if we find a case in which a certain part of each tooth of the whole set is pitted and rough, or grooved, the injury or deformity not following the lines of contemporaneous development, we have found another condition entirely and should separate it sharply from the form of atrophy above described. How many such cases have been confounded with atrophy in the past that have no histological or causal relation to it can not now be told. That some have, there is no longer room for doubt. I have collected a number of such cases. I shall describe only some of the most notable cases coming under my observation. I shall not try to group these into special kinds of deformities, for the reason that I have not studied a sufficient number to arrive at general conclusions.

GENERAL DEFORMITY OF THE ENAMEL.

I received from Dr. J. E. Callow, of Antigo, Wisconsin, sixteen teeth removed by him for a young woman who applied to him for treatment. They included incisors, cuspids, bicuspids and molars. The condition of these teeth, as indicated by their outward appearance, is very fairly shown in the photograph, Figure 36, of a cuspid, bicuspid and molar. All of the others were similar. Examination of these teeth showed that the injury to, or the deformity of, the enamel had no relation to contemporaneous lines of calcification. Histologically, although there were scattered interglobular spaces, there were no markings in the dentin that bore any relation to those that occur in atrophy. Either of these were sufficient to distinguish it as something different from atrophy. In all of the teeth, from incisors to

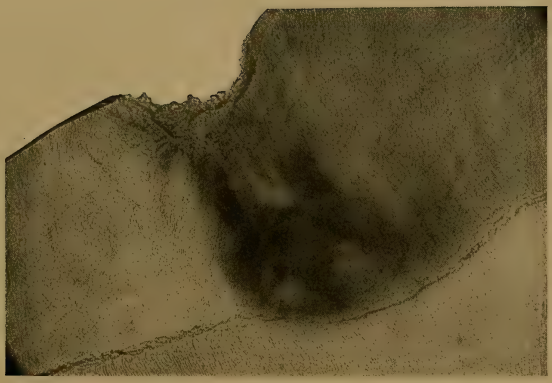

Fig. 34.

Fig. 34. A photomicrograph of a deep pit in the enamel, beginning in a whorl of enamel rods at the dento-enamel junction. Much of the pit is filled with amorphous material.

Fig. 35.

Fig. 35. A photomicrograph of a pit in the enamel beginning in the midst of enamel tissues, showing a failure of the development of enamel rods. The pit is nearly filled with amorphous material, very dark in color, and much of the enamel in the neighborhood is discolored.

Fig. 36.

Fig. 36. A cuspid, a bicuspid and a molar tooth from Doctor Callow's case. These are fair representatives of the appearance of the other teeth from the same mouth, from several of which sections were cut.



FIG. 37.

FIG. 37. Portion of buccal enamel from near the buccal cusp of a second molar from Doctor Callow's case. Note that the dento-enamel junction, which shows plainly at the right in the picture, is completely broken into small whorls in all of the left portion. While there is a portion of regularly formed enamel on the right, all of the enamel on the left portion is broken or twisted out of semblance of ordinary enamel. Also note the tubclike opening to the surface near the middle of the illustration. These features are found to be repeated with differences of detail in the other illustrations.



Fig. 38.



Fig. 39.

Fig. 38. Portion of enamel from near gingival line on the buccal surface of a second molar from Doctor Callow's case.

Fig. 39. From the buccal surface of a first molar, near the buccal cusp, from Doctor Callow's case.

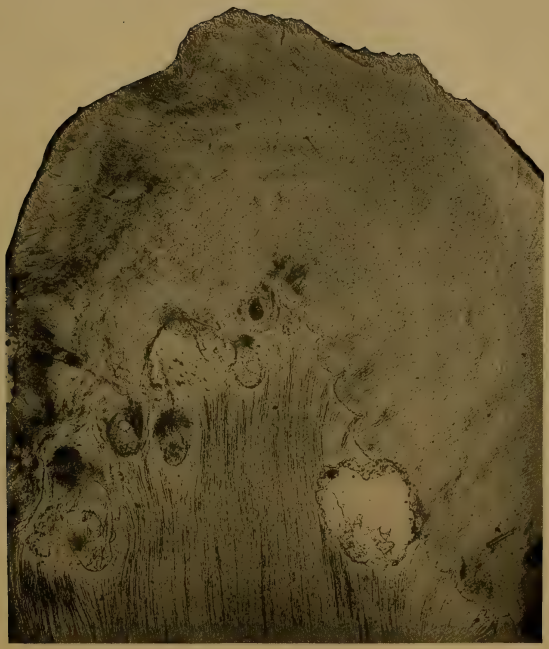

Fig. 40.

Fig. 40. Buccal cusp of a second bicuspid, from Doctor Callow's case.

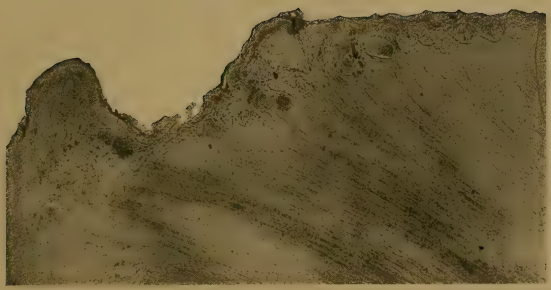

Fig. 41.

Fig. 41. Distortion of enamel on lingual surface of a bicuspid, from Dr. Callow's case.

Fig. 42.

Fig. 42. Enamel pits closed over, leaving cavities, over which a fairly smooth enamel is formed. Occlusal surface of a bicuspid, from Doctor Callow's case.



Fig. 43.

Fig. 43. A bit of enamel appearing in section as an island in the midst of the dentin in a bicuspid, from Doctor Callow's case.

Fig. 44.



Fig. 45.

Fig. 44. Enamel from near the cusps of a tooth in Doctor Prunty's case, showing the enamel rods breaking into bundles which end in spiculæ. This enamel had no cementing substance between the enamel rods. Its color was a dead paper-white.

Fig. 45. A scrap from one of the best parts of enamel found in Doctor Prunty's case, showing the rods to be without cementing substance between them.



Fig. 46.

Fig. 46. White spot in the enamel of an otherwise normal tooth. In the white area the enamel rods have no cementing substance between them. They have a covering on the surface, however, that has the usual hard glaze common to the surface of normal enamel. This is Naysmith's membrane.



Fig. 47.

Fig. 47. White spot in enamel. At the right, little bundles of rods are seen to be without cementing substance between them.

third molars, the deformity was greatest on the axial surfaces and least on the cutting edges and cusps. The surfaces were extremely rough and uneven, presenting sharp spiculæ or knobs and deep pits in the utmost irregularity of form. Over some of the cusps the enamel seemed to be normally thick, but did not have the smooth glazed surface of normal enamel. Only occasionally a small area would show the normal smoothness. In most of the teeth the enamel assumed a normal appearance suddenly near the gingival line, and this normal part generally encircled the tooth, joining the cementum in a normal gingival line.

Figures 37, 38, 39, 40, 41 and 42 are photomicrographs showing the histological characters of the enamel. In most of its parts the dento-enamel junction is lost in a wild jumble of circular whorls or protrusions of enamel into the dentin. Quite a number of these whorls are hollow and empty, while some are filled with amorphous material, but all of these, without exception, are lined with enamel, usually in the form of segments of whorls, as these are found in the bottom of other enamel pits. In some this lining is very thin. Some of these hollows communicate with the surface by small tubelike openings, forming very deep pits, Figures 37, 39, while others seem to be closed on all sides, Figures 37, 40, 42. In occasional patches, even where the enamel began in these whorls along the dento-enamel junction, the rods to either side straightened up and closed over them into a fairly well formed enamel, as shown in Figure 42, from the occlusal surface of a bicuspid. Still, most of the formed enamel is a wild, twisting, curving and bundling of enamel rods. With all of this the enamel formed seemed to be of normal hardness in every part. In a considerable number of places the enamel is plunged deeply into the dentin in long prolongations that were too large and long to permit photographing with any lens with sufficient amplification to enable the structure to be distinguished. Figure 43 shows a little part of one of these appearing as an island, midway between the cementum and the pulp canal, considerably root-wise of the gingival line. This is not an actual island of enamel, however, for it was traced as a part of a very long projection from the dento-enamel junction near one of the cusps of the tooth. Fortunately, I used my sectioning machine and had cut these teeth in very thin slices, so that I was able to follow such a growth through several sections. In general, the pictures given show the characters of the departure from the normal very much better than it can be portrayed in words. In

this case I could get no indication of any other abnormal condition of the patient. She seems to have been otherwise a normal and healthy girl.

Many of the teeth were badly decayed and it is represented that all of them, whether decayed or not, were abnormally sensitive to sweets, heat and cold, and to acid fruits. Also, that this condition of sensitiveness had been persistent since the eruption of the teeth. This sensitiveness was so continuous and severe that it led finally to the removal of all of the teeth for relief. In all of my observation this unique case stands alone. Considered as a whole, I have studied nothing else like it. I have, however, observed in the mouth a number of cases that may have been of this character. The definiteness of the deformity and the perfectness with which this definite histological character was repeated in each tooth examined, indicates that it is a deformity to which the teeth are liable. This is emphasized by the frequent observation of the tendency seen along the line of the dento-enamel junction to form scallops and whorls in teeth otherwise normal. But I know nothing of the conditions leading to this kind of deformity.

Dr. M. C. Smith, of Lynn, Massachusetts, presented casts of a case at Buffalo, at the meeting of the National Dental Association, 1905, which seemed to me to be of the same character. When I examined these models, no teeth had been extracted and no opportunity presented for a histological study. Dr. Smith's case presented the same difficulty as to sensitiveness.

White Spots in the Enamel.

White enamel is seen in occasional white or ashy gray spots occurring in the enamel of teeth otherwise normal in color and form. These white spots are usually small and are covered with the ordinary glazed surface of the enamel, so that an exploring tine will glide over them the same as over the perfect enamel. If, however, the spots are large, this glazed surface fails to cover the central portion, being projected but part way from the margin toward the center. In that case, the central area is rough, and an exploring tine enters the enamel without difficulty. Such spots as these latter are rare. Sometimes such a spot shows discoloration about its central portion or radiating through it in irregular lines or blotches. The smaller white spots covered with the glazed membrane are common in any great school clinic where large numbers of persons are present for dental operations.

A histological examination of these shows the enamel rods to be normal in their formation and continuous with the rods deeper in the enamel, which is altogether normal in form and color. Generally the smaller white spots that appear on the surface of the enamel do not extend through its thickness. It often ends abruptly in a line following the incremental lines of enamel formation, i. e., the lines of Ritzeus, as seen in Figures 46, 47. In the area of the white spot there is no cementing substance between the enamel rods. This is the histological characteristic of all of these white spots that I have yet examined. This is, therefore, an atrophy affecting the formation of the cementing substance between the enamel rods the same as certain of the pits in the enamel are an atrophy of the enamel rods. While white enamel usually occurs in small spots occupying but a small amount of the surface of a tooth, they are occasionally much larger, and I shall relate cases in which all of the enamel of all of the teeth of the person was of this character.

WHITE ENAMEL.

I received fourteen teeth from Dr. D. J. McMillen, of Kansas City, which had been extracted by Dr. John Prunty, of Boyd, Texas, for one patient, all of which were deformed in what, from macroscopic examination, seemed a similar manner to that described in Dr. Callow's case. The teeth were very dirty with blood stains and from being handled, which obscured some of their most notable characters. But a closer examination showed the enamel to be soft. I found that it could easily be picked to pieces, and evidently much of it had been lost in this way since the teeth were extracted. The axial surfaces were made up of irregularly formed spiculæ that rendered them extremely rough. Many of these had been broken, so much so, indeed, that it was with some difficulty that I was able to get sections showing the condition at the time the teeth were extracted.

When I came to the making of sections of these, I found the enamel white through its entire thickness, not the white bluish color of enamel, but the white color of unglazed white paper. The enamel had seemed so frail that I had soaked the teeth in thin balsam and then thoroughly dried them, in order to retain the spiculæ of enamel. Afterward I was sorry that I had not used shellac for this purpose, for in some of my sections these spiculæ floated about in the balsam in which the mount was made, as soon as the slight amount of hard balsam left after grinding had dissolved in the softer balsam in which it was mounted. The

shellac, which does not dissolve in balsam, would have saved me this chagrin.

This case proved to be something entirely different from Dr. Callow's case, histologically. The dento-enamel junction was perfectly normal in all its parts. Next to the dento-enamel junction the enamel was in perfect form. But after a slight growth the enamel rods broke up into bundles that became smaller, and evidently these bundles had ended in spiculæ. I found none of these that had not been broken, though I found patches with the mucoid film formed in the mouth still over them after grinding the sections, which showed conclusively that the spiculæ had not been broken after the teeth were extracted. Figure 44 shows this and indicates very well the manner of the formation of these spiculæ. Evidently the finest of these had been broken after the extraction of the teeth. In many places very little enamel remained.

This enamel throughout all its parts was almost wholly without the cementing substance between the rods. Figure 45. Histologically, this was the principal deformity. I became satisfied from my examination that the rods themselves were fully hard, but they were not cemented together and broke apart with the greatest ease. Indeed, much of the enamel came to pieces after it was mounted and the rods became scattered in the balsam. I have no idea what controlled the formation of the spiculæ which constituted the principal outward deformity. In the mouth the teeth must have had a dead paper-white appearance.

I have seen but one other case presenting a general absence of the cementing substance between the enamel rods. A laboring man came into the clinic at Northwestern University Dental School several years ago, whose teeth presented this dead paper-white appearance. Every tooth, and every part of every tooth, had this appearance. There was no deformity as to form. But Naysmith's membrane, which usually covers the enamel and forms the glaze of the surface, was absent. The teeth were of usual size, of good contour, and regular in the arch. He said they had always been so and he had been greatly annoyed because of the attention their peculiar color attracted. The man was twenty-eight years old. There were some points on the cusps where the enamel was worn enough to show the dentin, but generally the wear was not excessive. He said he could chew food as well as anybody. There were three small proximal cavities in the bicuspids; otherwise the teeth were sound.

I partially excavated one of the cavities, found the dentin

apparently of usual firmness, but the enamel seemed to crumble to pieces easily. Not only the walls of the cavity crumbled, but I could easily push a sharp explorer into the enamel of other teeth anywhere. I took some of the cuttings from the enamel walls of the cavity well beyond the decayed area and distributed them in glycerin under a cover-glass, and with the microscope found well-formed enamel rods that looked much like those that had been separated by a very weak acid, or those taken from the whitened enamel in backward decays.

This condition of the enamel had not rendered the teeth more than ordinarily liable to caries, as was shown by the general soundness of the teeth.

This condition reminded me strongly of the white spots so often seen in the enamel of teeth that are in the main perfectly formed; and is undoubtedly of the same character, Figures 46, 47. The only difference seemed to be that the usual white spots seen are covered with a very perfect glaze, or Naysmith's membrane, so that a sharp instrument will glide over them. This man's teeth had no such glazed surface. A sharp explorer would catch anywhere with very little pressure. In fact, it would not glide over the surface at all. The teeth evidently had not a normal Naysmith's membrane. The enamel in the two cases seemed very similar to cutting instruments. Since writing the above statement, another case has come under my observation in which the incisal portion of the incisors and cuspids and the occlusal portion of the bicuspids and molars were covered with normal enamel, but a large part of the axial surfaces were white enamel, much of which lacked the glazed covering, or Naysmith's membrane. At all points this glazed membrane was projected to some distance from the normal over the abnormal enamel.

These cases, taken together with the frequent occurrence of white spots, led me to the supposition that the failure of the cementing substance between the enamel rods is a special form of atrophy or abnormality in formation to which the enamel is liable. The occurrence of this in isolated spots, which are usually of an ashy white color, is not very uncommon, but its occurrence in the whole of the enamel in the teeth of a person is certainly extremely rare. I have seen this in but the two cases mentioned, in the one with abnormal form, in the other with normal form.

Nothing seems to be known of the pathology that brings about this condition.

The study of such cases is of great importance, as it may

lead to further knowledge of the formation of this tissue. Certainly the facts developed show that either the functioning tissue or the functioning of the tissue that forms the enamel rods is so different from that which forms the cementing substance between the rods that the rods may be formed and the cementing substance fail. Also, we have seen in the illustrations many failures of the enamel rods with the space filled in part with something else apparently without histological form. This something may be the cementing substance that should be only between the enamel rods. According to this view, atrophy of the teeth presents three distinct phases:

(1.) An atrophy due to a period of malnutrition, affecting those parts of several teeth at the time in process of formation. This may cause the failure of formation of all parts of the enamel and dentin in the zone involved, as seen generally in atrophied teeth.

(2.) An atrophy of the enamel rods occurring in spots, as seen in pits.

(3.) An atrophy of the cementing substance between the enamel rods, as seen in the white spots often seen in the enamel, and in the enamel of the whole denture in rare cases, as in the two I have described.

The first is clearly due to a general malnutrition and is seen only on the parts of teeth contemporaneously in formation at a period of illness. The second is in part seen to occur in process of general malnutrition, but often occurs independently of this, so far as can now be discovered. The third, so far as can now be seen, depends upon some condition of malnutrition as yet unknown.

I think Dr. Callow's case should be regarded as a deformity, not an atrophy.

EROSION OF THE TEETH.

ILLUSTRATIONS: FIGURES 48-62.

EROSION is a term applied to a peculiar and very characteristic loss of substance of the teeth, beginning in the enamel, or upon its outer surface, and slowly working its way inward and spreading, destroying and removing the substance of the tooth as it goes. At first it presents no symptoms whatever except this loss of substance, and this looks like a facet that would be left after grinding slightly with a very fine stone. There is no softening whatever, but simply a wasting of the substance, leaving a perfectly smooth, polished surface; a surface so smooth and polished and hard that an explorer passed over it will glide just as smoothly upon the eroded surface as upon the enamel that is perfect. The facet first formed gradually deepens and widens, progressing very slowly in most cases, until the enamel has been cut through. Then the dentin wastes away in a similar fashion, and so smoothly that there is no line of demarkation between the enamel and the dentin. When the enamel has been penetrated and the dentin begins to be eroded, the dentin becomes very sensitive. This sensitiveness is characteristic of erosion if in living teeth. Teeth that have lost their pulps may suffer from erosion in precisely the same way, except that in these there will be no sensitiveness.

Erosion is usually slow in its progress. The facets may appear upon the enamel and be seen for a considerable time before the enamel is penetrated; as a year, two years or more. It proceeds directly and steadily, in a large proportion of cases, until the teeth are destroyed, requiring from three to ten years, or even more, to cut through and destroy a tooth. In other cases the progress ceases spontaneously, or the progress may be intermittent.

The position of erosion is most commonly the buccal or labial surfaces of the teeth. It is yet uncertain whether it appears oftenest upon the incisors or upon the bicuspids and molars. Sometimes, however, it will begin upon the proximal surfaces, and a few cases have been observed upon the lingual surfaces. When it has begun upon a surface of a tooth, the

general rule is that it does not spread to other surfaces, i. e., if it has begun upon a labial surface there is rarely a disposition to begin upon a proximal surface or a lingual surface, but it will be confined to labial surfaces; it will, however, spread to other labial surfaces in the neighborhood. For instance, if it begins upon a labial surface of a central incisor — which is not an uncommon place of beginning — it is likely to spread to the labial surface of the other central incisor and to the labial surfaces of the lateral incisors and cuspids, spreading from before backward. If it begins upon a first molar it is liable to spread to the second and third molars and to the bicuspids, and in most of these cases it will be bilateral, though occasionally we find it unilateral, not occurring upon the opposite side at all. It may also apparently spread from the upper teeth to the lower, or vice versa, but continuing upon the labial or buccal surfaces, not involving other surfaces of the teeth. If it begins on proximal surfaces, proximal surfaces only will be affected. But it will spread from tooth to tooth.

Diagnosis of Erosion.

One who has carefully studied the conditions of the eroded areas in a few cases should have little difficulty in recognizing it in any of its forms. It should be remembered that the form or location of the eroded area is not distinctive, for the reason that a great variety of forms of area and of location are presented. The area of eroded surface is always smooth and glossy, and a sharp explorer held lightly in the fingers glides over it the same as over enamel. This distinguishes erosion from beginning caries, but does not distinguish it from abrasion. All facets occurring on the occlusal surfaces of the teeth should be regarded as abrasion. An examination should be made that will certainly exclude abrasion from any cause such as the rubbing of the particular part against another tooth, or rubbing by some artificial appliance, or the possible grinding by a stone for any purpose. With these excluded, a definite facet of any form that is hard, smooth and glossy, is distinctive of erosion. So long as this is in the enamel only, it will be the only symptom. A tooth with a living pulp will usually become sensitive when the dentin is reached, but in cases that have made much progress slowly in dentin, the pulps of the teeth may become much calcified, and the sensitiveness will disappear on account of the cutting off of the dentinal fibrils by the calcification. Obviously there will be no sensitiveness when erosion occurs in pulpless teeth. In

case the progress of erosion ceases, the sensitiveness of the exposed dentin soon disappears also, and the dentin may become discolored. All of these points must be considered in making a diagnosis of erosion. It will be seen from the foregoing that the one fact of loss of substance without apparent mechanical cause, leaving a smooth, glossy surface in dentin, or in enamel, or in both, is the distinguishing feature of erosion.

FREQUENCE OF EROSION.

As to frequence of occurrence, erosion is rare as compared with caries. Formerly my estimate of this was that less than one person per thousand had erosion of their teeth. Certainly it was very rare among my patients in Jacksonville, Illinois, though I saw a good many more than my proper share through consultations. For some years after I began teaching operative dentistry, and had opportunity to see the larger proportion of the patients in the clinic, they still were not plentiful. Finally I asked the Examiner to call my attention to every case he could find among those applying for treatment of any kind. This brought out so much larger proportion of cases as to cause me to believe that many had been overlooked previously. It is probable that very many cases are overlooked by practitioners. The evidence on this point, however, remains very uncertain.

Among the patients applying at our clinic, about one per cent of erosion is found. These people are mostly friends of the students. They are not of the very poor nor of the wealthy. I find among them erosion of every variety of form that I have seen elsewhere, but the rounded cuts across the teeth that tend to become stationary, or cease to progress, seem to be in the majority. Many of these cases stop spontaneously before any considerable injury is done.

Erosion is much more frequent in some certain classes of people than in others. Considerable inquiry has been made among practitioners regarding this. Some seldom see a case, while others find it very frequent. Especially those whose practice is confined closely to very well-to-do people find it most frequent, and of a character to do the greatest injury. One practitioner who has a practice among well-to-do Jewish people stated that all of his patients had erosion and insisted that that was literally correct. I then asked him to take as many casts as he could for me. Within a few weeks he turned over so many that his statement seemed to be fully justified. Not many practitioners can make casts of fifty to seventy cases of erosion from their own

patients within five or six weeks. He gave me a set of casts from a young man of twenty, his father, his grandfather and his great-grandfather, all taken the same week, each showing erosion. This practitioner is fully convinced by his observations among these people that erosion is hereditary. They are practically all descendants of a few Jewish families who settled in this country many years ago, who have been very much devoted to the maintenance of their especial set. From the descriptions first given of erosion among these people, it was expected that much of it would be of one character as to form, but the examination of the casts revealed a wide variety of form, so much so that one could not say that any one particular form prevailed to the exclusion of others. There were among them two cases of marked erosion of proximal surfaces, cutting holes between the bicuspids.

I have also supposed from my reading of the literature, and especially from examination of illustrations, and from inquiry in certain localities in this country and abroad, that certain forms prevailed in certain localities.

FORMS OF EROSION.

ILLUSTRATIONS: FIGURES 48-62.

Dish-shaped areas. One of the very common forms of erosion we may describe as a dish-shaped excavation, in which the center of the eroded area is deepest, and from this it rounds up to the surface of the enamel in every direction. This may attack a central incisor first and spread to the teeth at either side of the tooth first attacked, hardly ever exactly bilateral, but usually more extended on one side of the mouth than the other, destroying the labial surfaces. Its place of beginning varies from the middle of the gingival third to the mid-length of the crown. Mesio-distally it is usually about the center, but if there are irregularities in the positions of the teeth it is most likely to begin on the most prominent part.

It first forms a little facet upon the enamel, then destroys more and more, and finally passes through to the dentin, cutting without any distinction whatever between the dentin and enamel, and increasing the size of these facets until the whole labial surface has been removed, not touching the proximal surface, and not touching the incisal except as it is approached from the labial. This form is represented in Figure 48. There is frequently an offshoot from the true dish shape toward the incisal,

Fig. 48.

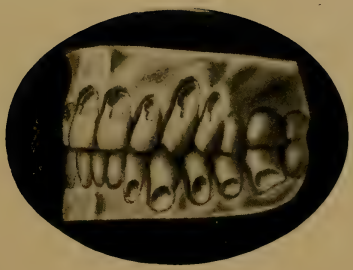

Fig. 49.

Fig. 48. A case of erosion occurring in the teeth of a woman twenty-eight years of age. These are dish-shaped areas, with projections toward the incisal edge, which are plainly seen in the lower central incisors. Otherwise it is a case of typical dish-shaped areas. A picture by myself from the same cast was published in the "American System of Dentistry."

Fig. 49. The dish-shaped areas complicated with recession of the gum, with projections extending from the dish-shaped areas toward the incisal edges, in the upper teeth. These extensions have a very characteristic squareness of their angles. Patient, a man forty years of age.

particularly in the central incisors and cuspids above and below, and sometimes in other teeth.

In examining the illustration it will be noted that in this case the lower centrals present an offshoot which has hollowed out the labial surface to the cutting edge. The same has been done in the upper central incisors, but the eroded area has become so large in these as to almost obscure this feature. It occurs in no other teeth in this case.

Figure 49 also presents the dish shape of the eroded areas, but in this case it has two complications. There is recession of the gums and the dish-shaped portion of the erosion is largely in the cementum, but cutting the cementum, enamel and dentin without distinction. This complication of recession of the gums with erosion is not uncommon. The erosion never passes under the free margin of the gum, and while the gum may be tumified or swollen, it is rare that it ever laps over into the eroded area, differing markedly from caries in this respect. Some of the cases look as though the recession of the gum may have been caused by the erosion, but we see many cases of recession of the gum of similar character without erosion. We also see many cases of erosion cutting away the teeth very close to the gum without recession of the gum. It would therefore seem that there is no causal relation between the two. Figure 49 also has a second complication not so frequently seen, in the squared-out projections toward the incisal from the dish-shaped portion which were noted in Figure 48. In this case the progress, however, has been much less and these curious projections are cut squarely into the tooth but little more than through the enamel, and with square angles toward the incisal. They do not appear in the lower jaw, but appear in every tooth eroded in the upper jaw. This case was bilateral, being much alike on the two sides.

Wedge-shaped areas. These are the *"keilformege defecte"* of German writers. This form usually has its place of beginning near the free margin of the gum, and if seen at its beginning looks like a little groove cut across the crown of the tooth from mesial to distal. These gradually deepen, and soon the case looks as if a wedge-shaped piece had been cut out of the labial surface of the tooth, presenting a flat side reaching toward the gingival and a square shoulder toward the occlusal, as if filed away with a square file. In many of the cases the cut is as square and the angles as sharp as they could be made with such an instrument. In others there is more inclination to rounding of the angle in the deeper part of the cut.

I had supposed that this form of erosion was the prevailing form in Germany, for in taking up the German writers I have found that generally they have illustrated this form only, and generally speak of erosion as the "*keilformege defecte*" (wedge-shaped defects). Upon inquiry, however, among German dentists, I find that other forms are also found, but they think this one the most common. I have seen a number of cases of this form in which the teeth were cut through so deeply that they finally broke away, cutting through the calcified pulp without any distinction whatever from other parts of the dentin. These wedge-shaped areas occur both in the upper and lower jaws, less frequently in the incisors in the upper jaw, but more frequently in the bicuspids and molars. It is not very uncommon to see this form in the bicuspids and molars, and some irregular forms or dish-shaped areas in the incisors and cuspids.

In Figure 51 is shown what appears to be a modification of the wedge-shaped areas of erosion, occurring in two bicuspids. In the deeper parts the cuts are well rounded from the occlusal toward the gingival margins, but are flat mesio-distally. The form is that of a segment of a cylinder. We see this form most in bicuspids and molars, but it may occur in the incisors as well. In the incisors, however, it is not apt to cut very deeply, so far as present observation shows. It is more likely to thin out and spread broadly over the labial surface of the tooth, producing a flat labial surface.

In Figure 52 is presented a specimen of this, occurring in the incisors of a young lady about nineteen years old. Three casts of this have been made about one year apart, watching its progress. The picture presented here is from the first cast taken, and the erosion at that time had been noticed only about one year. It has not gone deeper since, but has spread considerably more toward the incisal. At the last observation it seemed to have become stationary, all sensitiveness had disappeared and the teeth were perfectly comfortable. The cutting is so shallow that the teeth are not deformed so much as to be noticed in ordinary conversation. It required careful adjustment of light to get sufficient light and shade to make a good picture.

Flattened areas. The tendency seems evidently toward the flat form, which is prominently presented in Figure 53. This case was from a man about sixty years old, a laborer. He had apparently taken no care of his teeth, and claims that he never used a brush in his life. In this it will be noted in the cuspid on the left of the picture, that the cutting has begun and gone

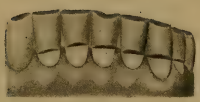

Fig. 50.

Fig. 51.

Fig. 50. The wedge-shaped areas of erosion, or the "keilformege defecte" of German authors. An excellent example of that form of erosion in which a wedge-shaped piece is removed. In this case the thin edge of the wedge is toward the gingival margin. Only the lower teeth are eroded. Patient, a woman about forty years of age.

Fig. 51. A modification of the wedge-shaped areas of erosion in which the bottom of the cut is well rounded instead of a sharp angle. This form is frequent in the bicuspids and first molars. Patient, a man thirty-five years of age. No other erosion had occurred in the mouth.

Fig. 52.

Fig. 53.

Fig. 52. An early stage of what promises to be the flat form, which, in its earliest beginning, is often much like the wedge-shape. The extension is toward the incisal and there is an absence of the cupping from mesial to distal. In these, the cutting is generally shallow. Patient, a girl nineteen years of age.

Fig. 53. The flat form in an advanced stage, but with a cuspid but little advanced, and a triangular patch of enamel still left on one lateral and one central incisor of the upper jaw. A man about sixty years of age; a laborer, who avers that he never owned or used a tooth brush.



Fig. 54.

Fig. 55.

Fig. 54. A flat form which ran a very rapid course, complicated with erosion of the proximal surfaces. The small figure on the right is a labio-lingual section, intended to give more definite information as to the loss of substance. The incisors were destroyed within five years after the erosion was first seen. From a man of wealth about sixty years of age.

Fig. 55. A flat form complicated by erosion of the proximal surfaces, which are also flat. No erosion of the lower teeth or any of the bicuspids or molars. The upper incisors had overlapped the lower normally before the erosion shortened the teeth. This case presented extreme sensitiveness of the eroded areas. A man twenty-eight years of age, a bookkeeper.

Fig. 56.

Fig. 57.

Fig. 56. A type of the irregular form. Some of these present singular extravagances. Man, about forty years of age.

Fig. 57. The pattern form, or figure cutting. In this particular case, in the right central incisor one horizontal and one perpendicular groove are cut, which are joined, forming a right angle, and there is also a groove in the labial portion of the incisal edge joining at a right angle with the perpendicular groove. A similar figure is being outlined upon the opposite central incisor. Patient, a girl, nineteen years of age.

but a little way. In the lateral incisor nearly all of the labial surface has been removed, but a triangular patch is left at the incisal edge, in which the enamel seems not to have been injured in the least. In the central incisor on that side, another triangular patch of enamel is left, next to the proximating central, in the same condition. On these triangular areas the surface of the enamel remains perfect. In the opposite lateral incisor and cuspid there is some cupping of the surface, but they are nearly flat. The incisors are cut pretty deeply at the gingival portion of the crown. The gums are in very good condition. It will be noticed that the lower teeth are irregular and that the cuspid on the right of the picture occludes evenly with the upper incisors. This cuspid presents a perfectly flattened labial surface throughout its extent from mesial to distal, but from incisal to gingival it is a little concave. The lateral incisor next to it is cut through its length as though it had been cut in a planing mill, it is so level and perfect, with almost perfectly squared edges on either side of the cut, the progress seeming to be to the mesial and to the distal of the central cut. These characteristics are not so often seen as some of those described earlier, and this case presents very remarkable peculiarities in the triangular patches of enamel left at the time the cast was made.

Figure 54 presents another case which, while it looks similar, is really quite different. This occurred in a man about sixty-five years old, and had been seen and watched for a number of years by one of our most intelligent practitioners. The course of the erosion was very rapid, occupying but between three and four years. In this the erosion began near the center of the labial surfaces and spread more rapidly toward the incisal than toward the gingival, and the incisal edge was soon invaded. The proximal surfaces also began to lose material and the centrals spread apart. In this case there was not the perfect smoothness of surface usually seen in cases of erosion, and it reminded me very much of a case described by Dr. Kirk, in which he thought there was an inclination to softening upon the surface, although there was no actual softening discernible. The teeth in this case, Figure 54, gave a great deal of trouble from sensitiveness, but artificial crowns placed upon them are doing very well.

The next case, Figure 55, is somewhat similar in its nature. This case was brought in to me for advice by the dentist in charge, and when I first looked at the mouth at a distance of a few feet, my impression was that the upper incisors were retained deciduous teeth, but closer inspection dispelled this idea at once. The

gentleman was about twenty-eight years old, and the normal wear where the lower teeth had occluded against the lingual surfaces of the upper incisors was unmistakable, showing that it had not been very long in progress. The teeth were so sensitive that the patient was greatly annoyed, and was seeking relief. The teeth were cut in such a way as to cup them out slightly upon the labial surfaces. The proximal surfaces were wasting perhaps as much as the labial surfaces, but were cut pretty squarely almost as though they had been filed. The teeth showed no traces of scratches of any kind, but they were not as smooth and glossy as most cases of erosion; they were more like the one last described. In this case I advised that porcelain crowns be placed on the teeth after devitalization.

Irregular areas. In Figure 56 is presented another class of case entirely, which will be described under the head of irregular areas. In this case there are grooves passing across the teeth from mesial to distal, not always at the same angle nor of the same depth, some appearing upon the mesial most, and others appearing upon the distal most, and so on. Occasionally I see this with the groove reaching not more than half across the labial surface of the tooth, but cutting very deeply; in fact, they may present almost any form, but generally in grooves from mesial to distal.

In one case that came under my observation a single groove was cut across the teeth at about the middle of the length of the crown, less than two millimeters wide, and cut squarely in, fully one-half through the tooth, affecting the two centrals and one lateral. This case occurred in my own practice a number of years ago when I was trying to prevent the spreading of erosion by filling, and in this case it was cut so squarely that I filled with gold the cavities formed in the centrals without any excavation whatever. I had the satisfaction of seeing these fillings remain perfect until the time of the gentleman's death, some ten years later. No renewal whatever of the erosion occurred. In a large collection of casts, a good many of these irregular cuts may be found.

Figured areas. In Figure 57 is presented an illustration of what may be designated as figure cutting in erosion, that is, cases in which the erosion takes a form of some particular complex type. In this, in the central incisor on the left of the figure, a rounded groove is cut across the labial face of the tooth near the junction of the middle and gingival thirds. From that a groove is cut along the mesial border straight to the incisal edge,

FIG. 58.



FIG. 59.

FIG. 60.

FIGS. 58, 59, 60. Pattern form more advanced. The cut across the root of the tooth was made with the file for the examination of the condition of the pulp chamber as to calcification. Notice that a second groove was starting on the distal portion of the crown. Figure 59 shows the depth of the perpendicular groove at the incisal edge, and Figure 60 the depth of the horizontal groove.

and then the incisal edge is squarely grooved across the labial portion of its edge. The cutting upon the fellow central incisor has started in the same way and will follow the same course. A case seen a number of years ago with Dr. Cushing was almost precisely the same as this in figure, except that the groove reaching the incisal surface, grooved the incisal surface and then extended to the lingual along the mesial margin of the lingual surface. The teeth were long cusp teeth. They were practically unworn and there was no reason whatever to attribute the grooving on the lingual surface to abrasion.

Figures 58, 59 and 60 illustrate another case of figure cutting that is much more extensive. In this case there was no grooving of the incisal edge, or along the incisal edge, only a slight broadening of the groove on the mesial side, and it will be noted that a similar groove is being cut upon the distal portion of the labial surface, while there is a curious half dish-shaped form on the distal end of the groove running mesio-distally. In this cutting, the angles with the surface of the tooth are very sharp, but the bottoms of the grooves are well rounded. The depth of the cut from the transverse groove to the incisal is shown in Figure 59, while the depth of the cut across the labial surface is shown in Figure 60.

It was clearly apparent in examination of the tooth, that the groove running mesio-distally had cut through the calcified pulp. The incisal edge of the tooth had been much worn by ordinary abrasion. The V-shaped cut in the root of the tooth was made with a file for the examination of the pulp canal.

In all my examinations of erosion I have never seen a metallic filling that seemed to have been cut away by erosion. Years ago I made much trial of gold fillings with a view of arresting erosion, and generally found the erosion progressing beside the filling as though no filling had been placed. The margins of the fillings stood up sharp and definite, showing no rounding. Dr. W. D. Miller, in his recent articles on erosion, claimed to have seen fillings of various sorts cut away by this process. Recently I have met with a case which is presented in Figure 61, in which a gold crown, which had been placed over the first bicuspid, seems to have been cut through. The patient is a dentist, and he tells me that this is the third gold crown that has been cut through at the same point. It was placed over the tooth because it had become quite deeply eroded and was extremely sensitive. The second bicuspid below also is a gold crown, placed for a similar reason. It has shown no signs of injury. It will be

noted that erosion is in progress in other teeth in the neighborhood.

In Figure 62 is presented an illustration of a case of erosion of proximal surfaces observed a number of years ago. The picture is reproduced from pencil sketches made during the progress of the case. I had the privilege of observing the progress of this over a period of about seven years, nothing being done or attempted in the way of treatment. The picture represents the case as I first observed it. It appeared as if holes had been bored between the teeth, cutting about equally from either tooth. These grew larger and larger and the interproximal gum tissue receded slightly until the teeth were cut away so much that they broke, leaving the roots in position. During all of this time, the margins of the cut at their junction with the enamel surface were sharp, presenting no observable rounding. I have observed this in the molars and bicuspids in several cases, and usually the teeth have been extremely sensitive. One gentleman had all of his molars removed from the upper jaw bcause of the pain they gave him in chewing food and in any effort to clean his teeth.

The selection of cases for illustration has been confined to a few which seem to represent the more typical varieties of form. Variations from these, however, are constantly coming up, almost every new case presenting characters peculiar to itself. Many of them, even when the teeth are badly cut and deformed, are so clean and white that the deformity is scarcely noticeable a few feet away. But occasionally we see cases that give a very bad appearance. A larger list of illustrations would present variations without giving essentially new forms. For instance, the case from which the irregular cutting of the incisors was taken for Figure 56 had wedge-shaped areas of erosion at the gingival of the bicuspids and molars in which the point of the wedge, and of course the flat side of the cut, sloped toward the occlusal instead of toward the gingival, as shown in Figure 50, which is the more common, and therefore the more typical of the wedge-shaped areas. Similar changes from anything that may be regarded as typical are continually occurring. These are curious, but further illustration would give no broader view of the general subject.

Whether or not these forms of erosion have any significance in connection with the causation, can at present be only a matter of speculation. In studying them it would seem that if some cases of erosion are caused by the brush carrying abrasive powders, certain of the forms may be due to that, while certain

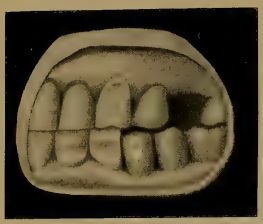

Fig. 61.

Fig. 62.

Fig. 61. Disk shapes. The lower bicuspids and first molar are gold shell crowns, which were placed because of the extreme sensitiveness of the eroded areas. The crown on the first bicuspid is the third shell crown which has been worn through by the erosion. The white cement may be seen through the hole in the crown. Man, forty years of age; a dentist.

Fig. 62. Proximal surface erosion. A case of a young man, about nineteen years of age. When first observed the teeth were in the condition presented in this illustration, showing round holes through between the teeth. These enlarged slowly, and the teeth broke away about seven years later.

other of the forms would seem to be impossible of production in that way. For the present there does not seem to be sufficient basis for any considerable discussion of this point.

Etiology of Erosion.

The cause of erosion is involved in the utmost obscurity. Most observers seem to have drawn their opinions of its causation from the observation of the circumstances attending a comparatively small number of cases coming under their personal observation. As the cases differ very materially in form of affected areas and surroundings, these views differ with the groups of cases observed. These opinions may be found in the literature reaching back some two hundred years. I may, perhaps, give a better and more condensed idea of this by grouping these opinions into classes, than by extensive quotations. I will follow in some degree the order in which they have been prominent in the literature. They may be thus summarized:

(1.) Erosion is a result of faults in the formation of the tissues during the growth of the teeth; conditions in after life have little or nothing to do with it.

(2.) Erosion is caused by friction, most generally of the tooth brush carrying some abrasive tooth powder.

(3.) Erosion is the result of the action of an acid in some way, as yet unknown to us.

(4.) Erosion is the direct result of the action of a secretion of certain diseased glands in the mucous membranes that lie directly upon the areas being eroded. This secretion is generally claimed to be acid in its reaction.

(5.) Erosion is a process of absorption similar to that of the removal of the roots of the deciduous teeth or the occasional absorption of the roots of the permanent teeth. The absorbing tissue is the diseased portion of mucous membrane found lying in the eroded areas.

(6.) Erosion is in some way the action of an acid, the development of which is associated with the gouty diathesis.

(7.) Erosion is effected by alkaline fluids acting upon the basic substance and setting the calcium salts free, which waste away with a polished surface.

(8.) While dental caries is the result of the action of an acid developed by microörganisms, erosion is effected by the enzyme of the same or similar microörganisms.

In discussing briefly the principal points in these views, we will find some overlapping more or less with each other, or

separated only by the introduction of certain factors supposed important by one party, but not considered so by another.

THE FIRST SUPPOSITION mentioned seems to have been the older view. It was clearly expressed by John Hunter in 1778, by Fox in 1806, by Bell in 1825, and by a number of others following these, and finally by Garretson as late as 1890.

Hunter supposes that erosion is due to some certain imperfection in the formation of the tissues of the tooth, because of which the substance gradually wastes away, continually leaving a smooth surface. His supposition seems to have been that conditions in after life had nothing especially to do in the matter.

Fox and Bell do not differ materially from this view, but Bell adds the supposition that in the case of the dish-shaped areas of erosion, the tissues of the tooth have been deposited in whorls or such forms as favored this kind of wasting. To-day such views seem very strange; but we should remember that when these men wrote nothing was known of the histology of the teeth, and their view did no violence to facts known in their time. We now know that such faults in the formation of the tissues do not occur as the basis of these cases.

THE SECOND SUPPOSITION, i. e., that erosion is caused by friction, and generally by the tooth brush loaded with abrasive powders, was held by John Tomes and many others in England, America and Germany, and is still held by many observers. According to this view erosion is no disease at all, but is purely a mechanical injury. Conditions present in quite a number of the cases seen, if grouped together and considered alone, would give strong support to this view. These cases nearly all belong to the more indefinite shapes of the wedge-like forms, and the cases which occur in the cementum after, or with, recession of the gum. A number of persons who hold this view describe and illustrate these forms only. This has led me to suspect that in some regions, particular forms are more frequently met than others. It seems certain that in the central part of the United States one would not observe many cases of the wedge-shaped areas without finding varieties of form that would be very difficult to explain as resulting from abrasion by the tooth brush. When Charles Tomes edited another edition of his father's work, he had seen cases that he believed could not have been made with the tooth brush, and he rewrote the chapter entire. Dr. C. R. E. Koch *(Dental Cosmos,* Volume 15, 1873, page 463) tried by every device he could think of to produce the conditions seen in erosion by the use of brushes and brush wheels, aided by acids in some

cases and by alkalies in others. His conclusion was that it could not be done in any of these ways. He did not have the modern electric motor to run his brushes, however.

Dr. W. D. Miller, of Berlin, Germany, recently published *(Dental Cosmos* of January and February, 1907) the results of two years' work on the etiology of erosion. He announced his belief that it is caused by weak acids or gritty tooth powders, or by both, assisted by the tooth brush. He seemed to be convinced that the tooth brush is the main factor, and that what we have designated as erosion is nothing more nor less than abrasion brought about by these agencies.

During several weeks that the author was in Berlin during the summer of 1906, he was frequently in Dr. Miller's laboratory while he was engaged in these studies. Through his kindness much was seen of his plans of work in the effort to produce erosion by artificial means. Having placed a number of teeth in wax, gutta percha, or similar substance, somewhat in the form they would be in the mouth, he saturated a cloth with a weak acid solution (different solutions being used in various experiments) and laid it lightly over the teeth so that it would touch only on the most prominent part of their crowns. After this had remained in a moist chamber, intended to prevent too much evaporation, for a predetermined length of time, the cloth was removed and the preparation placed on a machine run by an electric motor, and the teeth were vigorously brushed for a given number of minutes or hours, as determined for the particular case. The cloth was then resaturated with the acid solution, placed again upon the teeth, and the preparation returned to the moist chamber for the predetermined number of hours for that experiment. This was kept up day after day for weeks or for months, the experiments being much varied as to acid solutions, time, and brushing; also, certain experiments were being carried on without the acid solutions, and others by the use of tooth powders in use by the people. In some of the experiments the brushing was done by hand, as by this method more variety of motion could be used.

In these ways he had certainly produced results that looked very much like many cases of erosion as seen in the mouth, especially those of the partially dish-shaped, the wedge-shaped, and the flattened varieties. I saw none of his artificial production, however, that had the sharp, clean-cut margins so often present in the real thing as it occurs in the mouth. Yet I feel certain that if these specimens had been presented to me as

erosions that had occurred in the mouth in the ordinary way, I should not have questioned their genuineness. Certainly Dr. Miller has demonstrated the possibility and the probability that teeth are often injured by vigorous brushing with gritty powders, persisted in several times per day for many years together. I am not yet convinced, however, that all erosions are produced in this way, even admitting that they may be assisted in part by an acid that may be present in the fluids of the mouth.

One thing particularly Dr. Miller seems to have ignored, and that is the extreme sensitiveness that is so often present in cases of erosion. I know, however, that Dr. Miller had not finished his investigation of the subject at the time of his death, and that the peculiar sensitiveness occurring in erosion would have been considered by him later if he had had the opportunity. This I have regarded as peculiar to erosion, admitting, however, that cases occur in which there is no history of this symptom. It is my belief, based on the examination of many cases, that frequently sensitiveness is soon annulled by the rapid calcification of the pulps of the teeth. This has the effect of cutting off the connection of the dentinal fibrils of the crown of the tooth with the remaining pulp tissue. Then sensitiveness is ended. Therefore, many of the bad cases of erosion have not been sensitive for several years. This calcification has been a result of the condition of irritation communicated through the dentinal fibrils.

During the time of this irritable condition there is generally a history of the cessation of brushing, for the reason that the friction of the brush can not be borne. In the case illustrated in Figure 55, the young man said he had used a brush before his teeth became so sensitive, but most of the loss of substance had occurred afterward. This is but a repetition of the history I have had from many persons.

THE THIRD SUPPOSITION — that it is the action of an acid — has been held by many persons, and in one form or other probably has more adherents to-day than any other. How it is that an acid can so act to cut away the substance of the tooth, leaving a hard, polished surface which is a constant characteristic of erosion, while in all laboratory experiment and in caries as it occurs in the mouth the effect is a gradual softening by the solution of the calcium salts, is left unexplained, unless Dr. Miller's work noted above may be so regarded. As yet no acid has been found that will remove the whole of the tissue, calcium salts and basic substance, without previous softening.

I have made some experiments on a different plan (reported with illustrations in the "American System of Dentistry," Volume I, page 1003). Having noticed in some experimental work on the metals that the action of very dilute acids was different in the still condition as compared with the action in currents, I tried this upon teeth. Here I also found a difference. In a rapid current of a solution of one part of hydrochloric acid to four hundred parts of water, maintained for five days continuously, teeth were cut away in forms quite similar to erosion, the cut surfaces remaining hard and smooth while other portions of the teeth were not softened. I found the loss of substance to occur only where the current broke around the teeth in a certain way. While this experiment is impossible of comparison with anything that can occur in the human mouth, it demonstrates the possibility that the action of acid solutions may be modified in some degree by conditions under which they are placed. Thus far, however, no modification has been discovered that will in any degree account for effects like those seen in erosion under conditions that seem possible in the human mouth.

THE FOURTH SUPPOSITION — that erosion is caused by the secretion of certain glands in the mucous membrane of the lips and cheeks, that these glands become inflamed, or hypertrophied, from some unexplained cause, and emit an abnormal secretion which acts upon the teeth in this peculiar manner. It is certainly true in many of the dish-shaped eroded areas in incisors particularly, that a certain part of the mucous membrane is found to be raised in a form that fits into the excavations in the teeth. If we touch these with blue litmus, it is instantly reddened, showing the fluids in the region to be acid. Several have remarked that this was especially true when the test is made early in the morning, or when rising from bed.

I have personally examined many of these cases and have found the facts as stated. I have also found in these cases the *prints of teeth not eroded clearly outlined in the mucous membranes,* and these parts of the membrane showed also the same acidity when tested with litmus. After a careful and somewhat protracted study of these phenomena, my conclusion is that the little swellings on the mucous membranes are caused by the erosion, rather than the erosion by a secretion which they emit. In a considerable number of persons we will find prints of the teeth — the upper incisors particularly, and sometimes the bicuspids and molars also — in the lips or buccal membranes, and these are formed in the same manner.

This explanation is strongly emphasized by the fact that erosions occur in cases in which the mucous membranes never touch the teeth, as in the somewhat rare cases of erosion of proximal surfaces, and in one case coming under my observation in a girl sixteen years old, in which the bicuspids were deeply eroded in dish-shaped forms, where the tissues of the cheek had been destroyed before the teeth came through the gums, so that no mucous membrane could have touched them.

THE FIFTH SUPPOSITION has certain points of similarity with the fourth in that the same raised points of the mucous membrane are described as fitting into the eroded areas. But instead of the erosion being caused by an acid, the supposition is that this tissue acts as an absorbing organ, and that the result is really an absorption similar to that by which the roots of the teeth are cut away. Several writers speak of having seen the usual lacunæ of absorbed areas in roots of teeth and in areas of bone undergoing absorption, in these eroded areas. This supposition necessarily carries with it the idea that certain actively functioning cells become fixed against the tooth tissue and keep that position long enough or steadily enough to effect this result. The same objection to this theory applies as to the previous one, namely, that cases of erosion occur in positions in which no mucous membrane, or other tissue, is in contact with the areas being eroded. Also the supposition that the normal mucous membrane, or the mucous membranes in any probable pathological condition, would throw out or give rise to absorptive cells of such character as to act upon the teeth, seems untenable without further data than we yet have.

THE SIXTH SUPPOSITION is that it is caused by an acid that is developed in association with the gouty diathesis. This is a more recent supposition. Perhaps the most notable article upon this supposition is that by Dr. Darby, of Philadelphia *(Dental Cosmos,* Volume 34, 1892, page 629). Dr. E. C. Kirk, of the same city, has expressed somewhat similar views. This supposition has rapidly attained pretty wide credence. On this point my own observation, so far as it goes, would be negative. Very little gout has come under my observation (it would seem that the people of the Mississippi Valley are too restless a set of individuals to have time for gout) and the few well-marked cases that I have had opportunity to study have shown no erosion. It seems, however, that the tendency in recent years to attribute all kinds of ills not otherwise explainable, to the gouty or rheumatic dyscrasia, has been carried rather too far. Yet we must

now expect that the cause of erosion will eventually be found to depend upon some change in the body fluids giving oral secretions favoring these results; but how, by what, and how localized, are the questions. For the present it seems that we have no certain data in support of the theory connecting it with the gouty diathesis. So far as can now be determined from reports from other localities, it seems that erosion is as frequent here where gout does not prevail as elsewhere.

THE SEVENTH SUPPOSITION — that erosion is caused by alkaline fluids acting upon the basic substance of the tooth, setting the calcium salts free, which waste away leaving a polished surface — is one of the more recent. It has an individuality of its own. The supposition that an alkaline condition is maintained in these localities for any considerable part of the time as affecting litmus, is certainly contrary to my personal observations, and to much the larger number of recorded observations in the literature. Further, in Dr. Koch's experimental work mentioned above, he found that he could not dissolve either enamel or dentin in alkalies until the calcium salts had been removed, or partially removed by acids. The enamel particularly contains so little organic matter that it would seem impossible — first, that its organic matter could be removed in that way, and second, that if it could be accomplished it would not effect the disintegration of the tissue. The dentin has a much larger proportion of organic matter, but direct experiment seems to show that it has sufficient calcium salts to protect its organic matter from solution by alkalies. Therefore, until it can be shown experimentally that in some possible form alkalies will act to disintegrate these tissues, this supposition must be set aside.

THE EIGHTH SUPPOSITION, the most recent of all, is set forth by Preiswerk in his "Zahnheilkunde" ("Operative Dentistry"), 1903, page 200. It is the supposition that erosion is caused by the same or similar microörganisms as those which cause caries, but by the action of their enzyme, not by the action of their acid products. It is well known that a number of the microörganisms of the mouth which form acids in the presence of the carbohydrates, such as sugar or starch, will grow well in nutrient material devoid of these substances, but in that case will form no acid products. Preiswerk contends that the human saliva is normally alkaline, and that it is a mistake to suppose that the enzyme of these microörganisms is necessarily a peptonoid substance, as these act in an acid medium. He claims to have found

evidence that in alkaline or neutral conditions their enzyme is a trypsin similar to the trypsin of the pancreas which acts in the presence of an alkaline reaction. Under these conditions this enzyme acts upon the basic substance of the dental tissues, dissolving the basic substance, setting the calcium salts free, which are washed away during the chewing of food, the motions of the lips, fluids of the mouth, and in the artificial cleaning of the teeth. He claims to have in some degree proven this proposition by experiment with trypsin derived from the pancreas, which he found to act upon the basic substance of the teeth.

It seems quite possible that trypsin might act upon bone in this manner, possibly upon dentin, but that it should so act upon enamel, which has no more than three per cent of basic substance, seems out of the question. Erosion always begins in the enamel, except in those cases in which it begins in the cementum after the recession of the gum tissue, and practically always cuts the enamel as smoothly with the dentin as if the two were one and the same tissue.

In the absorption of the roots of the deciduous teeth, and not very rarely of the permanent teeth as well, all of the parts, basic substance and calcium salts, are cut away as one tissue. In the absorption of bone by the normal physiological process, the same thing occurs, and in my studies of these processes it has often been observed that the noncalcified bone corpuscles suffered the same fate. But even this process balks at enamel. I have often met with enamel in position to be acted upon by absorption, but this had failed. We often see almost the last trace of dentin removed from the crowns of deciduous teeth by physiological absorption, but never any part of the enamel. It appears at the present time that these facts place this process out of the question, even if the far more general observation — that the condition is acid in erosion — should be shown to be an error.

Finally, I can not at present find any theory proposed, nor have I any to propose, that has not features that seem to render it impossible. I therefore feel compelled to leave the subject in this very unsatisfactory condition, hoping that an early solution of the difficulty may be discovered. It seems highly probable that this will be found connected with some systemic dyscrasia, but if so, the conditions leading to its strict localization will require explanation.

Treatment of Erosion.

At present no treatment with the view of cure or of stopping the progress of erosion, is known, that gives promise of success in any considerable variety of the cases. There should be strict inquiry as to the patient's habits of cleaning the teeth in every case, and the use of any tooth powders whatever prohibited. A sufficient use of clear water and the brush will, I believe, do no harm. In what I learned of Dr. Miller's work in the production of erosion it seemed to me that he was not very successful in producing erosion with the brush and water, even when much brushing was done with the electric motor. With the powders, however, the teeth were worn away. He also found sharp grit in many of the tooth powders in use. The brush used with water regularly and sufficiently, but with moderation, will certainly keep the teeth in good condition as to cleanliness. If many dentists will do this and report the results carefully as to the effect on the progress of the erosion, we will soon gain valuable clinical evidence as to the possible effect of the brush with and without abrasive powders. Those who have connected erosion with the gouty diathesis have made some effort for the relief of the general condition with the hope that the progress of the erosion might be controlled, but thus far no very considerable benefits have been reported.

I have made considerable effort to reduce the evil results by inserting fillings, but can report but few successes, and am now of the opinion that some of these apparent successes were due to a coincident spontaneous stoppage of progress of the erosion, rather than from the influence of the fillings. In the case illustrated in Figure 48, I filled all of the eroded areas with gold, removing all that remained of the labial and buccal surfaces. This was effective for the teeth so treated, and fortunately the erosion did not spread to other teeth. I saw the case occasionally until the patient died, about fifteen years later. This was done before the modern process of porcelain crowns had become successful. The treatment was simply horrible from the esthetic standpoint, but it gave the patient the full use of her teeth with perfect comfort for the remainder of her life.

In my efforts filling has been of no other value except to limit sensitiveness and depth of cutting, unless all of the surface being eroded was removed, except possibly in some of the narrow cross cuttings and a few of the wedge-shaped areas. The

erosion will go on beside the fillings and continue spreading, leaving the margins of the fillings standing as they were placed.

One who has had a wide observation of erosion and of its progress from year to year may do much good by filling in certain selected cases. These should be those deep cuts across the teeth that show little or no disposition to lateral spreading. In a number of cases of this character I have cut the groove fully to the mesial and distal surfaces, and filled them with gold without other preparation. These have generally been successful. Early in my work I filled two of these without the extension mentioned. The erosion soon made the extension, and refilling became necessary. These include very few of the cases. The wedge-shaped forms have in a few instances done well with fillings, and certainly the depth of the cutting can be materially limited. Most of my efforts with these, however, have failed to stop the spreading. With the dish forms I have seen no success short of cutting away the remainder of the labial surface and replacing it. The artificial crown is the better treatment. In other forms of cutting, filling seems to be of no use except to limit the sensitiveness for a considerable time, and to prevent depth. The filling may be done with porcelain inlays when that seems desirable. In the great majority of cases, however, it will be better not to make fillings of any kind.

I am therefore of the opinion that, as a general rule, fillings should not be made in the treatment of erosion. That which now promises the best results is to keep watch of the cases, and at the proper time cut away the remaining parts of the crowns and place artificial crowns.

The sensitiveness when very annoying may be relieved, temporarily at least, by severe burnishing. The best way to do this is with the burnisher cut in ridges something like a coarse cut bur, with the edges rounded and polished. Some use has been made of these for burnishing fillings. Place the bur on the eroded and sensitive surface while rapidly rotating, and go over its surface quickly with strong pressure. Repeat this several times and then leave it alone. The first application will cause sharp pain momentarily, but afterward there will be less, or no pain. This will generally relieve the sensitiveness for some time. This may be repeated when necessary.

When erosion has progressed so far that the teeth have become much disfigured, the crowns should be cut away and porcelain crowns of some form substituted. These, if well made, will give excellent service.

In watching the progress of many cases of erosion a rather large number will be found that become stationary without known cause, and so remain indefinitely. These cases will, of course, vitiate many of the supposed good results of treatment by filling, or any form of treatment intended to limit or to stop the progress of erosion.

CARIES OF THE TEETH.

Historical.

MORE or less vague writings of caries of the teeth are found in ancient literature, most of which are too uncertain in their meaning for us to gain any clear conception of the views held of its cause. Other writings of the specialties in medicine, such as the mention of physicians for the teeth, extraction of teeth and of artificial teeth are not of interest in this connection. Close studies of the conditions surrounding the beginning and progress of dental caries have developed very slowly. The oldest writing that I know which attempts a rational presentation of the cause of dental caries is by an anonymous author in the German language in 1530. I present here a photographic reproduction of a single paragraph.

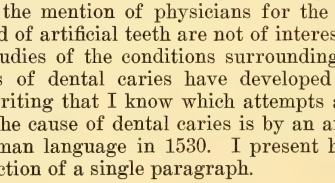

Corroſio iſt eine kranckheit vnd vehel der zen wenn ſie löcherigk vnd hol werdē welchs am meiſten den backzenē geſchicht vornemicklichen ſo einer iſt vnnd ſie nicht von der anhangēde ſpeiſe reiniget/welchs faul wirdt/ vnd macht darnach böſe ſchs arffe feuchtigkeit die ſie aus friſt vñ ezet/ vnd ymmer all melich vberhant nymmet baſs ſie auch gantz vnd gar die zen verder bet / vnnd darnach nicht ane ſchmerzen müſſen ſtückicht wegk faulen.

The statement is remarkable for its close agreement in substance to the views now held, if stated without detail. The wording is very quaint and in some unessential points the meaning is uncertain. I should translate it thus:

Translation. Caries is a disease and evil of the teeth in which they become full of holes and hollow, which most often affects the back teeth; especially so when they are not cleaned of clinging particles of food which decompose, producing an acid

moisture (literally, a sharp moisture) which eats them away and destroys them so that finally with much pain they rot away little by little.

In the same volume this writer gives also the oldest authentic mention of the use of gold for filling teeth. The paragraph runs thus:

Zum dritten das mân die ausholung wegk nummet/welchs auch auf zweyerley weyſe geſchicht/ Zum erſten das man das loch vnd die auſsfreſſunge mit einem ſubtilen meiſſelchen ader meſſerchen welchē/ ader mit einem andern inſtrument darzu bequemicklich/wegk ſchabe/vnd reinige/ als dy practickanten wol wiſſen/vnd darzu erhaldung des andern teyles des zanes das kōchlichen mit golt blettern zu fullet. Zum andern das mann gebrauche ertzney darzu dinlich welchs geſchiet mit Galles epffel vnd wilder galgen ſo der zan nach der reinigung darmit wirdt gefüllet.

The following is very nearly its meaning. The writer is discussing plans of treatment of caries.

Translation. In the third plan, the hollow place is done away with (taken away — removed) which is done in one of two ways. First, the soft part of the cavity and the decayed part is cut away with small chisels, knives, files or other suitable instruments, and cleaned, as is well known to practitioners. Then for the saving of the remaining parts of the tooth, the cavity is filled with gold leaf. Otherwise one may use a suitable gum prepared with nutgalls and hyssop to fill the cavity after cleaning it.

This writer mentions Mesu as an authority, a man who lived some two hundred years earlier, who is also mentioned by other writers, but so far as is now known, none of his writings have been preserved.

The French writings in dentistry are older that the English, but do not contain very clear statements of view of the pathology of caries. Generally the statements are equivalent to saying the teeth rot away or decay away, without attempt of explanation of the process.

Fouchard wrote in French in 1728 and a translation was made into German by Augustine Duddei in 1733. Second and third editions were published in French in 1746 and 1786. In none of these is there any statement regarding the cause of dental caries that is as definite in conception as the one quoted above. This seems to be true of all of the writings of that time. Fouchard mentions filling carious cavities with gold, but condemns the practice apparently because of the expense, and because certain persons of evil disposition deceived the people by using tin so prepared as to appear like gold. As filling materials, he preferred lead or tin leaf (foil).

John Hunter, writing in English (1778), expresses very clearly a different view, in which he says: "The most common disease to which the teeth are exposed is such a decay as would appear to deserve the name of mortification," with which he expresses some dissatisfaction as being an incomplete explanation of the diseased process. This, with other writings by the same author, shows that in considering the diseases of the teeth he was following closely the lines of thought of his time of what we now know as necrosis of bones.

Fox (1806) expresses a similar view, which, with slight modification, was repeated by Bell (1825), who proposed the term "dental gangrene" to take the place of the more common terms "decay" or "caries."

This seems to have been the most common view of medical men of that time, and, with slight modifications, was repeated by most writers. All of these men regarded caries of the teeth as being a result of inflammation and as beginning within the dentin instead of upon the surface of the enamel. Köeker of Philadelphia (1830) speaks of decay penetrating the enamel from within outward, saying that it "had thus formed a natural outlet for the bony abscess."

Robertson (1835) expresses a different view, which, in its main features, agrees substantially with the earlier views of the anonymous author quoted above. But Robertson is more explicit in the detail. According to this view, caries of the teeth resulted from the action of an acid generated by the decomposition of food particles or fluids, which lodged at particular points about the teeth and dissolved out the calcium salts of which the teeth are composed. These points of lodgment were shown to be the points at which caries made its beginning, as in pits and deep grooves in the occlusal surfaces, between the teeth (proximal surfaces) or about the margins of the gums.

Regnard of Paris (1838) defined caries of the teeth as "destruction of the teeth by decomposition." His contention was that this destruction took place at the very spot where the acid was formed, or where the alimentary particles lodged and decomposed.

This was called the chemical theory of caries of the teeth. A large body of dentists, both in Europe and America, gave similar expressions of view at about this time. The idea that inflammation of the dentin had any part in its causation was denied. Also the statements of Fox, Bell, and many others, that caries began within the dentin and worked its way outward, were generally denied. Instead, it was asserted that caries always began upon the surface of the tooth, or in pits, fissures, etc., that were open to the surface. The contentions along these differences of thought were sharp and the lines closely drawn. This brought about a much closer observation and study of the nature and form of the physical injuries inflicted by dental caries, and with this, the opinion became general that caries always began on the outside of the tooth and worked its way inward, forming a cavity. During this period also, comparative anatomists and geologists were studying closely the teeth of the living animals and those remaining of extinct animals, in which prominent differences between the structure of the teeth and the bones were ascertained. Owen gave us the word "dentin," distinguishing that which had before been called tooth bone from true bone.

A knowledge of histology began to be developed. The cell theory of the construction of organic bodies, animal and vegetable, was propounded and rapidly assumed the general form in which it stands at the present time. Makers of microscope lenses rapidly improved them because of the encouragement and patronage induced by these studies. In the midst of this, John Tomes, of London, was studying the microscopic structure — the histology — of the teeth and bones, and by 1860 this was developed almost completely as it stands to-day. It is true that since then much more exactness of method and greater accuracy of detail has been added. But the full foundation of our knowledge of dental histology and the development of the teeth was laid by John Tomes.

It seems that Mr. Tomes began this work with the inflammatory theory of caries strongly fixed in his mind. He found, however, that inflammation could not take place in the teeth. The histological structure of the teeth was such that there was no provision for the circulation of blood in the dentin, neither

was there any provision for processes of repair of injuries. Yet the dentin was a vital tissue and it was the opinion of Mr. Tomes that this vitality must be destroyed before the part could be dissolved out by an acid, thus forming a cavity. He admitted, however, that the same agent — an acid — might do both. This gave rise to the chemico-vital theory of dental caries, which was much discussed from 1840 to 1880.

Finally Dr. Magitot of Paris (English translation, 1878) published the most extensive work that has been produced on this subject, detailing much experimentation in various ways in the endeavor to determine the exact cause of the disease. His conclusions were that caries of the teeth was produced purely by chemical substances developed in the mouth or introduced with food. This work seemed, for the time being, to establish the purely chemical theory of the production of dental caries.

In the meantime, there had been many suggestions that microörganisms might be found to play a prominent part in the production of dental caries. The first important work published on this subject was by Leber and Rottenstein (German 1867 — English translation, 1868) in which these authors claimed to have determined the presence of these fungi in the dentinal tubules (which were much enlarged) of carious areas. Strong corroborative evidence of the correctness of their view existed in the fact that John Tomes had determined previously that the tubules in carious areas were constantly much enlarged and filled with granules, the nature of which he could not determine. This observation by Mr. Tomes had been confirmed by the observation of others and had become fixed as an essential difference between dental caries and a simple solution of the calcium salts of a tooth by an acid. Still, the work of Leber and Rottenstein made no considerable impression on the opinions held by dentists. These gentlemen wrote before the development of the staining methods by anilin dyes, which certainly distinguish microörganisms in tissues. Neither were they able, by means of culture methods then known, to separate microörganisms into distinct species and determine the character of each as to its power of producing fermentation or other special forms of decomposition.

Miles and Underwood of London (1881) determined definitely that the enlarged tubules in dental caries contained microorganisms, by use of the anilin dyes discovered by Dr. Koch, the German bacteriologist, but they were unable to go farther for the lack of better facilities for division of species of micro-

organisms and the determination of their physiological characters in the production of fermentations or putrefactions.

Dr. W. D. Miller was at work with Dr. Koch in his bacteriological laboratory when the means of cultivating microörganisms on semi-solid media was first established and was at once able to separate the microörganisms found in the mouth or in carious dentin into species, and determine the character of each in the production of acid fermentation or other forms of decomposition. The finding in the dentinal tubules of microörganisms which, when growing in artificial culture in the presence of any form of sugar or starch, uniformly produced lactic acid, which in time dissolved the calcium salts of the tooth tissue, completed the full explanation of the local changes taking place in caries of dentin, but the cause and the nature of caries of enamel was not so clearly made out.

This history, briefly as it is written here, shows the principal steps of the unfolding of a knowledge of this disease process extending through many years of labor done by many individuals, each building upon the discoveries which were made by his predecessors. The outcome of this work has finally given complete and exact knowledge of the steps in caries of dentin. It will also be seen that the work of Dr. Miller was really the finding of the exact method of the formation of the acids which the older anonymous German writer (1530), Robertson (1835), Regnard (1838), and others, described as being formed by decomposition. This brief summary mentions the work of but a few of the men who seem to have been most fortunate in the finding and giving expression to facts that have advanced our knowledge of the processes taking place in caries of the teeth. As a matter of fact, many men have taken part in this work.

General Statement.

Caries in its simplest expression consists in a chemical dissolution of the calcium salts of the tooth by lactic acid, followed by the decomposition of the organic matrix, or gelatinous body, which, in the dentin, is left after the solution of the calcium salts. In caries of the enamel, the whole substance of the tissue is removed by dissolving out the calcium salts, there being so little organic matrix in the enamel that it will not hang together; consequently a cavity is formed by the simple solution of the calcium salts of which it is composed. This solution always begins upon the surface, never in the interior. Decay of the teeth is therefore caused by an agent acting from without the

tooth, never from within the tooth. It is something extraneous to the tooth, acting upon the surface in the beginning and penetrating little by little into its substance.

Caries of the dentin is different from caries of the enamel, in that the organic matrix is sufficient in amount and consistence to retain its histological and physical forms after the solution and removal of the calcium salts. With the removal of these by an acid, the enamel will have disappeared entirely, but the dentin will not suffer any change of form. Therefore, the simple solution of the calcium salts leaves a softened matrix in the dentin and does not form a cavity. After the solution of the calcium salts, there is a decomposition of this organic matrix progressing from without inward, breaking it up and finally forming a cavity. Between the solution of the calcium salts and the decomposition of the organic matrix, some little time passes. The two seem never to occur at the same time in any given portion of the tooth, but the calcium salts are dissolved out first and the decomposition of the organic matrix follows later. Therefore, while, after the full development of the carious process, both may be progressing at the same time, the solution of the calcium salts is always considerably in advance of the decomposition of the organic matrix, leaving a zone of softened material between.

In the progress of the solution of the calcium salts of the dentin, the tendency is to spread in every direction from the point of penetration of the enamel, and especially along the dento-enamel junction. Then, particularly when the original opening in the enamel has been small, the enlargement of the opening is brought about mostly by what is termed "backward decay of the enamel." This is decay of the inner surface of the enamel that is in contact with the decaying dentin under it, due to the spreading just mentioned. In this case the enamel decays from the inside outward until it is so weakened that it breaks away, enlarging the opening. The rapidity of this backward decay of the enamel is exceedingly variable. Cavities may be wide open early in their progress, or they may remain for a considerable time with a small opening.

The calcium salts are not dissolved complete from without inward in the first instance, but the acid which dissolves them seems to spread, or percolate, into the tissue and the solution goes on as a gradual softening process. The innermost part affected is less softened than the more superficial parts. In the outer portion of the softening area all, or about all, of the cal-

cium salts have been dissolved, while in the inner portion but very little is yet dissolved. In this way the action of the acid progresses slowly from without inward.

The decomposition of the organic matrix of the dentin progresses in a similar way, the tissue being broken up little by little progressively, from without inward, so that the formation of a cavity, especially when the opening through the enamel is small, follows slowly the solution of the calcium salts. Therefore, it often happens that the solution of the calcium salts has progressed much more rapidly than the decomposition of the organic matrix. In that case, we find a very large amount of material that is soft and spongy, which may be easily cut with a sharp excavator; or, after removing any overlapping enamel that may interfere, a spoon excavator may be passed along the margin of the decayed area, and the whole of it may be turned out in a body, soft enough to be cut with a razor or sharp knife. Occasionally we will see almost the entire interior of the enamel cap, i. e., almost the entire dentin of the crown of the tooth, softened in this way and yet the organic matrix is not yet broken up. This, however, is the exception to the rule. The general rule is that the decomposition of the organic matrix follows fairly closely the removal of the calcium salts.

CARIES OF DENTIN.

ILLUSTRATIONS: FIGURES 63-74.

Although in the natural order of the phenomena, caries of enamel always precedes caries of dentin, it is preferred to first describe caries of dentin for the reason that the order and character of the processes in its progress are regarded as having been completely made out, and it is believed that afterward caries of enamel will be easier understood. It is sufficient here to say that caries of dentin can not occur until the enamel has been penetrated. The enamel with its rods cemented together by its cementing substance is a solid. It has no natural openings into which microörganisms can grow; and these have no power of penetrating into it, except as it is dissolved and removed by the acids which they form during their growth. Therefore, in decay of the enamel, the microörganisms producing the acid are on its surface. On the other hand, the dentin is everywhere permeated by the dentinal canals into which microorganisms may grow when the dentin is exposed by the destruction of the enamel.

Both caries of enamel and caries of dentin are caused by the same agency; namely, the growth of microörganisms in contact with the surface of the enamel in the first instance, and the formation of lactic acid during that growth, which dissolves the calcium salts of which it — the enamel — is composed. In caries of dentin, the microörganisms grow into the dentinal tubules and form their acid product within the tissue itself. This dissolves the calcium salts of the dentin, converting it into the soluble salt, calcium lactate, which gradually escapes into the surrounding saliva by osmosis.

Osmosis. The word osmosis, as used here, is used in physical chemistry to represent the passage of soluble salts through animal membranes. This occurs whenever a fluid containing the specified salt is in contact with the membrane upon the one side and water is in contact with the same membrane upon the other side. In this case, the salt will pass through the membrane into the water until the water on either side of the membrane becomes equally salt. Or again, if two salts, which will commingle in solution without chemical reaction, are placed in solution in water separately, and the one placed in contact with one side of a membrane and the other in contact with the other side of the



FIG. 63.

FIG. 64.

FIGS. 63, 64. Photographs, very nearly full size, of a small dialyzer used for separating the salts from the saliva, or other body fluids, for the microscopic study of the crystals. With this, it is the intention to deal with very small volumes. In Figure 63 the parts of the piece of apparatus are in position. In Figure 64 the lid with the tube passing through it is removed and laid to one side. The tube passing through the lid has a small rubber band around it above the lid, which may be moved to hold the tube at any height above the bottom of the vessel. The lower end of the tube is closed with a piece of gold-beaters' skin stretched over it and tied with a thread. This may have a coating of collodion to close any possible opening. A piece of fresh bladder could be used as well. In use, the saliva or other body fluid is placed in the dish and about two cubic centimeters of distilled water are placed in the tube and the height of the tube adjusted so that the surface of the water in it will be about level with the top of the fluid in the dish.

Fig. 65.

Fig. 66.

Fig. 65. A photomicrograph of salts dialyzed from the saliva and crystallized on a cover glass. Only a minute drop of fluid was used.

Fig. 66. Crystals of sugar. A photomicrograph with polarized light.

Fig. 67.

Fig. 68.

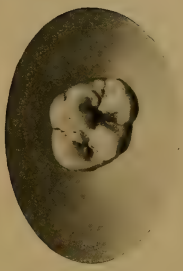

Fig. 69.

Fig. 70.

Fig. 67. A bicuspid split mesio-distally through an area of decay and photographed before separating the halves. When these are opened like a book, the penetration of the decay will be disclosed. These cuts have been made for the illustrations in an especially arranged lathe, in which the tooth is mounted on a slide rest. The cutting is done with a rapidly revolving aluminum disk, twenty-six gauge (thirty-two gauge may be used) charged with carborundum powder mixed with soapy water. With this, slices 1-100 of an inch thick may be cut.

Fig. 68. The occlusal surface of an upper first molar with a decay in the central pit. This tooth was split mesio-distally and is shown in Figure 71.

Figs. 69, 70. Other upper first molars showing, apparently, similar decays.

Fig. 71.



Fig. 72.

Fig. 71. The upper first molar, Figure 68, split mesio-distally, the surfaces polished, laid open and photographed to show the penetration of decay. The specimen shows particularly well the typical conical form of the penetration of dentin as it occurs when the opening in the enamel remains small. It also shows well the spreading of decay along the dento-enamel junction of the occlusal surface forming the broad base of the cone of the area of decay.

Fig. 72. A lower second molar with a large area of decay which has begun in the buccal pit. The decay has spread along the dento-enamel junction, undermining the greater part of the enamel of the buccal half of the tooth and has destroyed nearly one-half of the dentin. This injury has occurred while the opening into the cavity has remained small.

same membrane, the two salts will pass through the membrane in opposite directions until they have become equalized in the two solutions. This process, when used to separate crystallizable salts from colloid substances with which they may be commingled, is known as dialysis, for it is found that such substances as gums, resins, albumens, etc., which are not crystallizable, do not readily pass through membranes in this way. Therefore, if there is a solution of sugar in the saliva and a solution of calcium lactate in the depths of a carious cavity, that part of the matrix of the dentin which is already softened by the solution of its calcium salts, acts as a dialyzing membrane, passing the sugar in and calcium lactate out. In this way, the growing microörganisms receive sugar from the saliva, and lactic acid (their waste product) which has become calcium lactate by combination with the calcium salts of the tooth, is eliminated. This process naturally goes on very slowly, so that weeks and months are required for any considerable cavity to form, and often several years. Figures 63 and 64 represent a dialyzer used to obtain salts from the secretions free from the gummy substances with which they are associated, for microscopic examination of their crystals. Figure 65 is a photomicrograph of the salts dialyzed from saliva and crystallized. Figure 66 is a photomicrograph, made by polarized light, of sugar dialyzed from a solution and crystallized.

In penetrating into dentin microörganisms follow the dentinal tubules, simply growing into them as a grapevine would grow through a lattice. The anastomosing loops from tubule to tubule, which are plentiful near the dento-enamel junction, and any other openings such as interglobular spaces which they may encounter, are filled full as they go. There is much difference found in different teeth in the number and size of the anastomosing loops from tubule to tubule. In some these are plentiful, in others very much limited. In all, however, there is a sufficient number of these near the dento-enamel junction to afford a moderately free passage of microörganisms from one tubule to another. In a considerable proportion of teeth there are many small interglobular spaces along next to the dento-enamel junction, known as the "granular layer of Tomes," through which microörganisms may readily grow. Therefore among different teeth there are differences in the facility with which microörganisms will spread along the dento-enamel junction. The organisms having gained access to the dentin by the solution of the enamel, they grow into the dentinal tubules

directly toward the pulp. They are continually gaining access to other tubules by spreading laterally along the dento-enamel junction in every direction from the first point of entrance. *Therefore, the tendency is to the formation of a conical area of decay with the point of the cone toward the pulp of the tooth and its base against the dento-enamel junction.* The breadth of the cavity thus formed, in relation to its depth, will naturally depend upon the comparative rapidity with which the organisms may spread laterally along the dento-enamel junction. For this reason some cavities are broad and some are very narrow as compared to their depth.

In the illustrations of this subject many "split teeth" will be used. In these the teeth are cut through the decayed area as shown in Figure 67. The cut surfaces are polished and the parts laid open like a book and photographed as opaque objects. The half-tone engravings are made from the photographs without any retouching whatever. In many cases only one of the halves has been used.

The form taken by decay in dentin when it has begun in an occlusal surface is well shown in Figure 71, a photograph from a first molar split in half mesio-distally through the central pit, in which the decay began. The occlusal surface of the tooth before cutting is shown in Figure 68. Other photographs of molars showing decays which, to superficial observation, seem to be similar, are shown in Figures 69 and 70. In Figure 71 the wide spreading of caries along the dento-enamel junction forming the base of the cone, and the point of the cone reaching to the pulp chamber are well shown. This is the most common form. In this case, as in most cases of split teeth displaying caries, the cut surface is photographed as an opaque object. In examining such illustrations, it must be remembered that a section through a cone gives a triangular figure.

Figure 72, a lower second molar that has been cut bucco-lingually, shows a decay that has begun in the buccal pit. This decay has proceeded very slowly. There is the same wide burrowing along the dento-enamel junction related above, and the effect of the continued irritation during the slow progress of the decay is seen in the reduction of the size of the pulp chamber by the deposit of secondary dentin. This condition, resulting from long continued irritation of the dentinal fibrils, is a common effect. It occurs also in abrasion and erosion.

Careful observation has shown that microörganisms do not begin to grow into the dentinal tubules until the calcium salts



Fig. 73.



Fig. 74.

Fig. 73. An illustration showing the filling of the dentinal tubules with microörganisms. The dento-enamel junction is at the top of the illustration. The organisms have entered the tubules and by continued growth and multiplication have filled and enlarged them very evenly, having grown single file into all of the smaller side branches. Only a few slight local swellings of tubules are seen. The left of the illustration is near the margin of the invasion, where new tubules are as yet but partially filled. Great differences are found in different specimens in the number of smaller side branches. Some have very few after passing a little way from the dento-enamel junction.

Fig. 74. Another illustration of the filling of the dentinal tubules with microörganisms, in which, as compared with Figure 73, the opposite extreme as to side branches and irregular swellings of the tubules is shown. This figure represents something like a maximum of irregular swellings of tubules and with no side branches. This is taken from deeper in the tooth close on the deeper margin of the invasion. The two specimens were from different teeth, and have been selected as representing the extremes of smoothness of the filling and enlargement of the tubules and maximum of filled side branches, as seen in Figure 73; and absence of filled side branches and something near the maximum of irregular swellings of tubules, as seen in Figure 74. All gradations between these two illustrations are found.

have been dissolved out for some little distance in advance of them. In the natural order of the advance of decay this is accomplished in the beginning by the percolation of acid through the enamel before the enamel rods have fallen away, so as to admit microörganisms to the dentin. This will be more clearly shown in considering caries of the enamel. Therefore, when they are admitted to the dentin, some portion of it has been softened and the organisms begin growing into the tubules at once. As they do so the acid which they are forming percolates into the dentin in advance, dissolving more and more of the calcium salts. In this way it happens that the dentin is continually softened in advance of the growing organisms so that there is a little space softened around them that contains none of the fungi. By removing all overlapping enamel carefully to give good opportunity, a thin, sharp spoon excavator may be passed closely along the hard dentin at the margin of the softened area and the decayed portion turned out, removing with it practically every microörganism in the dentin.

As the microörganisms fill the dentinal tubules, the tendency is to become more and more crowded together and the tubules begin to be enlarged. In some cases this enlargement is a very regular increase in size along the length of the tubules, the outer ends of which are enlarged most, as shown in Figure 73. In other cases there is much tendency to irregular swellings of the tubules, as shown in Figure 74. Indeed, these two illustrations have been chosen as showing the extremes of regularity and of irregularity in this respect. Every variation between the two may be found. Also the number of side branches into which organisms may grow varies indefinitely; after passing a little way from the dento-enamel junction some cases show very few or even none at all, while in others they are very plentiful.

This enlargement of the dentinal tubules continues until the division walls disappear, uniting two in one, three into one, and so on until there is nothing left but a mass of microörganisms mingled with some undissolved shreds of organic matrix, which, if the cavity is exposed to the saliva, wastes out and is washed away. This enlargement of the tubules and destruction of the organic matrix is accomplished by the enzyme of the organisms. It is digested. Dr. Miller, in his examination of this point, decalcified teeth, cut them into slices, completely removed the acid by which the decalcification was done, and planted the fungus upon these as culture media. He found that they make a good growth without other nutrient material.

Within my personal observation, caries of dentin has seemed to progress most rapidly when closely shut in by overlapping enamel, and less rapidly when the opening to the fluids of the mouth was broad and ample. Finally, when the carious area is so flat as to be kept clean by mastication and is fully exposed to washings by the saliva, the decay ceases. The fungus is facultative anaërobic, growing ordinarily in the presence of oxygen, but having the faculty of growing quite as well in the absence of oxygen. It grows well in culture media when all oxygen is removed, and therefore grows as well when shut up in a deep cavity. In case the opening of the cavity becomes very broad while the cavity is yet shallow, the progress of decay is apt to be much slower. The explanation for this difference is that when the opening to the cavity is very broad, much of the acid formed by the microörganisms is washed away by the saliva. This must be considered a local factor. The intensity of the condition of susceptibility, which will be discussed later, must also be reckoned with as a general factor when considering the rapidity of caries.

The progress of caries is limited, or even stopped, in a number of different ways. The crowding of meats into a cavity and the establishment of putrefactive decomposition, an occasional occurrence, is apt to end the progress of decay for the time, and leave the cavity with smooth, hard, blackened walls by the decomposition of all of the organic matrix from which the calcium salts have been removed. Decay may rebegin in this if conditions are so changed as to favor it.

When most of the crown of a tooth breaks away, the progress of caries will necessarily be across the length of the dentinal tubules, because these become horizontal on a level with the pulp of the tooth. If the organisms are prevented from entering the tubules from the pulp canals, the progress of decay will be very slow, or there will be no progress at all.

When the pulp of the tooth has died and alveolar abscess in the chronic form is established with a free discharge through the root canals, the progress of decay is generally stopped as long as this condition continues. If, however, the apical portion of the root canal is choked by debris or otherwise closed, decay may proceed from the root canal, penetrate the tubules and rapidly hollow out the root to a conical shell and destroy it.

The breaking away of the lingual or buccal wall of proximal cavities is often a factor in saving a tooth from destruction, especially among those people who live much on coarse food.

This has been found in the examination of some of the older Indian remains, especially of those tribes that were supposed to eat much parched corn. The food forced through the cavity in mastication and out through the broken side kept the surface worn smooth. The opportunity to know and to watch this among our own people occurs frequently.

The question as to whether caries is produced by a single species of microörganism or whether a number of kinds are acting together is often asked. As to this, there are several organisms found in the saliva of practically every person that have physiological characters which seem to fit them for the production of caries, and no reason is known why they may not be acting together in the same carious cavity. Dr. Miller seems to have found them so. In the deepest portion of the carious area I have usually found but a single variety, the streptococcus. In the decaying mass, however, pretty much all of the varieties found growing in the mouth may be found and some of them penetrate deeply into the softened portion. Especially a white staphylococcus is often found deep in the dentinal tubules, if judged of by the difficulty of keeping clear of it in the effort to get a pure culture of the streptococcus from carious dentin.

NOTE.— I have often spoken of this staphylococcus as the zigzag coccus, because of its habit of forming zigzags in its growth in broth. One coccus of a pair divides on the opposite pole from that upon which the pair has divided, making a square turn instead of a straight or curved line, as is the more usual habit of the streptococci. This organism dissolves gelatin freely in artificial culture. It is frequently found in suppurating pulps in alveolar abscess, yet it will generally fail to produce pus when animals are infected with it. It is probably the white staphylococcus pyogenes modified by continuous residence in the saliva. The streptococcus spoken of above I have often called "caries fungus," or "streptococcus media," the latter because of finding larger and smaller varieties occasionally in the saliva. These are hardly found so continuously as to make the latter term a good one.

CARIES OF ENAMEL.

ILLUSTRATIONS: FIGURES 75-98.

Caries of enamel differs from caries of dentin in several important particulars. (1.) In caries of enamel, the microörganisms are attached to or lie upon the outside of the enamel. They grow and form the acid which causes caries of enamel in that position. They never enter the tissue until the enamel rods are loosened and fall out. The enamel is a solid into which microorganisms can not penetrate. (2.) The enamel rods are cemented together by a cementing substance which dissolves more readily in an acid than the rods themselves, and the first effect upon the enamel is to dissolve out this cementing substance. The general rule is that in decays occurring on the smooth surfaces of the teeth, this cementing substance is dissolved through the entire thickness of the enamel before any enamel rods fall away. In some of the decays occurring in pits, the enamel rods themselves will be dissolved, enlarging the pit. (3.) The decaying spot upon the enamel is always whitened, as the first observable change. This change in color is sometimes not considerable and is very easily overlooked while the teeth are wet, but, when the teeth are dried and examined carefully, the color will be found to be a grayish white, or even very white in some cases, and the outlines are often very clearly marked. (4.) In such spots an explorer is likely to catch if passed lightly over the surface, instead of gliding smoothly as it will on sound enamel. (5.) For these decays to occur, it seems to be necessary that microörganisms become attached to the surface of the tooth, grow there in the form of a colony, or in a zoöglea formation, attached together in a gelatinoid matrix, or equivalent covering, and produce fermentative decomposition with acid formation at the spot, applying the acid directly to the solution of the tooth. (6.) For this reason, the beginning of caries of the teeth occurs at such points as will favor such lodgment or attachment in which the microorganisms will not be subject to such frequent dislodgment as would prevent a fairly continuous growth. This is the cause of the localization of the beginnings of caries on particular parts of the surface of the tooth. It had previously been supposed that caries of the enamel might be caused by acids dissolved in the saliva, or introduced with foods from the outside. This

idea, however, is no longer tenable. If caries of the enamel was caused by acids dissolved in the general saliva, we would not have that strict localization of decay that is found in the mouth. This localization is very important and should be very carefully considered.

THE POINTS OF LOCALIZATION ARE: (1.) Pits or fissures in the occlusal surfaces of the bicuspids and molars, in the buccal surfaces of the molars, and sometimes in the lingual surfaces also, and occasionally in the lingual surfaces of the upper incisors; (2) In the proximal surfaces of all of the teeth; (3) In the gingival third of the buccal or labial surfaces of all of the teeth, and rarely in the lingual surfaces also. Ninety-eight per cent of all of the decays that occur in the human teeth are located at the points included in this mention. Those beginnings of decay located elsewhere in the teeth are usually the result of accidental conditions, proving the accuracy of the rule; (4) The most prominent tendency to wide spreading of decay on the surface of the enamel is a direction that, when complete, encircles the tooth following close to the free margin of the gum. Hence proximal decays and gingival third decays spread most in these directions. The tendency in cases of unusual severity is for proximal and buccal, and even lingual decays, to unite across the angles of the teeth, making a complete circle around the tooth near the free border of the gum.

It may be laid down as a principle that *for caries to begin in the enamel of the teeth anywhere, the caries fungus, which forms an acid, must be attached to the surface of the enamel in some such way as to prevent the acid which it forms from being readily washed away and dissipated in the general fluids of the mouth.* Under all the observations of the surroundings of the occurrence of decay of the enamel, I fail to be able to form a conception of its beginning without the existence of some such conditions. But it is not insisted here that this must always be by the formation of zoöglea or gelatinoid plaques. This may be produced in an artificial way by cementing a band on a tooth, as is done in orthodontia operations, and omitting the cement in a part of the area covered. If such a band remains long on the tooth, caries of the enamel will occur, even when the patient is otherwise immune to caries. This has been a matter of careful experiment by the author. It has also been observed in many orthodontia cases. Indeed, the amount of injury being done in this way during the treatment of irregularities, is giving rise to much complaint.

Penetration of Enamel in Pits.

ILLUSTRATIONS: FIGURES 75, 76, 77.

The beginning of caries in pits in the occlusal surfaces of three molar teeth is shown in Figures 75, 76, 77. It is not difficult to conceive of a colony of the microörganisms present in the mouth, establishing itself within one of these pits and growing there, producing acid sufficient to begin the solution of the cementing substance between the enamel rods. These would be covered with debris from foods that is forced in upon them, very completely shielding the acid formed from being washed away by the saliva. It seems to be true that there is a greater intensity of the action of the acid in caries of enamel in this position than in any other, for elsewhere it is very rare to see the carious process extending across the length of enamel rods, or a complete solution of any of the rods before they are loosened from the dentin. Caries usually follows accurately the length of the enamel rods in the penetration of the enamel in all axial surface positions. But in beginning decays in pits, we occasionally see progress across the length of the enamel rods, and in Figure 77 particularly, less distinctly in Figure 76, we may note that the pit has been enlarged at its deeper part by the solution of the enamel rods about its walls. This kind of showing occurring frequently, indicates that the locality is more completely isolated, or less disturbed by solution of the acid in the oral secretions than elsewhere, and therefore reaches the highest percentage of acidulation. It seems to be for this reason that in this position the rods themselves are often dissolved even before the carious process has extended into the dentin. The spreading across the enamel rods is, however, often more apparent than real, for about pits the enamel rods are all inclined toward the pits. It will be noted also, in the examination of these illustrations, that there is no sign of the carious process on the surface of the enamel outside the pit. It is confined exclusively to the walls of the pits and usually to the deeper part. Occasionally pits that are gradually narrowed from surfaces much inclined, or in a funnel shape, will show caries extending a little out of the pit proper, but this is unusual. This absence of superficial extension is because the surfaces immediately about the pits are kept clean, or reasonably clean, in the process of mastication; and further, because, if microörganisms were growing in such a position, they would be subjected to continual

FIG. 75.

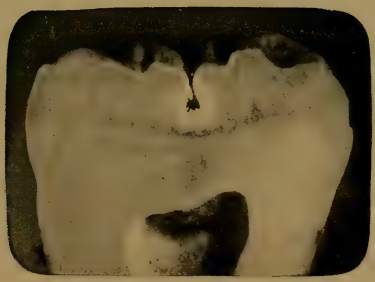

FIG. 76.

FIGS. 75, 76. Photographs from split teeth showing pit decays of occlusal surfaces. See below Figure 77 for descriptions of these illustrations.

Fig. 77.

Figs. 75, 76, 77. Photographs from split teeth showing progressively the beginning and progress of decay of the enamel in pits in the occlusal surfaces of molar teeth. Each illustration is from a different tooth. Figure 75 represents almost the earliest beginning of caries in the pit, shown by the whitening of the enamel of the walls of the pit, that can be distinctly recognized in a photograph. Figure 76 is a more distinctive showing of decay made by the deeper whitening of the enamel about the pit and the appearance of slight solution of its walls. In Figure 77 more decided advance has been made in the whitening of the enamel and loss of substance in the walls of the pit. The acid has, in this case, passed the dento-enamel junction and an effect in the dentin is seen. In this tooth there is also a smooth surface decay of the enamel beginning in the mesial surface, which has also been cut through centrally. This shows as a faintly whitened area, broad on the surface and penetrating deepest in its central part. Its form is characteristic of smooth surface beginnings of decay of the enamel, and is placed here in sharp contrast with the forms of beginning decay of enamel in pits.

Fig. 78.

Fig. 79.

Fig. 78. Caries of enamel. A white carious spot on the distal surface of a central incisor. It has very sharp and definite outlines, though not very regular.

Fig. 79. An incisor removed for a girl nine years of age, split through areas of decay and showing the broad pulp chamber of that age. A decay in the mesial surface had destroyed the pulp. In the distal surface there is an area of decay in the enamel, which, superficially, was similar to the one shown in Figure 78, but not so white. This is very typical of the form of these smooth surface decays of enamel in its conical shape, with the broad base of the cone on the surface of the enamel and the apex of the cone toward the dento-enamel junction. In this case the apex of the cone has just penetrated the enamel. A little solution of the lime salts of the dentin has begun by the percolation of acid from the surface through the thickness of the enamel. No enamel rods have fallen away and no microörganisms have been admitted. Notice that a delicate hyaline zone fringed with shade streaks away toward the pulp, following the direction of the dentinal tubules.

Fig. 80.

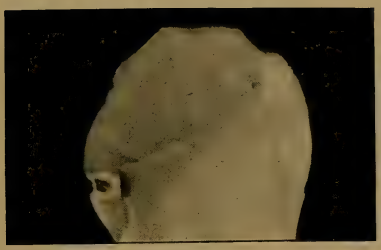

Fig. 81.

Fig. 80. A split lateral incisor, with a very white decay of enamel in its distal surface, showing a modification of the conical form of penetration. This has just penetrated the enamel, and the hyaline area, which may already be traced to the pulp chamber, is unusually dark for such a case. These areas of effect in the dentin beyond the area of actual decay vary greatly in light and shade. Photographs of these areas vary greatly, because of differences in the translucency of different teeth. A tooth that has become very dry, becomes opaque and often fails to show these shadows, or shows them differently.

Fig. 81. A very narrow area of decay penetrating the enamel in the distal surface of a cuspid. In this the action of acid has been confined to a very narrow area of the surface of the enamel. The decay has reached the dentin, following accurately the length of the enamel rods. The enamel rods have fallen out of its central portion, microörganisms have been admitted and decay of the dentin has begun. Other parts of the photograph are indistinct because it was made when the tooth was dry and the surface opaque. For the same reason the hyaline area streaking inward toward the pulp does not show. Some translucence is necessary to show these by photography.

Fig. 82.

Fig. 82. A photomicrograph showing an area of decay in the enamel in the distal surface of an incisor. The incisal edge of the tooth is upward. All the illustrations from perpendicular sections have been so placed. The letter D is placed on the dentin, E, is on the enamel. The dento-enamel junction is between these two letters. X. The beginning point of the decay of the enamel. Z. An extension of the superficial decay toward the incisal. The irregularity of the line of deepest penetration is common, as seen in photomicrographs. In this figure the enamel rods in the decayed area have been disturbed in mounting, distorting the edge representing the surface of the tooth. Areas of decay which show white by reflected light are opaque and show dark by transmitted light.

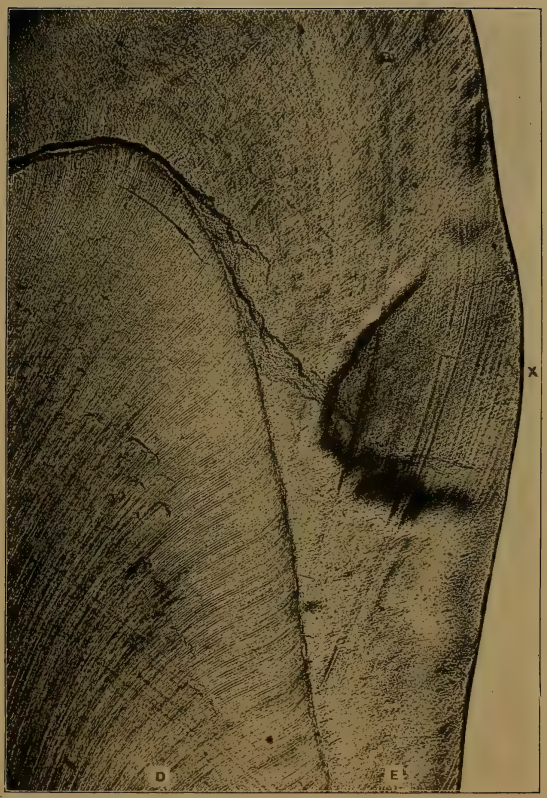

Fig. 83.

Fig. 83. A photomicrograph of a small area of the beginning of caries in enamel that shows an unusually smooth rounding of the deep line of penetration. D. Dentin. E. Enamel. The dento-enamel junction is between these two letters. X. A distinct swelling of the decayed area. This swelling is common in areas of decay in enamel.

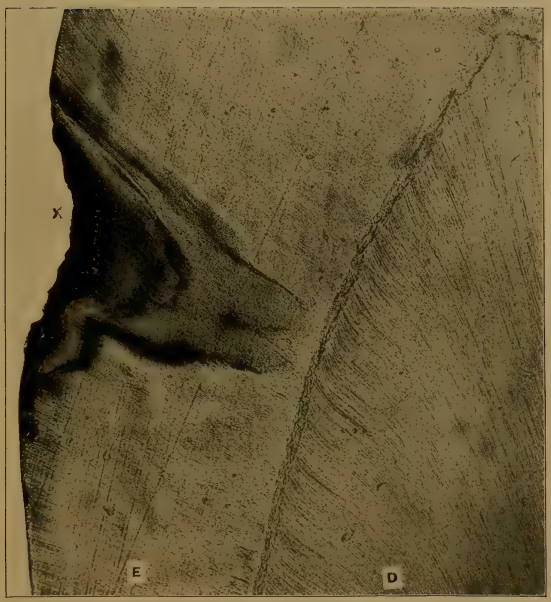

Fig. 84.

Fig. 84. Caries of enamel. D. Dentin. E. Enamel. X. Area of decay. In this figure the outer ends of the enamel rods have been broken away in grinding. Notice particularly the flamelike tongues of penetration sweeping toward the dento-enamel junction, following the lines of the length of the enamel rods. Also the penetration on the margins of the principal area are seen to follow the lines of the length of the enamel rods. This rigid following of the enamel rods is a characteristic of caries of enamel beginning in smooth surfaces.

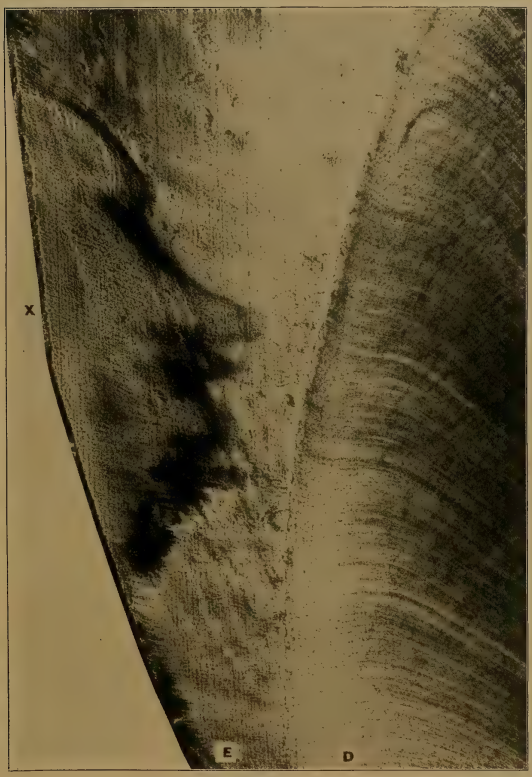

Fig. 85.

Fig. 85. A broader and flatter area of carious enamel. D. Dentin. E. Enamel. X. Area of decay. Here also we find the same inclination to the formation of flamelike tongues sweeping toward the dento-enamel junction, following the length of the enamel rods. There is no spreading of decay across the length of the enamel rods. All spreading is in new beginnings to the side on the surface of the enamel.

washings by the saliva, which would dissipate the acid formed. *Therefore, decays of the enamel, beginning in pits, are in the form of a cone, having the base on or toward the dento-enamel junction, and the apex toward the surface.*

Penetration of Enamel in Proximal Surfaces of Incisors.

ILLUSTRATIONS: FIGURES 78-85.

The conditions are entirely different on the smooth surfaces of the teeth, as the proximal surfaces. Here there is no pit or fissure, depression or fault in the enamel. It is a smooth, rounded surface. The teeth round together normally in such a way that the interproximal gum tissue fills the space to the contact point, and the contact point proper is fairly well rounded in most cases. While this condition continues perfect, there is no place for the lodgment of microörganisms upon the proximal surfaces, but, whenever the gum tissue fails to fill this space completely and a little opening is left to the gingival of the contact point, it forms a harbor or nidus at which microörganisms may lodge and begin their growth. It is probable that by this growth alone they may have something to do with forcing the gum tissue a little bit further away, and, if they are sufficiently protected from washings by the saliva, they may form sufficient acid to produce an action upon the calcium salts of which the enamel is formed.

Figures 78-81 are a group showing the manner of the penetration of enamel by caries in the proximal surfaces, as may be well seen in split teeth with an ordinary hand magnifier. Figures 82-84 illustrate the same thing in photomicrographs* produced by low powers of the microscope. The first beginning of decays upon these surfaces is often small, as is shown by Figure 78, a photograph of the distal surface of a central incisor with the spot of beginning decay very exactly in the position mentioned, just to the gingival of the contact point. This was a very white spot on a tooth that was rather dark in its general color, so that the engraver has been able to show it very distinctly. We might ask here, by what power, circumstance or condition has the action of the acid been confined to this one small spot, while all the rest of the surface of the tooth is free from any action of the acid?

* The difference between the photograph and the photomicrograph, constantly observed in their use in this work, is that the photograph is taken from an opaque object by reflected light, while the photomicrograph is taken from a thin section by transmitted light. Usually the object is much less enlarged in the photograph.

Figure 79 is a photograph from a central incisor that has been split mesio-distally through a white spot upon its distal surface but little larger that the one shown in Figure 78. In this we see the penetration into the enamel in the form of a somewhat flattened cone, or a cone with a broad base on the surface of the enamel, and the point just reaching through to the dento-enamel junction. As we will see quite distinctly later, in caries of the enamel more highly magnified, the solution of the cementing substance between the enamel rods follows directly the length of the enamel rods and continues spreading upon the surface from a spot of much smaller beginning than that now seen. At the central beginning point, or nidus, the effect of the acid has reached through the enamel to the dentin and is beginning to dissolve it, while the depth of penetration is less and less about that central point in every direction, until it runs out to quite a thin edge at the surface of the enamel. This is characteristic of beginning decays in enamel upon all of the smooth surfaces of the teeth. They begin at a central nidus, or beginning point, and spread sometimes in every direction, but generally spread most in some particular direction from that beginning point, as will be described later. Not infrequently decay begins at several points close together in a more or less even row, which takes some particular direction.

In Figure 80 we have another illustration similar to that in Figure 79, also a photograph from a lateral incisor, cut mesio-distally, with a cavity in the distal surface. This was a very white decay and shows to advantage. It will be seen that there has been considerable spreading both ways from the central nidus, and that the central portion has just penetrated to the dento-enamel junction and is quite a little in advance of the general conical form of the invasion of the enamel. Decays occur, however, that show very little or none of this spreading upon the surface, even upon the proximal surfaces of the teeth, as will be seen from an examination of Figure 81. The tooth is a little more enlarged in order to show this spot to better advantage. Here it will be seen that a cavity has formed in the enamel. Some of the enamel rods have fallen out and the effect of the acid has passed entirely through the enamel and begun to dissolve the calcium salts from the dentin, and yet the opening, or the area, of the enamel affected, as seen in this dimension (the tooth having been cut mesio-distally from occlusal to gingival), is no larger than the shaft of a large pin. The enamel rods have been exactly followed lengthwise, and the enamel about

it seems free from the action of acid. Again it might be asked: By what power, circumstance or condition has the action of the acid been confined to this narrow area?

This following of the enamel rods is better seen in photomicrographs, in which the enlargement is only just sufficient for the direction of the enamel rods to be made out. If a very high power is used, a sufficient area of the tissue of the tooth can not be included in the picture to give a correct idea of the general form and relation of the different parts. It must be understood that a decayed area that is white to reflected light, shows an opacity to transmitted light and is dark in the photomicrograph unless it is ground excessively thin. This group of sections, Figures 82, 83, 84, 85, are all cut from occlusal to gingival. Beginning decays of the enamel cut in this direction show but little superficial spreading as compared with that seen in cross section, which will be given later. The characters as to penetration, however, are the same, only less extended laterally.

Figure 82 is a photomicrograph from a lateral incisor with a beginning decay of the enamel that was very similar to that shown in the photograph, Figure 80. The form of the penetration and of the spreading on the surface are quite remarkably alike in the two cases. There has been a little disturbance of the injured tissue by crushing it together just above x forming the notch midway between x and z. There has also been some loss of the outer ends of the enamel rods from this notch to the letter z, but the main feature of the illustration, the line of penetration, is in perfect form. The starting point of the decay was about the position of the letter x, and it has spread superficially in both directions. In this case, the spreading has been most toward the incisal angle, as was the case in the photograph, Figure 80. The tendency of the line of invasion to be broken up into flamelike tongues shooting forward of the general line may also be noted.

Figure 83, a photomicrograph from a proximal decay, is almost unique in the smooth roundness of its deeper portion. It shows almost none of the flamelike tongues shooting toward the dento-enamel junction that are common characteristics of the deep border of advancing caries of enamel. The accretion lines of Ritzeus are brought out much more clearly in the decayed area. This is quite general when the direction of the section is squarely across them. In many instances, however, this seems not to occur. The swelling of the decayed area is well seen at x.

This is constantly seen in decays at this stage when no enamel rods have been lost during the preparatory work.

Figure 84 is a photomicrograph from a proximal decay of the enamel at x, which is very narrow on the surface and penetrates almost to the dento-enamel junction at the point of the cone. This cone is of somewhat irregular outline. In this case the outer ends of the enamel rods were lost in grinding. Notice particularly that at different points the tendency is for decay to advance in little flamelike tongues or projections, each following the length of the enamel rods. This is a characteristic of caries of enamel, and often, when examined in the very early beginning, the starting points are divided from each other with these little flamelike tongues projecting inward toward the dento-enamel junction. This is seen also in Figure 85 in a decay at x, which is much broader and flatter, showing less of the conical form. In this, a nidus, or beginning point, upon the surface of the enamel has been just above the letter x, and it has spread quickly over the surface to the gingival and the occlusal of this point by the increase in size of the growing colony of microörganisms on the surface. Each new beginning, with individual enamel rods, or groups of rods, follows exactly along its length toward the dento-enamel junction. Other illustrations will show this tendency more prominently than these two.

In examining many photomicrographs of caries of the enamel, we find this tendency constant and the following of the length of the enamel rods very rigid. We never find caries of the enamel spreading laterally in the interior of this tissue. It always goes straight from its starting point to the dento-enamel junction and then spreads out in the dentin. In order for decay to spread out, involving a larger area of enamel laterally in any direction, the spreading must be in the form of new beginnings on the surface. In other words, all spreading of decay of enamel from the beginning point is brought about by conditions which allow of growth and spreading of colonies of microörganisms on the surface of the tooth. No matter how broad the carious area, it projects inward in these little flamelike tongues along its deeper border. *Therefore, decays of the enamel, beginning in smooth surfaces, are generally in the form of a cone, having the base at the surface of the enamel, and the apex toward the dentin.*

Fig. 86.

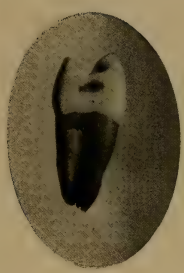

Fig. 87.

Fig. 88.

Fig. 89.

Figs. 86, 87, 88, 89. Photographs from four bicuspid teeth with superficial proximal decays. To show distinctly the gingival line, the first two have been stained slightly with eosin, which does not stain the enamel. The four teeth have been arranged to show progressively the disposition of caries to spread bucco-lingually on the proximal surfaces of these and the molar teeth. While decay is apt to begin first just to the gingival of the contact point and is confined between that and the free border of the gum occluso-gingivally, it is free to spread bucco-lingually as far as the sweep of food through the embrasures, formed by the rounding of the angles of the teeth away from each other, will allow. In Figure 86 the area bucco-lingually is very narrow. In Figure 87 a little broader, and in Figure 88 it reaches fully to the embrasures. In Figure 89 something of the disposition of decay to begin at numbers of small points along this bucco-lingual line, is seen.

Fig. 90.

Fig. 91.

Fig. 90. A bicuspid in which there is seen a disposition to broader spreading occluso-gingivally. Sometimes this is very extensive, as will be illustrated later.

Fig. 91. An upper molar in which is seen the same disposition to spread bucco-lingually as occurs in the bicuspids. This form of spreading is common to the bicuspids and molars. In this case the enamel rods have fallen out of a small area at the point of first beginning.

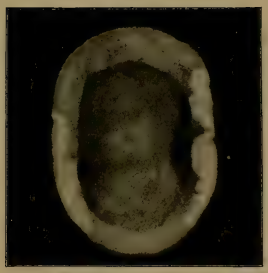

FIG. 92.

FIG. 93.

FIG. 92. A cross cut of a bicuspid crown showing decay on both the mesial and distal surfaces. This has the advantage of showing the spreading of the decay bucco-lingually in its relations to the angles of the teeth. On the right side of the picture the spreading of decay is from angle to angle; indeed, somewhat around the curve on the lingual. Also the decay is seen to have begun at several points along the line from buccal to lingual. Some solution of the calcium salts of the dentin is in progress, though no enamel rods have fallen away and microörganisms have not been admitted. A broad area of decay is shown in such an illustration, because the cut is along the length of greatest spreading on the surface. A section lengthwise of the tooth would show a narrow area of decay. On the left margin of the illustration, the area of decay is not central because the first bicuspid was in lingual occlusion. Hence the anomalous position of the beginning of decay.

FIG. 93. A cross cut of the crown of a bicuspid with a decay that has begun at a number of points, which have penetrated the enamel separately, leaving some areas of sound enamel between them at the time of extraction, but on the surface all had united.

Fig. 94.

Fig. 95.

Fig. 94. An upper first molar cut across the crown, showing a solid area of caries of the enamel stretching bucco-lingually from angle to angle of the distal surface, which has just reached the dento-enamel junction at one point. One should note especially the thinning out to the surface of the decay of enamel rounding slightly toward both the buccal and lingual angles, and the amount of sound enamel that would have to be removed in order to remove the last of the carious enamel in the preparation of such a case for filling.

Fig. 95. An upper first molar with a less extensive decay of the enamel, which has reached the dentin at two points. In this case the beginning of the decay was much further toward the gingival line than usual, and the enamel is very thin.



Fig. 96.

Fig. 96. A photomicrograph showing a portion of a section of enamel in which caries has progressed part way through its thickness. E. Enamel that is perfect. x. Decayed enamel. The decayed portion of the enamel has been filled with yellow shellac, which has taken the place of the cementing substance dissolved out from between the rods, and takes dark. The sound enamel, being solid, does not absorb the shellac. The plan of doing this is given in the text. In this particular section not much of the structure of the enamel can be seen in the undecayed portion.

FIG. 97.

FIG. 97. A photomicrograph of enamel in which caries has made considerable progress. D. Dentin. E. Enamel. X. Carious enamel. The dento-enamel junction is seen between D and E. In this case, the enamel rods appear fairly well in the sound enamel and a considerable irregularity in their course may be observed. The decayed area is filled with yellow shellac. The enamel rods appear smaller in the decayed area.

Superficial Spreading of Caries in Proximal Surfaces of Bicuspids and Molars.

ILLUSTRATIONS: FIGURES 86-95.

We pass now to the superficial conditions as seen in the proximal surfaces of the bicuspids and molars. If we examine the whitened outlines seen upon the surfaces of the teeth before any enamel rods have fallen away, we will find these decays taking certain definite forms by reason of spreading, and often starting at several points instead of at one central nidus. A knowledge of these forms and the reasons for them, is of great importance in the treatment of caries.

The group of illustrations, Figures 86-89, inclusive, shows the principal varieties of form produced by the spreading bucco-lingually of beginning decays in the proximal surfaces of the bucuspids as seen in whole teeth. This tendency is practically the same in the molars, as seen in Figure 91. These may be confined to a round spot, as is often the case in the incisors, as shown in Figure 78, but the more general tendency is to spread buccally and lingually from the beginning point. This is shown progressively in the different pictures of this group and illustrates the common tendency of caries of the enamel to spread in these particular directions. Occasionally the tendency to spread gingivally is seen, as is illustrated in Figure 90. The cause of this will be more explicitly discussed later. It should be noticed particularly here that the tendency is to spread bucco-lingually rather than gingivally, though, as will be shown later, wide spreading gingivally occurs under certain conditions. Spreading occlusally does not ordinarily occur, because that part of the surface from the contact occlusally is cleaned by mastication. As we shall see later, decays that begin much to the gingival of the contact point may spread occlusally. These beginning decays are characteristic of the surface areas of beginning decays in the proximal surfaces in the bicuspids and molars. It will be readily seen that if the cut is made horizontally instead of lengthwise of the tooth, as in split teeth herein before shown, the area of decay presented would be very different.

In the group of illustrations, Figures 92-95, inclusive, cross sections are shown illustrating the conditions from that view. Here, instead of the narrow area of decay seen in the whole teeth, as in the group 86-91, the teeth are cut crosswise through similar areas of decay. These have the additional value of show-

ing both the spreading buccally and lingually and at the same time the penetration of the enamel along this line in its relations to the individual teeth as a whole. In three of the four figures, the decay has spread across the proximal surfaces to the rounding of the angle which opens the embrasures, both to the buccal and to the lingual, practically before decay of the dentin has begun. Figure 92 is from a mouth with thick necked, squarely built teeth, in which the lingual surfaces of the second bicuspids are equally broad with the buccal, and with very flat proximal surfaces. On the distal, the decay reaches fully from angle to angle. It is easily seen in this that there were two nearly equal beginning points which have run together on the surface, but are still divided in the deeper part. On the mesial surface, it is noted that the original beginning was much to the lingual at the point where whitening completely penetrates the enamel for a little space. The spreading is toward the buccal and toward the lingual from that point. It spreads a little around the mesio-lingual angle but does not reach the mesio-buccal angle. It is easy to determine by this that the position of the first bicuspid was abnormally to the lingual of the line of the arch. This gave the opportunity for decay in this unusual position. It was prevented from reaching the mesio-buccal angle by the cleaning of this part by excursions of food crushed along this portion of the surface in mastication.

In Figure 93 there has been an unusual number of very small beginning points forming a line which had just fused together by the superficial spreading. It is particularly interesting from that fact. The tooth seems out of form for the reason that the decayed side was cut farther from the occlusal surface than the sound side. Figure 94 shows an area of decay on the distal surface of a molar that is of the more regular type, showing a solid advance of decay of the enamel, except as it thins out at the angles of the tooth. This photograph gives in relief, to speak figuratively, the reason for many cases of recurrence of decay after filling. The cutting had been carried to hard enamel, but not far enough to remove the thin portion of the decay spreading farther around toward the angles. If the filling were finished without sufficient separation of the teeth having been made, so that a little of the mesio-distal breadth of the tooth was lost, the area of near contact was increased by that much, giving better opportunity for decay to rebegin. Therefore, the filling is quickly undermined.

Many of the beginning decays observed in the proximal sur-

faces are of much less extent than in these three figures. Indeed, the general rule is that the enamel rods have fallen away in the central area quite a little before the spreading has reached its bucco-lingual limit. In this case, the spread of decay in the dentin, along the dento-enamel junction, backward decay of the enamel and breaking away of enamel, so change the conditions as to stop the superficial beginnings in the enamel. Figure 95 sufficiently illustrates this. In this case, the spreading bucco-lingually is not yet great, but the decay has penetrated the enamel at two minute points, and solution of the calcium salts of the dentin has begun. In a little more time the enamel rods would have fallen away from all of the central part of the area and so changed the conditions that the superficial spreading of caries would have ceased.

A Closer Examination of the Injury to the Enamel.

ILLUSTRATIONS: FIGURES 96-98.

Before studying further the cause of the localization and tendency to the spreading of caries in particular directions on the surface of enamel, it may be well to examine more closely the injury produced. For the illustration of this, the photomicrographs have been taken from thin sections of decays beginning in the enamel that were in every way similar to those shown in other illustrations, but with an amplification that is sufficient to display the condition of the tissue without being excessively magnified. This enables a larger area of tissue injured, in comparison with the uninjured tissue, to be shown on the ordinary book page than seems practicable with a higher amplification. In Figures 96, 97, special preparation of the tissue has been made to show the removal of the cementing substance from between the enamel rods by filling the spaces left with common yellow shellac, which takes dark in the photomicrograph. Figure 98 is without this. In Figures 96, 97, which are both from cross sections, but from different teeth, the darker portion marked with the letter x is the injured enamel, while that portion marked by the letter E is uninjured. In each case the border line between the injured and uninjured tissue is dark. The sections from which they were made were prepared as follows: (1.) The cross section of the tooth was ground flat and polished. (2.) It was then placed in absolute alcohol for twenty-four hours to remove all traces of water. (3.) It was placed on a cover-glass which was covered with a solution of ordinary yellow shellac in abso-

lute alcohol, which had been filtered to free it from all insoluble particles. (4.) It was allowed to lie in an abundance of the shellac solution for several hours. (5.) It was then placed on a steel disk and the specimen was clamped down onto the cover-glass with a heavy weight, the excess of shellac removed and then left until the shellac had become hard. (6.) The cover-glass to which the specimen was attached was then cemented to a grinding-disk, which was placed in the grinding machine and the specimen ground thin enough for examination with a twelfth-inch immersion lens. (7.) The glass, with the specimen, was then removed from the grinding-disk and at once mounted upon an ordinary slide, using for the purpose xylol balsam, which does not dissolve the shellac by which the section is attached to the cover-glass. In this way, every part of the frail tissue is retained in its normal position. From the photomicrograph of this the engraving is made without the slightest retouching.

It is seen by examination of the illustrations that the spaces, formed between the enamel rods by the solution of the cementing substance by the acid causing the injury to the tissue, have been filled by the shellac, which photographs dark. This divides the carious area, marked by the letter X, sharply from the sound tissue, marked by the letter E, and displays the enamel rods, or the undissolved central portions of them, lying in a dark field, each in its normal position. The adjacent undecayed enamel does not absorb the shellac and remains white. In Figure 96 the sound enamel shows scarcely a trace of structure, while in Figure 97 the enamel rods in the sound tissue are very well brought out. This difference in unetched sound enamel is often met with. In both specimens the area decayed is also sharply divided from the normal enamel by a broad, dark band, which occurs in many specimens in which no shellac has been used, as will be seen in most of the photomicrographs of decayed enamel in this volume.

If we examine carefully these illustrations as to the comparative sizes of the enamel rods in the undecayed and the decayed areas, it is found that they are much reduced and more slender in the decayed areas. This may be made out also in Figure 98, which has not been filled by shellac, but not so clearly. In the grinding of this latter specimen, the machine was adjusted to stop when the specimen was one one-thousandth (1-1,000) of an inch thick. Such specimens are extremely frail. When the solution of the enamel rods has gone a little further than shown in these illustrations, the whole structure falls to

Fig. 98.

Fig. 98. A photomicrograph from a very thin section of carious enamel ground on the cover glass in hard balsam. E. Perfect enamel. X. Carious enamel. The line between the sound and carious enamel is fairly sharp, and follows closely the length of the enamel rods.

Fig. 99.

Fig. 100.

Figs. 99, 100. Photographs of the upper molars and bicuspids of the right side in their normal relations to each other, with the soft parts removed to show the interproximal spaces, interproximal contacts and areas of near approach of the surfaces of the teeth. The two pictures taken together, the first showing the buccal surfaces and the second the occlusal surfaces, give a good view of the interproximal spaces, breadth of contact occluso-gingivally, and breadth of near approach of surfaces bucco-lingually, with their variations. They also show the openings of the embrasures buccally and lingually, with their variations in depth.

pieces at a touch, and most generally through the whole thickness of the enamel at once. This seems to be due to the complete loosening of the ends of the rods from the dentin. In unprotected places, however, such as decays of buccal or labial surfaces, and decays of proximal surfaces in which there has been interference by the crowding of food through the contact, a considerable number of cases are found in which the outer ends of the enamel rods are broken before the enamel has been penetrated. In the greater number of cases, however, in any of these positions, a considerable solution of the dentin has occurred by the acid which has penetrated through the enamel before any enamel rods have fallen away. This is well attested in many of the illustrations presented.

The Relation of the Occlusion to the Localization of Caries.

ILLUSTRATIONS: FIGURES 99-103.

When we come to study carefully the forms of the teeth in their relations to each other as they stand in the arch, and their uses in the mastication of food, we find that there are certain points or areas of their surfaces that are comparatively free from rubbing, or abrasion, while much the larger part of the tooth surface is exposed to friction and washings by the fluids in the mouth. The occlusal surfaces particularly are exposed to severe abrasion in the mastication of food. The lingual surfaces, both above and below, are exposed to the friction of the tongue and of the food that is washed over them during mastication, so that these surfaces are fairly well cleaned. The buccal surfaces are less exposed to friction during mastication and to washings by the saliva during the motions of the tongue, cheeks and lips, particularly in their gingival thirds. The proximal surfaces are shielded from abrasion and from washings by the saliva by the contact and areas of near approach of these surfaces with adjoining teeth. Decays beginning in the depths of the pits of the occlusal surfaces have no opportunity to spread upon the surface of the enamel, for the reason that these surfaces are so continually cleaned by abrasion in mastication and by washings by the saliva. It seems to be for these reasons, principally, that decay does not spread superficially upon these surfaces. It is prevented by the forms and the uses of the teeth. It seems to be purely these local conditions that are the basis of the strict localization of the begin-

nings of dental caries in certain positions in the enamel to the exclusion of all others. These are physical conditions controlling lodgments of debris. They are also physical conditions preventing the removal of anything which may become attached to the enamel in these positions.

If we study the relations of the proximal surfaces of the different teeth to each other, we find that various forms of contact and near approach of these surfaces serve to shield certain areas from all friction from mastication and in which the deposit of a very little gummy material will shield colonies of microorganisms from all washings by saliva. This may be studied in the illustrations. Figures 99, 100, show the buccal and the occlusal surfaces of the upper bicuspids and molars as they stand in the arch. The teeth are in the same relation to each other in each figure. The soft tissue filling the interproximal spaces has been removed in order that the forms of these may be better seen. In studying the buccal view, it will be seen that the points of near approach of surfaces are very narrow and rounded in form from occlusal to gingival, so that the actual touch point of unworn teeth is very small, like that of two marbles coming in contact, while, in the view of the occlusal surfaces, the points of near approach of the teeth to each other are shown to be very much broader in the bucco-lingual direction.

The decays in the proximal surfaces of the bicuspids and molars, in Figures 86-91, inclusive, correspond in form with the areas of near approach of the surfaces of the teeth so closely and so constantly that we must connect these relations as cause and effect, controlling both the localization and superficial form of the beginning and spreading of caries in the enamel. To gain correct expressions of this, the study must be confined to those beginnings of decay that have not yet penetrated the enamel, or in which the enamel rods have not yet fallen out, for, with the breaking away of the enamel after decay of dentin has begun, the particular form of the beginning upon the surface of the enamel is often quickly lost.

A study of the forms of the surfaces making the contact of different teeth as seen in the occlusal view, will show great variations in the bucco-lingual length of near approach of these surfaces. The area of near approach of surfaces is much longer bucco-lingually between the second bicuspid and the first molar than that between the two bicuspids. Therefore, a beginning decay between the second bicuspid and first molar will spread and become longer bucco-lingually in these than a beginning

decay would do between the two bicuspids. The differences in this respect among the teeth of the same mouth, and especially among the teeth of different mouths, are very great.

As this study of forms of contact and near approach accounts for the differences seen in forms of decay in this respect, as shown in illustrations given of the bicuspids and molars, Figures 86-91, inclusive, it also accounts for the differences shown of the breadth of decay in illustrations made from cross sections of the teeth, Figures 92-95, as compared with sections made lengthwise of the tooth. A section made lengthwise of a tooth may show a very narrow injury to the enamel, while, if the section were made crosswise of the tooth, cutting through the length of the injury, it would show a very broad beginning of decay. This will be seen more clearly by a comparative examination of sections cut in these different directions which show the great difference in the form and extent of the injury to the enamel. This will be appreciated by comparing the cross sections, Figures 92-95, with the photographs of split teeth, Figures 107, 108, 112, 113, 117.

The embrasures, or the openings formed on the buccal and on the lingual by the rounding of the surfaces of the teeth away from each other, vary greatly in depth among the different embrasures of the same mouth, and particularly they vary in depth among the teeth of different persons, owing to the forms of the teeth and the form and prominence of the proximal contact points. It must be remembered that in normal conditions in young people, the interproximal space is filled with gum tissue to, or very nearly to, the contact point, and that the gum tissue arches up to this from the buccal and the lingual. In studying this, it will be found that the beginning of decay is close to the line of the margin of this arch of gum tissue, and it does not spread to the gingival unless the gum tissue has been pushed away by lodgments of food between the teeth. Therefore, unless lodgments of food have occurred, the forms of beginning decay will retain that narrowness from occlusal to gingival that has been shown, and the spreading bucco-lingually will generally coincide with the length of the close approach of the surfaces to each other.

If we study the teeth in their occlusion under normal conditions, we will find a provision of very considerable importance in the relation of the cusps of the upper teeth to the embrasures between the lower teeth, and, vice versa, the arrangement of the cusps of the lower teeth with respect to the embrasures in

nings of dental caries in certain positions in the enamel to the exclusion of all others. These are physical conditions controlling lodgments of debris. They are also physical conditions preventing the removal of anything which may become attached to the enamel in these positions.

If we study the relations of the proximal surfaces of the different teeth to each other, we find that various forms of contact and near approach of these surfaces serve to shield certain areas from all friction from mastication and in which the deposit of a very little gummy material will shield colonies of microorganisms from all washings by saliva. This may be studied in the illustrations. Figures 99, 100, show the buccal and the occlusal surfaces of the upper bicuspids and molars as they stand in the arch. The teeth are in the same relation to each other in each figure. The soft tissue filling the interproximal spaces has been removed in order that the forms of these may be better seen. In studying the buccal view, it will be seen that the points of near approach of surfaces are very narrow and rounded in form from occlusal to gingival, so that the actual touch point of unworn teeth is very small, like that of two marbles coming in contact, while, in the view of the occlusal surfaces, the points of near approach of the teeth to each other are shown to be very much broader in the bucco-lingual direction.

The decays in the proximal surfaces of the bicuspids and molars, in Figures 86-91, inclusive, correspond in form with the areas of near approach of the surfaces of the teeth so closely and so constantly that we must connect these relations as cause and effect, controlling both the localization and superficial form of the beginning and spreading of caries in the enamel. To gain correct expressions of this, the study must be confined to those beginnings of decay that have not yet penetrated the enamel, or in which the enamel rods have not yet fallen out, for, with the breaking away of the enamel after decay of dentin has begun, the particular form of the beginning upon the surface of the enamel is often quickly lost.

A study of the forms of the surfaces making the contact of different teeth as seen in the occlusal view, will show great variations in the bucco-lingual length of near approach of these surfaces. The area of near approach of surfaces is much longer bucco-lingually between the second bicuspid and the first molar than that between the two bicuspids. Therefore, a beginning decay between the second bicuspid and first molar will spread and become longer bucco-lingually in these than a beginning

decay would do between the two bicuspids. The differences in this respect among the teeth of the same mouth, and especially among the teeth of different mouths, are very great.

As this study of forms of contact and near approach accounts for the differences seen in forms of decay in this respect, as shown in illustrations given of the bicuspids and molars, Figures 86-91, inclusive, it also accounts for the differences shown of the breadth of decay in illustrations made from cross sections of the teeth, Figures 92-95, as compared with sections made lengthwise of the tooth. A section made lengthwise of a tooth may show a very narrow injury to the enamel, while, if the section were made crosswise of the tooth, cutting through the length of the injury, it would show a very broad beginning of decay. This will be seen more clearly by a comparative examination of sections cut in these different directions which show the great difference in the form and extent of the injury to the enamel. This will be appreciated by comparing the cross sections, Figures 92-95, with the photographs of split teeth, Figures 107, 108, 112, 113, 117.

The embrasures, or the openings formed on the buccal and on the lingual by the rounding of the surfaces of the teeth away from each other, vary greatly in depth among the different embrasures of the same mouth, and particularly they vary in depth among the teeth of different persons, owing to the forms of the teeth and the form and prominence of the proximal contact points. It must be remembered that in normal conditions in young people, the interproximal space is filled with gum tissue to, or very nearly to, the contact point, and that the gum tissue arches up to this from the buccal and the lingual. In studying this, it will be found that the beginning of decay is close to the line of the margin of this arch of gum tissue, and it does not spread to the gingival unless the gum tissue has been pushed away by lodgments of food between the teeth. Therefore, unless lodgments of food have occurred, the forms of beginning decay will retain that narrowness from occlusal to gingival that has been shown, and the spreading bucco-lingually will generally coincide with the length of the close approach of the surfaces to each other.

If we study the teeth in their occlusion under normal conditions, we will find a provision of very considerable importance in the relation of the cusps of the upper teeth to the embrasures between the lower teeth, and, vice versa, the arrangement of the cusps of the lower teeth with respect to the embrasures in

the upper teeth. This will be seen in Figure 101. Beginning with the third molars, we find that the cusp of the lower third molar occludes directly under the embrasure between the second and third molars of the upper jaw and will force food through that embrasure especially, while the second molar of the upper jaw has its distal cusp over the embrasure between the second and third molars of the lower jaw and will force food through it. This arrangement is repeated among all the molars and bicuspids. The result is that, in mastication, the food is caused to run through the embrasures by the crushing action of the teeth. The effect of this arrangement will perhaps be better understood by comparison with the occlusal surfaces of the same teeth as seen in Figures 102, 103, noting carefully the forms of the individual embrasures and their variations. This abrasive action by the food is increased by the cheeks and tongue also pressing upon the food laterally, causing it to be crushed down over the buccal and lingual surfaces of the teeth, and more particularly through these embrasures. In fact, this lateral pressure on the food is an endeavor to hold it between the occlusal surfaces of the teeth. The result is that the food is forced through the embrasures especially, causing it to rub the angles of the teeth from their occlusal surfaces to the gum margin.

This abrasive action of the food serves to limit sharply the distance that attached colonies of microörganisms may spread toward the buccal or lingual angles of the teeth because of their removal from the surfaces by the passing of food through these embrasures during mastication. It also explains another fact of great importance in the treatment of caries of the teeth by filling, for it was found by actual count of ten thousand persons examined that only in about one case per thousand, decay was found to have spread superficially, or upon the surfaces of the teeth, across the angles. *Therefore, near to, or along these angles, is the safest place to lay cavity margins.*

Caries never begins on the angles of the teeth nor spreads superficially past these angles in any case in which the teeth are in normal relations and the person is making active use of them in mastication; this may be stated without fear of successful denial. All of the cases of such spreading that have come under my observation in twenty-five years of close study of this point, have been in persons who have practically ceased to use their teeth in the mastication of food because of some interference. This has generally been sensitiveness of exposed pulps in decayed teeth, and at the same time the persons had

FIG. 101.

FIG. 101. Photograph of the teeth in normal occlusion, including the alveolar processes and bones. This is given as a study of the normal relations of the cusps of the teeth of the upper arch to the embrasures of the lower, and the relations of the cusps of the lower teeth to the embrasures of the upper. It will be seen that among the bicuspids and molars this relation is constantly such as to force food through these embrasures in chewing.

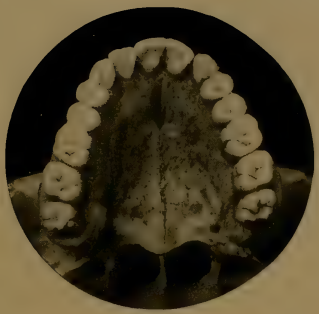

Fig. 102.

Fig. 103.

Figs. 102, 103. Photographs of the upper and lower teeth shown in Figure 101. In these it will be seen that, while the molars and bicuspids are in normal occlusion, the left lateral incisor is missing in the upper jaw. This has forced an irregularity of the incisors of the lower jaw. These give an additional study of contacts, embrasures and near approach of areas of the proximal surfaces.

become entirely careless as to artificial cleaning. The study of this phase of the spreading of caries and its limitations is of the utmost importance. The student and the practitioner should be continually studying it in the mouths of his patients, making out carefully areas of spreading decay and their normal limitations under the conditions which he finds. This, if carefully carried out, will serve as a guide of great importance in the extensions necessary in the preparation of cavities to prevent recurrence of decay about cavity margins.

In the consideration of the beginning of caries of the enamel with reference to treatment, it may be stated, as a fundamental proposition, *that the nidus of each beginning of caries will be found at that particular point on the surface of the tooth attacked, or that may be attacked in the future, that offers the best position for the lodgment and undisturbed growth of colonies of microörganisms.* These colonies and the caries will spread superficially on the surface to those lines where their further spread is limited, (1) by the position of normal gum tissue; (2) by abrasion of mastication by excursions of food through the embrasures; or (3), by artificial cleaning. When this nidus is destroyed by the falling away of the enamel rods because of caries of the dentin, before such spreading has reached its limit, as often happens, the conditions are usually so changed that the growth of colonies on the surface of the enamel is prevented. This at once limits further superficial spreading buccally and lingually on the lines thus far illustrated. Further superficial spreading gingivally, may or may not occur, as will be illustrated later. The lateral superficial spreading seems to be stopped by the frequent catching of stringy foods on the roughened area and the worry of the parts in its removal, or by the frequent forcing of these lodgments further to the gingival at each meal time. In many of the cases the loss of the central and best attachment of the organisms may of itself be sufficient to produce this effect. However this may be, much careful observation shows that after the opening of the cavity this stoppage occurs in many cases. But if a good and perfect filling is made, restoring the original form and conditions without reference to the possible further spreading of the growth of colonies of microörganisms, such filling will reëstablish the nidus for growth and this will recur on the filling and extend to the full limit that it might have done if the original nidus had not been destroyed, thus reëstablishing caries beyond the margins of the filling. In this way, a well-made filling in the mechanical

sense, restoring the original contour perfectly but without reference to the superficial spreading of caries, may become the cause of wider spreading of decay on the surface than would have occurred without it. Further, in practice, it will be found that when proximal fillings are made without separating the teeth to gain room for the finishing of the fillings to the full original contour, with the original fullness of the contact points, but necessarily losing a little of the original mesio-distal breadth, the area of near approach of the proximal surfaces is increased, the embrasures are made shallower and the opportunity for recurrence of caries at the bucco-gingival and linguo-gingival angles of fillings is increased.

Penetration of the Enamel in Buccal and Labial Surfaces.

Caries beginning in the buccal and labial surfaces presents the same characters as to penetration of the enamel and spreading in definite directions as decays beginning in the proximal surfaces. In this case the line of beginning is along the free margin of the gum in the middle third of the surface mesio-distally. The lines of extension in spreading are toward the mesial and the distal angles of the tooth. The beginning of these decays often forms a narrow whitened line, the length of which is from mesial to distal. These, taken with the decays of the proximal surfaces, tend to form lines encircling the teeth along the free margins of the gum. This is very generally defeated by the failure to spread across the angles of the teeth. But when the angles are passed and when connected by decay on the lingual surfaces, which sometimes occurs, the complete girdling of the teeth is accomplished. Frequently we may find, in the first beginning of the decay on buccal surfaces, several starting points which later run together, forming a continuous line of whitened enamel. This gives, in cross sections of the tooth, appearances almost exactly similar to those shown in Figures 92-95, inclusive. As the very general rule, the extension of decay on the surface of the enamel is stopped at the mesial and distal angles of the surface.

While these decays occur in a much less number of persons than proximal decays, they often attack tooth after tooth in quick succession, and progress very rapidly in the enamel, destroying considerable areas of enamel tissue. They become wide-open cavities, and, in the mouths that have very little care, are apt to run a rapid course.

This subject will be presented in greater detail under the heading, "Caries as a Whole."

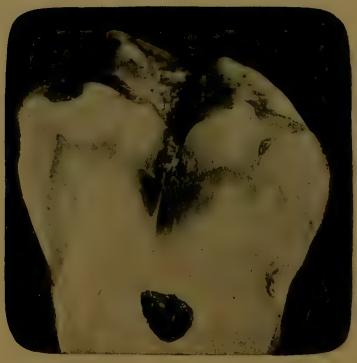

FIG. 104.

FIG. 104. Photograph of a split upper first molar with an occlusal decay of ordinary form. Note a small beginning of decay of enamel in the distal surface, and a decay beginning in the cementum. This latter is characteristic of decays which occur because of crowding of food into the interproximal space, with resulting absorption of the interproximal gum tissue.

Fig. 105.



Fig. 106.

Figs. 105, 106. Photographs showing decays in occlusal pits, in which the opening through the enamel has become larger and the decayed areas are of less depth in proportion to their breadth. Some proximal decays are also shown.

CARIES AS A WHOLE. ITS CLINICAL FEATURES.

In the further consideration of the injuries inflicted by caries of the teeth, we may include caries of both the enamel and dentin. In this we may consider the processes as a whole, noticing the various characters presented in the beginning and progress, controlled purely by local or clinical conditions. These conditions have no special signification as to immediate or remote cause of caries further than location or condition of tissue which may influence the action of these causes. Yet these causes which are brought into action, seemingly because favorable conditions for their active development have been presented, can not be lost sight of in any consideration whatever. It may truly be said that, without the presence of the principal causes no decay could occur, and also that, without reasonably favorable conditions for their action, these causes would not produce decay.

This may be said to constitute the clinical features of dental caries, and in its consideration frequent reference will be made to the clinical management of cases. One of the surprising features of the study of dental caries that comes sharply in view when the history of the development of our knowledge of it is closely scanned, has been its complete divorcement from all clinical consideration. It seems to be correct to say that a large number of even the most earnest workers in dentistry are doing their work of treatment by rote, without any proper thought of the relations which their plan of treatment may bear to the conditions that have localized the decay being treated at that particular spot, and making inadequate provision, or too often no provision at all, for the prevention of a recurrence of the trouble. It is only recently that there has been any special study given to the conditions of the beginning of caries of the enamel, which really is the all-important question in the study of dental caries considered from the clinical standpoint. One of the noblest pieces of scientific work in pathology was Dr. W. D. Miller's investigation of dental caries. It not only developed the questions at issue, but completed the investigation so that the rest of us, in repeating his experimental work, could only say, well and correctly done. But this investigation was confined exclusively to the immediate active cause of caries as it occurs in dentin. Decay of enamel, or the conditions localizing

beginnings of this, which constitutes the initial lesion, without which caries of dentin never occurs, was left untouched. These constitute the principal clinical features of the disease we are treating. Our knowledge of them is, as yet, but partially developed, particularly in that the systemic conditions of susceptibility and immunity are but indefinitely known; and observers do not yet agree as to the especial relations of acid saliva and of microörganisms to the particular processes in the earlier parts of the beginning of caries of enamel.

Occlusal Surface Decays in Molars.

ILLUSTRATIONS: FIGURES 68-71, 104-106.

Principal clinical features: (1.) Absence of superficial spreading on the enamel. (2.) Rapid burrowing along the dento-enamel junction. (3.) Spreading in the dentin in true conical form. (4.) Great softening of dentin in advance of the decomposition of the organic matrix. (5.) Very large decays often occurring while the opening to the surface remains small. These characters are common to decays beginning in pits and fissures wherever found.

The conical form of decays of dentin beginning in pits, in the occlusal surface or elsewhere, the spreading along the dento-enamel junction, and the absence of spreading superficially on the surface of the enamel, have been considered in previous articles and some principal illustrations, Figures 68-71, given. For the further illustration of the clinical features, the Figures 104-106, inclusive, are here provided. It will be seen that Figure 104 and other figures of this group show the same form of decayed area more or less perfectly, the detail being different in some degree on account of size of the decayed area or the particular form of the surface of the tooth about it. In each case illustrated, the direction of force in the use of the chisel in opening the cavity so as to fully uncover the area of decay, may be studied. The case illustrated in Figure 104, considering the tooth as a whole, is complicated by two other decays, both of them in the distal surface; one a very shallow decay, beginning in the enamel at the usual point of beginning decays, and the other a decay beginning in the cementum and penetrating into the dentin at the gingival line. This latter is a serious complication in the clinical sense, which has arisen from neglect of the leakage of food into the interproximal space. In Figures 105, 106, the openings through the pits, in which the decay has

begun, are unusually large. This has occurred by the breaking away of the enamel about the pit much earlier in the progress of the decay than usual. In response to this early widening of the pit, giving a greater opportunity for washing out acids formed in the dentin, the penetration of the dentin presents a much less pointed cone, the penetration is less in proportion to the breadth than in cases in which there is less breaking of enamel about the pit. This is seen most distinctly in Figure 106. In studying these illustrations, one must divide the area of actual decay from the cloud (hyaline area) stretching away toward the pulp. In Figure 105 there is really very little decay of dentin. The triangular (in section) cloud stretching toward the pulp chamber is not softened dentin. In Figure 106 the area of decay is more definitely outlined by the distinctly darkened area which is flattened or rounded rather than in the typical conical form. This is characteristic of a wide opening through the enamel. The rate of progress of decay is quite apt to be greater where it is hidden away under the overlapping enamel than in the central parts. The tendency, therefore, is to form broad, flat cavities. Both of these cases, considering each tooth as a whole, are complicated by proximal decays. On account of ease of access and the absence of the tendency to superficial spreading of decay, these cavities and pit cavities, wherever they occur, are the simplest of cavities in the clinical sense. The only thing requiring special attention outside of the area of decay and its full exposure by trimming away the undermined enamel, is to see to it that all grooves are cut out to such a point as will give opportunity for a smooth finish of the filling.

Proximal Surface Decays in Molars.

ILLUSTRATIONS: FIGURES 107-111.

Principal clinical features: (1.) The beginning decays of this class are hidden from view in the proximal surfaces of the teeth, making their early discovery difficult. (2.) A tendency to wide spreading on the surface of the enamel, bucco-lingually, making extension for prevention necessary in filling operations. (3.) Tendency to the early undermining of the marginal ridge by the extension of decay along the dento-enamel junction and the exposure of the cavity by its breakage. (4.) Wide secondary spreading gingivally in a considerable number of cases which is liable to be overlooked in the preparation of cavities. (5.) Recurrence of decay at the bucco-gingival and linguo-gingival

angles of fillings when judicious extension for its prevention is neglected. (6.) Recurrence at the gingival margins of fillings where contacts are of bad form, allowing food to leak into the interproximal space. (7.) Hence the requirement that correct forms be given contact points in the finishing of fillings.

The conical form of cavities in the dentin is a little different in proximal cavities, where seen in sections cut mesio-distally, from those in occlusal surfaces, because of the difference in the trend of the dentinal tubules from the line of the dento-enamel junction toward the pulp of the tooth. It is still a cone, however, with its base placed diagonal to its length, or in section it is a triangle, having one of its basal angles obtuse. The tendency to this form is best displayed in the decays in Figure 110. In general, there is a greater tendency to rounding of the general line of invasion of dentin than is seen in the decays beginning in occlusal surfaces. There is the same tendency to wide softening of the dentin more rapidly than the decomposition of the organic matrix when the opening in the enamel is small, as is seen elsewhere; but this disappears when the enamel breaks away, exposing the cavity to the occlusal surface. As the time in relation to the progress of the decay at which this breakage of the enamel occurs is very variable, extensive burrowing with large amounts of softened dentin is liable to be found unexpectedly in that which seemed, upon superficial examination, to be a small cavity. The large proximal decays in Figures 110 and 111 show something of the extent to which these cavities may burrow before the marginal ridge breaks away, exposing them to the occlusal surface.

A lower molar is shown, in Figure 107, with a mesial surface decay and a distal surface decay, both of which are excellent types of the early beginnings of caries in these surfaces. In that in the mesial surface, the decay has just passed through the enamel, no enamel rods having yet fallen away. In the distal surface the enamel rods have fallen out and the extension of caries along the dento-enamel junction is making progress. This is seen best in the picture to the right. From this the hyaline zone stretches away to the pulp chamber. This picture is a most excellent study. It is well to note the small amount of dentin between the occlusal surface and the pulp in this case, and also the great extension of the mesial marginal ridge of the pulp. The frequent extension of the mesio-buccal horn of the pulp in both upper and lower first molars is a menace in cavity preparation that should be carefully guarded against when possible, by

Fig. 107.

Fig. 108.

Fig. 107. A photograph giving an excellent showing of a mesial and a distal decay in a lower molar that have made but little advancement. The two halves of the tooth are shown, giving two views of each decay. In the decay in the mesial surface the enamel rods have not yet fallen out from any part. The enamel has been penetrated, however, and in the half on the left side some solution of the dentin is apparent. In this, another feature not so frequently met with, is the compression of the decayed area by contact with the next tooth, which is apparent in both halves but is most prominent in the half on the left side. It is not uncommon to find a decay that has progressed about as this has done (but situated just to the gingival of the contact), swollen so as to have become flattened against the proximating tooth or even to take its form for a space. But for the area of decay to occupy the contact point as in this case is infrequent. In the decay in the distal surface, the enamel rods have fallen out of the central area, and in the half on the right side, there is an excellent showing of the projection of decay along the dento-enamel junction. The illustration is also an interesting one because of the showing of the unusual nearness of the pulp to the occlusal surface and the danger of exposing the mesial marginal ridge of the pulp, or horn of the pulp.

Fig. 108. An upper first molar with a distal decay which has made considerable progress, and has undermined the distal marginal ridge.

FIG. 109.

FIG. 110.

FIG. 111.

FIG. 109. This photograph discloses three decays; one in the mesial surface, one in the distal surface, and one in the occlusal surface. The decay in the distal surface is not well shown because of the loss of a part of the enamel. The decay in the mesial surface is cut to one side of its central area and shows the undermining of the enamel buccally beyond the area of penetration of the enamel, and shows well the area of whitened backward decay of the enamel. The extraordinary prolongation of the mesio-buccal horn of the pulp is also an interesting feature of the specimen.

FIG. 110. The decay on the right side of the illustration shows a very prominent clouding extending to the pulp. This also shows particularly well the form of the clouded area, with the base of the cone placed diagonal to its length, caused by the relation of the direction of the dentinal tubules to the proximal surfaces. The actual decay of the dentin in this case is marked by the very dark area about the small opening in the enamel. The spreading along the dento-enamel junction is very wide. The decay in the mesial surface has exposed the pulp before the mesial marginal ridge has broken so as to expose the cavity.

FIG. 111. This tooth has an unusually heavy enamel cap. This seems not to have been any bar to the penetration of caries, but has prevented the breaking of the marginal ridge disclosing the cavity to the occlusal surface, though it is extensively undermined.

avoiding cutting through its recessional line. This recessional line is usually nearly a direct line from the point of the cusp to the present location of the point of the horn of the pulp. Where the point of the horn may be located along that line in any individual case can not be told in advance, but that it will not be much out of that line is a certainty. When it is possible, cutting that line should be avoided.

In this group of pictures, and in the next following, the clouded areas stretching away from the areas of decay toward the pulp are particularly prominent. The best examples are in Figures 110, 113 and 117. It is an almost constant appearance in some form, even in the freshest decays, after the acid has begun to dissolve the calcium salts of the dentin, but it never appears before the enamel has been penetrated. It was first described by John Tomes and by him was called the hyaline area in advance of actual caries. It finally became known as the hyaline area of Tomes. At first Mr. Tomes supposed this was caused by an increased deposit of calcium salts, filling the dentinal tubules. While the chemico-vital theory of caries was held, this was looked upon as an effort to bar the further progress of caries by building against it. With further studies, this explanation became untenable. It now seems more probable that it is caused by the death of many of the dentinal fibrils. The appearance differs much in different cases. It may be either a cloud fringed with white, or a white area fringed with cloud, an irregular distribution of these, or it may be wholly of the one or the other. It appears to the best advantage in photographs of split teeth by reflected light, and its prominence in the photograph depends much upon the condition of the dentin as to translucence at the moment of photographing. A freshly cut tooth is apt to show it best, and, if it is photographed at once on being removed from water, the surface being simply wiped dry, the appearance will be much stronger than it will be if the tooth has been allowed to dry. Therefore, it has happened occasionally in the pictures presented that the photograph of one of the halves of a tooth has shown this strongly, while the other half of the same tooth has scarcely shown it at all. How much actual injury to the tooth is done by that influence which causes this hyaline zone can not well be told. That there is a distinct injury is certainly true. It seems now that the most rational explanation is that in this zone many of the dentinal fibrils are dead from the irritation caused by the progress of caries. If this is true, the extension of this to the pulp may be

the cause of the hyperæmia of the pulp that so often occurs in carious teeth before the pulp has become involved or exposed to the actual carious process.

In studying the decays of this tooth, Figure 107, or others of this group, it will be seen that any effort to prepare these smaller cavities as simple proximal cavities, would inevitably produce conditions which would cause failure of the fillings, for the reason that they are situated so close to the marginal ridges that the enamel rods slope very much toward the ridge. Further cutting in that direction to obtain a clean enamel wall, or to remove the decay projecting along the dento-enamel junction, would bring the margin of the filling to an impossible point, because of the direction of the enamel rods. Therefore, the marginal ridge should be cut through and anchorage made in the form of a step in the occlusal surface.

This is more sharply illustrated in the undermining of the distal marginal ridge in Figure 108, in which decay has made a little further progress. In such positions, this undermining is generally done very early in the progress of the decay and the marginal ridge breaks away, exposing the cavity correspondingly early. This generally gives the patient the first suggestion of the presence of a cavity. Often, also, the dentist overlooks these decays until this breakage reveals them. This is often fatal to the pulp of the tooth, especially in cases in which the decay has begun farther to the gingival, as in the decay on the left, in Figure 110, or in those cases in which the enamel cap is unusually strong, as in Figure 111. In the decay seen in the right of Figure 110, the undermining of the enamel seems extreme. This is often the case in those decays that have penetrated the enamel as a small opening without much superficial spreading, as is apparent in this case. In Figure 109 there is an excellent showing of backward decay of enamel in the decay seen on the left of the figure. In this case the cut is to one side — the buccal side — of the central area of the decay, and shows the projection of the decay buccally, along the dento-enamel junction, its progress in the dentin and the whitened area showing the backward decay of the enamel. Incidentally this cut has been in the line of the projection of the mesio-buccal horn of the pulp, which is unusually long, demonstrating again the clinical necessity of avoiding the recessional line of this horn of the pulp in the preparation of cavities, both proximal and occlusal. For here it may also be noticed how very close the small occlusal cavity is to this horn of the pulp. Finally, it is

Fig. 112.

Fig. 113.

Fig. 112. A photograph of a split bicuspid disclosing three beginning decays which only just reach the dento-enamel junction. Any one of these will quickly undermine the dento-enamel junction if neglected. The pit decays, if allowed to become deep, often undermine the enamel of the proximal surfaces also.

Fig. 113. A beginning decay in the mesial surface of a small three-cusped molar, in which solution of the dentin is just beginning. A very characteristic light-colored hyaline area in the dentin is fringed with deep cloud. The decay of the enamel has extended considerably toward the occlusal surface.

Fig. 114.

Fig. 114. The photograph in this case was taken with the surface dry, with the expectation that the areas of decay would show whiter. This succeeded well with the decay on the left side, but not with the one on the right. The hyaline area of the left decay is well shown. The extension occlusally of decay along the dento-enamel junction and the very white backward decay of the enamel are interesting features. After this photograph was made, the polished surface was cemented to a cover glass and ground thin for photomicrographing, and Figures 115, 116 were made.

FIG. 115.

FIG. 115. Photomicrograph showing the carious area seen on the left of the small photograph, Figure 114. D. Dentin. E. Enamel. X. Area of decay. Y. Line of actual solution of the calcium salts of the dentin. Z. Backward decay of the enamel, which shows very white by reflected light, but is dark by transmitted light. In the drying of the specimen, the decayed dentin has shrunken and pulled a little away from the enamel. A slight break of the enamel rods has occurred at x, and a little confusion of the decayed rods has occurred near the letter Y. No enamel rods have fallen out, however, and microörganisms have not been admitted to the dentin.



FIG. 116.

FIG. 116. Photomicrograph of the decayed area on the right side in Figure 114. D. Dentin. E. Enamel. X. Area of decay. Z. An extension of the superficial beginning of decay of the enamel occlusally. The dento-enamel junction is seen between D and E. In this case the enamel rods have fallen into a tangled mass in the deeper portion of the central part of the decay at X, leaving a partly open cavity in the enamel. The dentin beneath is considerably decayed but has not been pulled away from the enamel by shrinkage. The extension of the decay, as seen in the perpendicular section, has been toward the occlusal portion of the tooth. The extension of beginning on the surface seen at Z is in a degree separated from the principal area of decay and extends toward the dento-enamel junction in a flamelike tongue, following the course of the enamel rods.



FIG. 117.

FIG. 117. This excellent photograph of a split bicuspid with mesial and distal decays is remarkably similar to the last, but in many ways a more perfect picture than Figure 114. In the decay on the left, the enamel rods are broken down and are lying in the cavity in the enamel in a tangled mass. In the decay on the right, the enamel rods are still in perfect position and no microörganisms have been admitted to the dentin. The dark portion of the dentin accurately exhibits actual decay of the dentin in both decays. The hyaline areas are both very well shown. The forked projection of the flamelike tongue on the left, formed by the border of cloud, is one of the singularly interesting features.

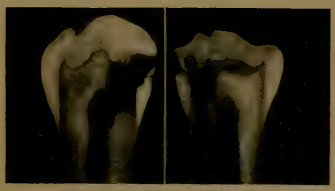

Fig. 118.

Fig. 118. The halves of a split bicuspid in which decay, through an opening through the enamel that has remained small, has involved the pulp before the marginal ridge has broken, though it is extensively undermined.

well to notice that the very heavy enamel cap shown in Figure 111 has been no bar to the invasion of caries, but that, on the other hand, has been rather a menace in that the failure to break away early has kept the cavity hidden and maintained conditions favorable to the rapid advance of caries of the dentin.

Occlusal and Proximal Surface Decays in Bicuspids.

ILLUSTRATIONS: FIGURES 112-118.

Principal clinical features: (1.) In pit and fissure decays, the danger of undermining the mesial and distal marginal ridges by extension of caries along the dento-enamel junction, involving also the enamel of the proximal surfaces. (2.) In proximal surface cavities the clinical characters are the same as in proximal surfaces of the molars.

The positions in which pit decays occur in the bicuspids are well shown in Figure 112. The occurrence of these, independent of caries of the proximal surfaces, is not nearly as frequent as in the molars, yet a considerable number are met with. If these are treated before considerable progress has been made, they are very simple cases; but, as decay progresses, it quickly undermines the marginal ridge and is liable to weaken the enamel of the proximal surface to such an extent that this must be cut away to make a safe treatment by filling. In the illustration, Figure 112, which presents decays of the enamel in each pit and in its distal surface, it will be noted that, as these progress in the dentin, they will quickly undermine the enamel of both the marginal ridge and the proximal surface, and the enamel of these parts will be weakened by backward decay. This undermining often makes a proximo-occlusal filling necessary even though there may have been no proximal decay.

Many of the proximal decays in bicuspids begin near the marginal ridges, as in the molars. This is illustrated in the beginning of decay of the enamel in the distal surface in Figure 112. These undermine the marginal ridges and disclose the cavities early in their progress. In Figure 113 the beginning of the decay has been farther toward the gingival, and spreading on the surface of the enamel toward the occlusal has occurred. This is seen also in Figure 114 in the decay on the right side of the figure and is much more plainly seen in the photomicrograph of the same decayed area in Figure 116. The excellent photograph of the split bicuspid in Figure 117, shows the most usual points of beginning and direction of progress of these decays to

great advantage. It will be noticed that in the cavity on the left side of Figure 117, decay has already begun to undermine the enamel forming the marginal ridge, and the distance to the pulp is so great that the breakage of the marginal ridge would probably occur, disclosing the presence of the cavity before the pulp would become involved. But this tooth shows that the pulp has receded and is smaller than usual. In many cases the pulp is involved before the breakage of the marginal ridge. This brings us to the necessity of discovering these decays at an early date in their progress in order to limit the injury to the dentin by caries and prevent the exposure of the pulp. In the split bicuspid, Figure 118, there is a mesial cavity which has extended in the dentin to the exposure of the pulp before the mesial marginal ridge is broken. This shows well the extension along the dento-enamel junction under the occlusal surface of the tooth. This great extension along the dento-enamel junction and the general form of the cavity is typical of this class of cases in which the opening of the cavity remains closely covered by the proximating tooth.

Taken all together, the principal clinical differences between the proximal decays of the bicuspids and the molars are to be found in the smaller comparative size of the bicuspid in relation to the exposure of surface to the beginnings of decay. For this reason, the amount of sound tissue in proportion to carious tissue quickly becomes much less than in the molar teeth, and their successful treatment is for this reason rendered more difficult. These facts intensify the demand that closer examinations be made and filling resorted to earlier in the progress of caries in the bicuspids. If this will not allow the cutting to be made much narrower on the surface, it can be made much shallower, giving proportionally a much greater mass of healthy tissue to support fillings and to limit the danger of breakage.

The photograph from a split bicuspid, Figure 114, shows a cavity in the mesial, and also one in the distal surface and is of especial interest. The forms are fairly well outlined, showing particularly in the one on the left of the picture, that the enamel rods have not fallen out. Yet the clouding of the dentin reaches to the pulp chamber. The acid, which has percolated through the decaying enamel, has begun dissolving away the calcium salts of the dentin. This extends along the dento-enamel junction, both to the occlusal and to the gingival. In this picture the backward decay of the enamel, in the extension toward the occlusal, is particularly well shown. It is this backward decay

of the enamel which so weakens it that it often breaks away early in the progress of the decay. The decay in the mesial surface, or right-hand side of the picture, has not been well shown by the engraver, but in this, in the central area of the decay in the enamel, the enamel rods are broken down and lie in a tangled mass near the dento-enamel junction.

After the photograph of this tooth was made, the cut surface was cemented to a cover-glass, and this in turn to a grinding-disk, which was placed in the grinding machine, and a section ground thin enough for microscopic examination by transmitted light. From this, photomicrographs were made which show the carious areas in greater detail. The sides to which each belong have been preserved as they appear in the small photograph.

If the decay on the left in the photomicrograph, Figure 115, is studied, the amount of the solution of lime salts from the dentin, as it is shown at y, is easily followed. The injury to the dentin, however, extends from the point of the dentin cusp near the occlusal, down past the decay of the enamel toward the gingival. At z the outline of the backward decay of the enamel, seen in the small photograph, is quite plainly shown, but by transmitted light it is dark. A backward decay toward the gingival is not so well shown, because of some little cracking of the enamel in that region, which mars the picture. The occlusal portion of this picture is upward, as it is in all of the photomicrographs.

The decay on the right of the small picture, Figure 114, is represented in Figure 116. Although this decay has not caused enough solution of calcium salts in the dentin to show shrinkage in drying, the injury to the dentin seems to be considerable. The enamel rods are broken down in the central area, which occurred, I am persuaded, in the process of grinding, for my notes say that the surface of the enamel showed no loss of enamel rods. The grinding of the surface from which the small photograph was made, was without any protection by cementing the enamel rods together by solutions of balsam or shellac to prevent movement, and some distortion of the enamel rods on the superficial portion of the cut surface would easily be overlooked. It will be seen in the photomicrograph that many of the partially dissolved enamel rods lie in a tangled mass in the deeper parts of the cavity. The very unusual extension of the carious process in the enamel toward the occlusal at z will also be noticed here, separated partially from the principal area of decay, a flamelike tongue shoots inward from the surface and is making progress,

following directly the length of the enamel rods. This represents a new decay of enamel in the form of an extension, but beginning upon the surface. It is not a lateral extension within the tissue, but marks the spreading of microörganisms on its surface. It is well to note particularly the direction of the enamel rods along the occlusal side of the flamelike tongue of decay shooting down from z, with reference to the inclination of the enamel wall that would be required if this were prepared as a simple proximal cavity. It will be seen that this inclination of the enamel rods is too great to fill against safely, for it is in such a position that the thinness of the margin of the filling material would be insufficient to give it the necessary strength.

MISPLACEMENT OF BEGINNING PROXIMAL DECAYS.

ILLUSTRATIONS: FIGURES 119, 120.

It has been noted, in considering Figure 92, that the proximal decay upon the mesial of the bicuspid is out of the ordinary position to the lingual, passing partially around the lingual angle of the tooth. Such displacements from the normal position occur frequently on account of irregularity of the teeth bringing their surfaces together in unusual relations to each other, or some such accidental condition.

In Figure 119 a peculiar shaped cavity is presented in the mesial surface of the central incisor, having a prolongation running labio-incisally. When the tooth is seen standing alone, such form of beginning decay might seem difficult to explain, but examination of Figure 120 explains the reason for this unusual form. The relative position of the two teeth is such as to bring very near contact directly along the line which this decay has taken in the enamel, and is the local influence which has caused this peculiarity. In any case, if a tooth, a bicuspid for instance, is turned one quarter around upon its axis, so that the buccal surface, proper, becomes the mesial surface, and the lingual surface, proper, becomes the distal surface, decay, if it occurs, will start in the portion of the enamel that is in near contact with the neighboring tooth.

Therefore, we see again in this that the nature or perfection of the enamel is in no wise an element in the localization of decay on the smooth surfaces of the teeth. These unusual forms, and apparently unusual positions, of beginning caries are always traceable to some condition that serves to invite lodgment and

FIG. 119.

FIG. 120.

FIGS. 119, 120. Drawings showing an unusual form of decay in a central incisor in Figure 119, and the overlapping of the two central incisors in Figure 120, in such a way as to bring the surfaces of the teeth in very near approach in such a direction as to produce this form of beginning decay.

Fig. 121.

Fig. 121. A photomicrograph of an extensive decay of the enamel on the proximal surface of a molar. D, Dentin. E, Enamel. X, Area of decay of enamel. Y, An extension of the superficial beginning of caries gingivally further than the illustration shows. No enamel rods have fallen out. The enamel is decayed through to the dento-enamel junction and some solution of the dentin has been begun by the percolation of acid through the decayed enamel. The extension of caries of enamel gingivally is characteristic of lodgments of food between the teeth and absorption of the interproximal gum tissue.

FIG. 122.

FIG. 122. A photomicrograph of caries of the enamel on the proximal surface of a molar, with an extension gingivally. The decay from the original point of beginning has penetrated the enamel almost to the dento-enamel junction. The extension gingivally is partially separated from the principal decay. See Figure 123.

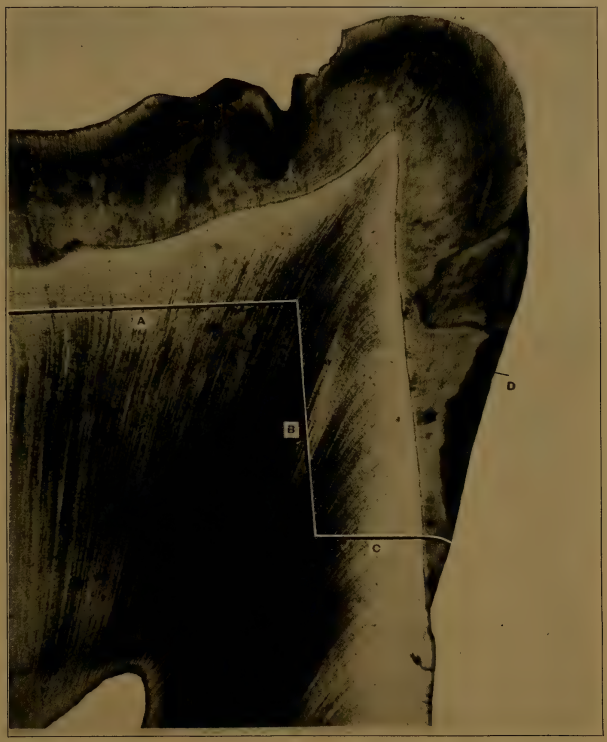

FIG. 123.

FIG. 123. Another photomicrograph from the decay shown in Figure 122, made with less amplification in order to show the relation of the decay to the pulp chamber and other parts of the tooth. It includes a little less than one-half of the mesio-distal section of the crown. In the preparation of a cavity for filling in such a case, it would be an error to cut the gingival wall at D. The true cavity lines would place the gingival wall at the line C; the axial wall on the line B; the occlusal wall of the step on the line A.

to protect colonies of microörganisms. In the examination of many teeth, such unusual positions of beginning decay are not very rare.

SECONDARY EXTENSIONS GINGIVALLY OF PROXIMAL DECAYS.

ILLUSTRATIONS: FIGURES 121, 122, 123.

In proximal surfaces another condition arises frequently that deserves especial attention on account of its great clinical importance. Figure 121 shows a large carious area of enamel at x that has just passed through the enamel and begun the solution of the calcium salts of the dentin. In this case, a secondary beginning of caries of the enamel has occurred toward the gingival at y, running farther gingivally than the illustration shows. This occurs in somewhat less breadth in a considerable number of cases on account of lodgment and retention of food between the teeth. Because of roughening of the surfaces, by the swelling of the decayed area, or because of the falling away of enamel rods in one or both of the proximating teeth, the food, instead of gliding out laterally in the normal way, will be held, and will be forced more and more onto the gum tissue as other food is forced in upon it. In this way the interproximal gum tissue will be absorbed and a pocket will be formed between the teeth that will be well enclosed by the festoons of the gum to the buccal and lingual, and by coverings of debris from washings by the saliva. Acid fermentation will become established in this pocket. The acid formed by this fermentation will be in contact with the surface of the enamel and its calcium salts will be dissolved. Another case of similar character is illustrated in Figure 122. The progress toward the gingival line is less extensive, but in depth its progress is more pronounced and it has a more evident separation from the original beginning point of decay in this surface. As in most of the decays of enamel at this stage, the swelling of the carious enamel is very apparent in the principal decayed area. There seems to be some effect upon the partially dissolved enamel rods that causes them to lengthen slightly, causing this swollen appearance. Further, when these rods are disturbed, they often collapse into a tangled mass in which they seem bent and twisted together in such a way as to suggest that they have become softened and in a degree pliable. See Figure 116. This swelling appears in a number of the photomicrographs. I do not remember that any other writer has mentioned it. In the hand grinding that I had done before this had not been

noticed, but in many of my recent grindings with the machine, in which the final thinning down of the specimen is done, with all such frail parts held together in hard balsam or shellac, it has become too prominent to be overlooked. Indeed, in the grinding by the machine, the preparation is more delicately done than heretofore and much carious tissue is saved in form that formerly was lost. This is giving a closer insight into the actual conditions existing in the beginnings of caries of enamel. The roughening of the surface of the decayed area is evidently a factor in the holding of food and the establishment of a pocket between the teeth. This is aided later by the falling out of the enamel rods and the more general roughening of the surface on that account.

Those conditions, which cause the food to lodge, become a cause of the wide secondary extension of the carious area toward the gingival line, which creates a very ugly clinical condition, and one that is too often overlooked at a time when it might be easily remedied. During the preparation of the cavity, such an extension of decay as is shown in Figures 121, 122, will show a white line of more or less thickness on the cavo-surface angle of the gingival wall, while the remainder of the enamel wall will be hard and firm. This is further illustrated in Figure 123, another photomicrograph from the same specimen as that in Figure 122, but made with less amplification in order that more of the relation of the carious areas to the tooth and its pulp chamber may be shown on the ordinary book page. In this case, if the occlusal portion of this proximal decay had extended into the dentin and the cavity had been discovered by the breaking away of the enamel at a time when the secondary extension of decay gingivally, as shown, was at its present stage, which often occurs, it would have been easy to overlook this extension and prepare the cavity with its gingival wall cut at the line D, instead of cutting the cavity to the line C. Such an error as cutting the gingival wall at D would inevitably have resulted in disaster within a short time. In practice, the only way in which to make a filling that will not soon be undermined at the gingival wall is to continue the extension until all appearance of this secondary caries of the enamel has been removed. The perfect enamel will then show the usual solid vitreous appearance at the cavo-surface angle of the gingival wall. Then the contact point must be so formed and the filling so finished as to later on prevent the leakage of food into the interproximal space. Afterward, the regrowth of the interproximal gum tissue should be encouraged

by local stimulants and the case kept under observation in the effort to have it refill the interproximal space.

Any condition which allows food to leak into the interproximal space, be held and forced onto the gum tissue, will cause the absorption of the gum tissue and result in the formation of a pocket. In time, one of two things is certain to happen: (1) acid fermentation will become established in the pocket and decay will occur farther toward the gingival line, or (2) putrefactive decomposition will become established, and finally disease of the peridental membrane will result. Careful clinical study has shown conclusively that much the greater number of the decays met with in practice that extend far toward the gingival line, or past it into the cementum, have occurred in this way. It is true, however, that a considerable proportion of these have occurred in what may be called the more normal way by the spread of decay along the dento-enamel junction and backward decay of the enamel. This later can occur only in the badly neglected cases.

The crowding of food between the teeth after the placing of so-called contour fillings in the earlier days of cohesive gold work was the cause of widespread loss of fillings by undermining by decay at the gingival margin. The former employment of the separating file as it had been developed in the use of non-cohesive gold was continued for the finishing of cohesive gold fillings. Flat contacts were made and the forms of proximal surfaces were left otherwise in imperfect form. There had not been that close study of tooth forms which enabled men to copy them with accuracy, or to appreciate the correctness of forms of interproximal contacts; neither did they have suitable instruments. It is only by the complete relegation of the separating file to past history, the study of the best natural forms of interproximal contacts and their function in the protection of the interproximal spaces, the copying of these in the shaping of proximal surfaces of fillings, which are made to restore the full mesio-distal breadth of the teeth, that this difficulty in the treatment of caries of proximal surfaces is being overcome. Decays recurring from these causes are especially difficult of treatment, often requiring the removal of a filling previously made, in order to reach them from the occlusal surface. They are also complicated with great difficulties in getting the rubber dam far enough to the gingival to protect them from moisture.

Therefore, in practice, a complaint of pain being produced by food lodgments, or of food being held between the teeth in

the chewing of meats or other stringy foods, should receive immediate attention, the cause found and the condition remedied. It may occur from a number of causes besides the beginning of caries, and will occasionally be found in one, two or more teeth, in mouths in which no caries has previously occurred. The proximal contacts may be bad from faulty forms of the teeth themselves, they may have become bad from movements of the teeth after extractions, the contacts may have become flattened by interproximal wear, but oftenest of all, they have become bad because of beginning of proximal decay. I may say that, personally, I have done no other thing for my patients that has elicited keener expressions of appreciation than the correction of this class of evils. If the dentists of this country would unite in looking closely after these conditions and be careful in their correction, it would add greatly to the comfort and welfare of their communities, save thousands of teeth for useful service and enhance the usefulness of dentistry.

INJURIES BY INTERPROXIMAL WEAR.

ILLUSTRATIONS: FIGURES 124-128.

The clinical consideration of caries of the proximal surfaces of the bicuspids and molars should not be passed without more special mention of the injuries that result from interproximal wear and the flattening of the contact points from this cause; though it will be again presented from the technical view in the second volume. The general principles governing the lodgment of food debris between the teeth have been given under the last heading, to which the reader is referred, in which interproximal wear of the contact points was mentioned as one of the causes.

A certain indefinite amount of wear of the mutual points of proximal contact between the teeth as they stand in the arch, must be regarded as normal. Almost any tooth extracted after the age of twenty-five or thirty years will show a facet of wear on its point of contact with its fellow. A number of measurements of these give an average of a loss of about one centimeter in the length of the arch from this cause when measured on the labial and buccal surfaces of the teeth around the arch from the mesio-buccal cusp of one third molar to the other at the age of forty years. This wear increases as the person grows older. When this wear is fairly even in its distribution among the several teeth, it can not be regarded as abnormal, nor is it a cause of material injury. Such wear does not loosen the normal

Fig. 124.

Fig. 125.

Fig. 126.

Fig. 127.

Fig. 128.

Figs. 124-128. This group of five teeth, all of which were extracted by the author because of neglected disease of the peridental membranes, caused by the crowding of food between the proximal surfaces, flattened by interproximal wear. These should have been protected at the proper time by building prominent contacts for the cure of the difficulty. Figures 127, 128, illustrate the position in which decay most usually occurs in these cases.

pressure of the contact of tooth with tooth as they stand in the arch in any degree. In the balance of forces which confine the teeth in normal form and occlusion in the arch, there is a moderate but continuous pressure exerted to hold them firmly one against the other, which, when conditions remain normal, continues through life. This is much more than sufficient to take up any loss of length of the arch around its curve that may be occasioned by the wear of the contact points. This is often shown by the quickness with which the teeth anywhere in the arch will close together when a contact point has been lost by reason of caries or the reduction of an intervening space where a tooth has been removed. This wear is produced by the slight movement of the teeth in their alveoli allowed by the peridental membrane. It is not equal in all parts of the mouth, but is greatest among those teeth which do the heavier work in chewing food, especially the second bicuspid and the first and second molars. In these teeth it is frequently excessive. The five first molars, photographs of which illustrate this subject, were each removed by the author because of injury done to their peridental membranes by the food which was held by the flattened surfaces and crowded against the interproximal gum tissue. The flat facets shown in the photographs exhibit the amount of interproximal wear that may be expected to occur frequently in persons fifty to sixty years old, who have made good use of their teeth. Many cases may be observed that have become worn as much as these, or nearly so, in which no special harm has resulted, and they require no attention. But in a certain number of these, food that is unusually tough and stringy will some time be forced between the teeth and not be removed. At subsequent meals more will be forced in, until finally the pressure of the contact will be loosened and remain so. Then trouble has begun in earnest, which, if not relieved promptly, will certainly result in disaster. Within my personal observation, certain persons have manifested a remarkable unconcern as to this condition, claiming that they had never experienced any uneasiness whatever, even when large amounts of gum tissue had been destroyed by the pressure of food debris. Such cases are often hopeless when first seen. But when the dentist discovers such cases in time to act successfully, he should express the necessity for treatment by proceeding at once to do that which is necessary. Such a course will save his patient from the loss of the teeth concerned. Others, and much the greater number, are in constant trouble from the beginning of the lodgments

and gladly accept anything that promises relief. The number of persons who have complained that they have been unable to obtain relief when applying to their dentist indicates that the body of the profession have been slow to realize the necessity for treatment, or to see the way to make it successful. As said in the previous article, one of two things is sure to result if this continues: (1) acid fermentation will become established in the pocket formed between the teeth as a result of the absorption of the interproximal gum tissue, by the pressure of the accumulations, and caries beginning near the gingival line, as shown in Figures 127, 128, will result; or (2), putrefactive decomposition will occur, resulting in disease of the peridental membrane. In Figure 124 a considerable absorption is shown on the side of the mesial root of the lower molar, which seems to have been caused by the continued irritation of the peridental membrane, a thing that has been observed in a considerable number of such cases. The common habit of dentists of throwing extracted teeth into the waste-basket or elsewhere without examination of the condition of their roots, is accountable for the slowness of the development of our knowledge of the effect of pathological conditions upon the peridental membranes and the hard tissues which they invest. In this illustration, Figure 124, the surface flattened by wear is very broad. In Figure 125 the enamel has been worn entirely through, exposing the dentin. In Figure 126 a decay of the enamel had begun near the contact point but had ceased to progress because of some favorable change of conditions. This has become blackened and the facet of wear has later spread over it. The location of the decays that have begun in Figures 127, 128, is typical of the beginnings of decay in these conditions and speak for themselves as to the difficulty of treatment. From every point of view cases of this class call for immediate, careful consideration and treatment in the very early stages of their progress, or just so soon as it is noticed that there is trouble that seems to persist. Only one thing promises relief, and, fortunately, has proven very effective when carefully done. This is to cut a cavity in one of the worn teeth that shall fully include the worn area, make a good and sufficient separation of the teeth and build out a prominent contact that will hold the surfaces sufficiently apart and prevent further leakage of food into the interproximal space. This treatment is given in detail in the volume on technical procedures in filling teeth.

Fig. 129.

Fig. 130.

Fig. 129. A blackened spot on the mesial surface of a central incisor caused by a beginning decay of the enamel, which was stopped by a change of conditions, and afterward became very dark. It shows the most common position of beginning of decay in these surfaces.

Fig. 130. An open cavity in the mesial surface of a central incisor with a superficial extension of decay running away from it, toward the linguo-gingival angle of the surface. A similar superficial whitening leads away to the labio-gingival angle, which was lost in the high light in photographing.

Proximal Surface Decays in Incisors and Cuspids.

ILLUSTRATIONS: FIGURES 78-81, 129-133.

Principal clinical features: (1.) The V-shaped form of the proximal surfaces. (2.) The necessity that cavities be approached through the labial or lingual embrasures, differing from the approach through the occlusal surface in the molars and bicuspids. (3.) The curvature of the surface at the usual point of initial attack carries extensions of decay along the dento-enamel junction quickly to the undermining of the lingual or labial enamel plates, or often both. (4.) The frequent danger of the spread of decay incisally along the dento-enamel junction, destroying the support of the incisal angle. (5.) The tendency to spreading of caries to the linguo-gingival and labio-gingival angles of the surface, especially after fillings have been made. (6.) The triangular forms of prepared cavities, with extensions at the labio-gingival and linguo-gingival angles only, instead of the square-cut cavities in proximal surfaces of the bicuspids and molars. (7.) The necessity for forming incisal anchorages of a form not used elsewhere. (8.) The greater necessity for esthetic considerations in all parts of the treatment, and especially in the preservation of the stronger parts of undermined labial enamel. (9.) The great danger of injury to the attachment of the soft tissues to the tooth at the crest of the arch of the gingival line on the mesial and distal surfaces in the use of ligatures.

The two groups of Figures, 78-81, 129-133, taken together, present a progression from the very early beginnings of caries in the enamel in proximal surfaces of incisors and cuspids to a very considerable invasion of the dentin. They give a fair view of the usual conditions found, including the place of beginning and the manner and direction of the invasion. Particular attention should be given to the arch of the gingival line as it passes from labial to lingual across the proximal surfaces. This is well shown in Figures 129, 130, which exhibit plainly the danger of serious damage to the attachment of the soft tissue to the tooth at the crest of the arch of the gingival line by tying ligatures tightly and forcing them to the gingival line on the labial and lingual surfaces. This danger is found particularly with the incisors and cuspids, and great damage is frequently done by inattention to this point.

Figure 129 shows particularly well the most common position of the beginning caries on the mesial surfaces of the incisors. It is sometimes a little closer to the incisal angle and sometimes a little farther away, though it does not often vary very much from the point shown. The spot shown is a beginning decay which had penetrated the enamel but little apparently, and, having been stopped by a change of conditions, became very dark. Figure 130 was intended to show the broad spreading of caries which sometimes occurs on the proximal surfaces of these teeth. This is plainly shown on the lingual in the rounded tongue of superficial decay extending away from the dark, open cavity toward the linguo-gingival angle of the surface. A somewhat similar extension toward the labio-gingival angle was apparent, but the high light in the photograph has hidden that point. Such extensions as that seen upon the lingual in this photograph are particularly liable to occur in very susceptible persons after fillings have been made, unless extensions of the angles of cavities have been made to include the area of danger. Otherwise, this case presents a wide-open cavity in which the undermined enamel has broken away most toward the lingual surface. The penetration of dentin and its direction of progress is progressively shown in Figures 131, 132, 133. In the first of these, the enamel rods have fallen out, and the spreading of decay along the dento-enamel junction is in progress. The faint hyaline zone is seen reaching almost to the pulp chamber. This decay is rather nearer the gingival line than usual, because the strong rounding of the distal surface inciso-gingivally placed the contact point unusually far from the incisal. We see in this that the form of the particular tooth plays its rôle in the particular locality of the point of attack in the enamel by caries. The next photograph, showing decay in the mesial surface of a cuspid, Figure 132, gives a false impression in that it shows the enamel rods in position, while, in fact, the cut is slightly to one side of a small area from which they had fallen out, admitting microörganisms to the dentin. The same spreading along the dento-enamel junction is present, though in less degree than the average of cases. An examination of this case will show the liability of extension along the dento-enamel junction undermining the incisal angle before an exposure of the pulp would occur, a thing that frequently happens to the incisors when there is a lack of watchfulness of the progress of decay. This was not a young tooth, as shown by the wear of the cusp, which has exposed an area of dentin. A trace of a hyaline zone is

FIG. 131.

FIG. 132.

FIG. 131. A beginning decay in the distal surface of a lateral incisor from which the enamel rods are falling away and progress of decay has begun in the dentin. A delicate hyaline area stretches away toward the pulp chamber.

FIG. 132. A decay in a worn cuspid that has made greater progress. This picture is liable to give a false impression for the reason that the cut is a little to the side of the central area and shows the enamel penetrated with the enamel rods still in position, when, in fact, the cavity was open through the enamel.

Fig. 133.

Fig. 133. A more considerable decay in the distal surface of a central incisor in which the undermining of the enamel is less than usual. In such a case the labial or lingual plate of the enamel may be found undermined.

seen streaking away to the pulp chamber from that as well. These shadows occur in abrasions the same as in caries, but usually are not so prominent. Whatever else these zones of shadow may be, they express a decisive injury to the dentinal fibrils. A still more extended invasion of dentin is photographed in Figure 133. This is not an inordinately large cavity, but one that is easily managed in filling operations. However, even in this, one is liable to find the labial or lingual enamel plates considerably undermined by extensions of decay along the dento-enamel junction. It should be noted particularly that many of the incisors are thin labio-lingually at the point first invaded by decay, and a comparatively moderate extension along the dento-enamel junction may cause such injury to the labial enamel plate as to make a decisive esthetic blemish. This can be avoided only by careful watchfulness over these teeth to see that caries in them receives early attention.

Material for the illustration of this class of decays is exceedingly difficult to obtain and much dependent upon accident. This is exhibited in Figure 79. In this, decay had practically destroyed the central incisor by exposure of the pulp before the apex of the root had closed sufficiently to permit of a root filling. The case exhibits in a striking manner the breadth mesio-distally of the pulp chamber at this tender age of the child, the proximity to the pulp of the usual points of the beginning of caries, the small amount of dentin through which decay must penetrate to expose the pulp, and strongly suggests the watchfulness that should be had over such teeth in families highly susceptible to caries. This is an ugly thing to happen, but it gave an excellent picture of beginning caries and the form of the penetration of enamel in the distal surface of the tooth.

Gingival Third Decays in Labial and Buccal Surfaces.

ILLUSTRATIONS: FIGURES 134-141.

Principal clinical features: (1.) The earliest beginning of decay is a line of whitening of the enamel running mesio-distally near the free margin of the gum in the middle third of the surface mesio-distally. (2.) The spreading of the decay on the surface of the enamel is usually confined closely to extensions mesially and distally toward the angles of the tooth, following the curve of the free border of the gum. (3.) In cases of neglect of cleanliness, and especially in neglect of the use of the teeth in chewing food, there may be extensions occlusally and also across the angles of the teeth to connect with proximal

decays on the mesial and distal surfaces. (4.) In many cases of this class of caries the disposition is seen to spread quickly from tooth to tooth, or to attack a number of teeth at the same time. (5.) Yields to prophylactic treatment by the patient, when properly instructed, more readily than any other class of decay. (6.) Protection from recurrence of decay after making fillings is had only by extension of cavities nearly to the angles of the teeth in the ordinary cases. (7.) Attacks fewer persons than other classes of caries, but is often very destructive when a beginning is once made. (8.) The most general rule is that gingival third decays occur later in the life of the person than the other classes, but attacks in early youth are not very infrequent.

Gingival third decays in the labial or buccal surfaces, or in both together, have been much dreaded by dentists because of persistent recurrence to the mesial and the distal of the margins of fillings, or to the gingival when these have been made for young people. This difficulty has arisen from a failure to study the clinical characters and conditions of occurrence closely enough to properly direct the treatment for its eradication and cure. If the conditions which have given rise to the beginning of the decay are not materially modified by prophylactic measures, or spontaneous cessation, the disposition to spread mesially and distally is one of its most persistent characters. Nothing less than the extension of cavities very nearly to the angles of the teeth attacked, will be effective.

Figure 134 is a photograph of a cuspid with a gingival third decay which began before the tooth fully reached its position in the arch, or when the crown had yet more than one third of its length covered by the free margin of the gum. Decay spread rapidly across the surface mesially and distally from the beginning point and became established in the dentin. In the process of growth, more of the crown of the tooth was uncovered to the gingival of this decay, the conditions which caused the first beginning remaining or recurring. The result is another whitened band of enamel, a new beginning of decay, to the gingival of the first. This is what may be expected to occur when such decays are treated by filling, when they occur in young persons, unless the free margin of the gum is pushed well away and the cavity margin extended so far to the gingival as to include the new area of liability that must become exposed. In early youth the sufficient persistence of attention to prophylactic measures for the prevention of such extensions is not likely to be so well kept up as to be a very safe protection.

Fig. 134.

Fig. 135.

Fig. 134. A photograph of a cuspid with a decay across its labial surface. There is a decayed area running across the surface mesio-distally that has penetrated the enamel and is making progress in the dentin. Undermined enamel has been breaking away, leaving more or less jagged margins. The beginning of this decay occurred when the free margin of the gum was about at the gingival margin of this carious area, and covered the portion of the tooth to the gingival of it. As the tooth protruded farther through the gums, more of the enamel became exposed and the conditions producing decay continuing, or recurring, another band of whitened enamel — beginning decay — has occurred to the gingival of the first.

Fig. 135. Another cuspid, similar to that in Figure 134, in which a decay, beginning in the enamel when the tooth was still half covered with gum tissue, has become fixed in the dentin and later produced a round opening by the breaking away of undermined enamel. When the tooth had protruded farther through the gum and the conditions causing the beginning of decay in the enamel having passed away, this appeared much removed from the free border of the gum.

The most essential condition for the occurrence of decay of this class is a saliva favoring certain kinds of deposits upon the teeth which will cover in attached colonies of microörganisms in such a way as to protect the acids formed from free dissipation in the general oral secretions. This may be such a condition as will enable microörganisms to protect themselves by the formation of gelatinous plaques (zoöglea aggregations), or possibly by other kinds of deposits from the saliva that will form a membrane-like covering that will afford a sufficient protection. It is a notable fact that where any kind of deposits are found upon the teeth, they are first to be seen on the buccal surfaces at the points where gingival third decays begin. It is not any and every kind of aggregation of filth on the surfaces of the teeth that gives rise to decay. Indeed, some forms of filth seem to prohibit decay instead of causing it. Some of the filthiest of mouths have no caries, and in some cases where caries has been in progress it seems to have been actually stopped by extreme filthiness in the same way as decay not very infrequently is stopped in certain cavities by the establishment of putrefactive decomposition in their interior, as has been mentioned. Neither will loose aggregations of saprophytic microörganisms, or of leptothrix buccalis, or the leptothrix of Vignon, or other harmless varieties which may form thick masses over the teeth, through which water will run as freely as through a sieve, have any influence favoring the production of caries. The covering must be of a kind that will protect from free washings by the fluids of the mouth, and in and under which the caries fungi will grow and produce acid fermentation. This may be so thin and so transparent that the teeth may appear clean and yet afford an effective protection against the too free dissipation of the acid products of fermentation. It has become evident enough from clinical observation that the conditions which favor the formation of these plaques is one that is liable to be intermittent. It comes and goes. Decays of the gingival third of buccal and labial surfaces are especially liable to start, to stop, and to start again. Their exposed situation renders them more sensitive to fluctuations of conditions than decays situated in protected localities. This is said of decays of the enamel in which enamel rods have not fallen away exposing the dentin to invasion by microörganisms. Once caries is implanted within the dentin, it will most generally persist, even when there is complete immunity to the beginnings of caries on the enamel.

Figure 135 shows a decay, situated centrally in the labial

surface of a cuspid, which has progressed in the dentin, undermining the enamel, which, by breakage, has now formed a round opening. At a time when this tooth was taking its place in the arch and was uncovered by the gum tissue, only to about that point, a decay penetrated the enamel and became seated in the dentin. The particular form of the beginning in the enamel is now lost by breakage from backward decay, but we know from many observations of such cases that it was in a line across the central portion of the present dark area. As the tooth protruded farther through the gum, the conditions causing the beginning of decay in the enamel passed away and did not return, but the decay established in the dentin continued. Had the original beginning failed, ever so little, to penetrate the enamel and admit microörganisms to the dentin, the progress would have ceased entirely. Later, a blackened blemish of the enamel would have remained to show where decay had begun. Many of these may be found in any box of extracted teeth.

A rare position of decay on the lingual surface of a cuspid is shown in Figure 136, which, from what is left of the lingual surface, seems to have begun as a pit decay, beginning, probably, in pits at the junction of the lingual developmental grooves with the linguo-gingival groove or pits along the lines of these. (See "Descriptive Anatomy of the Human Teeth"— Black, Figures 5 and 20.) These grooves are unusually prominent, and one undecayed pit remains in view. The case shows how decays may sometimes begin in the most unusual positions and how difficult it may become to define the local conditions causing them after the immediate surroundings have been destroyed.

The gingival third decays in the buccal surfaces of the bicuspids and molars are not materially different from labial surface decays. They exhibit similar characters in both their beginning and in their disposition to spread along the gum margin mesially and distally. In the photograph of the upper molar, Figure 137, two considerable areas of loss of enamel rods appear in an area of rather faint whitening stretching across the buccal surface. Figures 138, 139, photographs of a third molar, show the wild race of destruction that sometimes befalls these teeth when caries is allowed to go on unchecked by any sort of cleaning. For these illustrations, the cementum has been tinged with a selective anilin stain to show the gingival line distinctly in order to bring prominently into view that portion of the enamel covered by the free border of the gum, illustrating its protection from the beginnings of caries. This

Fig. 136.

Fig. 136. A photograph of the lingual surface of a cuspid with a broad open cavity. From what remains of the surface of the tooth, it is seen that there is an unusually prominent lingual groove on the left side of the picture, in the line of which a small dark pit appears. This indicates that there were other and deeper pits in this surface in which decay in this unusual position started. The case illustrates the fact that often decays in unusual positions have occurred because of some imperfection which has furnished a place of lodgment, and the imperfection has been wholly destroyed by the decay, leaving no sign explaining the cause.

FIG. 137.

FIG. 137. A molar showing two beginning points of decay on the buccal surface. A whitened line running mesio-distally was apparent on this tooth, but the engraver failed to show it.

FIG. 108

FIG. 109

FIGS. 108, 109. Two photographs of a lower molar tooth, in which caries proceeding from a buccal surface decay and a mesial surface decay have met across the angle. Figure 108 shows the wide range of the decay of the buccal surface. Figure 109 shows the mesial surface decay as a broad, whitened area, from which no enamel rods have fallen away. This meets the buccal surface decay across the angle of the tooth. This picture also shows the breaking away of the undermined enamel of the buccal surface to advantage. The cementum of this tooth was stained selectively with an anilin dye to bring the gingival line into prominence, showing the influence of the free border of the gum in protecting the enamel from beginnings of caries.



Fig. 140.

Fig. 140. A neglected decay of the buccal surface of a lower molar, showing the more common form these decays assume.

Fig. 141.

Fig. 141. A photograph of an upper first molar that was misplaced toward the cheek and but partially erupted. When removed, decay of the enamel had begun over all of the exposed surface.

FIG. 142.

FIG. 143.

FIG. 144.



FIG. 145.

FIGS. 142-145 inclusive. Photographs of a lower first molar with beginning decay completely encircling the crown, following closely the free margin of the gum in every part. Figure 142, the mesial surface; Figure 143, the buccal surface; Figure 144, the distal surface; Figure 145, the lingual surface.

appears to best advantage in Figure 138. In Figure 139 it is seen that the decays beginning in the mesial and the buccal surfaces have become connected across the mesio-buccal angle of the tooth by a comparatively narrow neck. The pictures illustrate the riotous progress sometimes seen in buccal decays under exceptionally unfavorable conditions. Figure 140 exhibits another neglected buccal decay, which is a more ordinary example of the form and extent of these when they are left to take their own course. It will be noticed that this has not passed the angles of the tooth. These decays will, of course, burrow along the dento-enamel junction, the same as others, and in that way destroy the enamel by backward decay to the gingival line, allowing the free margin of the gum to fall into the cavity.

Figure 141, a photograph of an upper third molar, presents an anomalous condition. In coming into position it deviated backward and to the buccal from the normal, and seemed to have stood for some time with but a part of its crown through the gum. When removed, the whole of its exposed surface was whitened by beginning decay.

Spreading of Decay Around the Teeth.

ILLUSTRATIONS: FIGURES 142-145.

In what has been written thus far of dental caries, the idea has been developed that, when decay occurs on proximal surfaces, the tendency to superficial spreading is from the starting point both buccally and lingually toward the angles of the teeth. Also, that, when caries begins on the buccal surfaces, the tendency is to spread mesially and distally from the place of beginning toward the angles of the teeth. This is true of caries in these positions in all of the teeth, but more especially of the bicuspids and molars. A fewer number occur in the front teeth as well. It has also been stated that in a few instances under specially unfavorable conditions this decay crosses the angles of the teeth and the proximal and buccal decays join each other. This crossing of the angles of the teeth is the rarest of all of the spreading. It then requires only that decay shall also occur similarly on the lingual surfaces in order to complete the circle of the tooth. This, though much more rare, occurs also. This appears in the case of the lower second molar tooth, four photographs of which are shown in Figures 142-145, inclusive. Figure 142 shows the mesial surface with a broad, whitened area of carious enamel stretching from angle to angle, in which the

enamel rods have begun to fall away at one point only. Figure 143 is a photograph of the buccal surface with the whitened area also stretching from angle to angle, the shadow obscuring a small part at the mesial angle. The distal surface, Figure 144, shows dark, but the decay is apparent, and on the buccal surface, as seen in this photograph, the whitened line of carious enamel is seen to advantage as it rounds to the occlusal following the free margin of the gum to join the distal surface decay. Finally, the whitened decay on the lingual surface, Figure 145, is seen streaking away from the decay in the mesial surface in a curved line, which is lost in shadow as it approaches the distal angle, completing the circle of the tooth.

The pictures of this series are the final illustrations for the explanation of the tendencies to spreading superficially on the surface of the enamel and the direction of that spreading as one of the principal clinical features of caries of the teeth, which every dentist should fully understand and appreciate as his guide in the preparation of cavities for the prevention of recurrence of decay about the margins of fillings. Every one should understand distinctly that the spreading *on the surface of the enamel* is a thing entirely different and apart from spreading along the dento-enamel junction and destruction of the enamel by backward decay, together with the general invasion of and destruction of dentin by caries. This latter spreads in every direction from the point of penetration of the enamel, having no respect whatever for any particular surface or any of the angles of the teeth. The spreading along the dento-enamel junction this way or that has no clinical significance in connection with the recurrence of caries about fillings. This invasion may produce broad cavities, cavities of awkward shapes, may weaken the tooth by the destruction of dentin, and, in these and other ways, has its special points of clinical importance. But this is all secondary, occurring only after the enamel is broken. The clinical importance of a full appreciation of the superficial spreading of caries on the enamel has to do especially with the prognosis, with the probable future of every case individually, and the rational management of the teeth of each person under our care. On the details of this management, the success or failure will depend more than all else, supposing always that the details of manipulation, as this may be planned, be skillfully executed. Together with all of this, judgment must be stimulated and quickened by a careful study of the conditions of immunity and susceptibility to dental caries.

SYSTEMIC CONDITIONS.

ILLUSTRATIONS: FIGURES 146-158.

In what has been presented thus far, the immediate active cause of dental caries only has been mentioned, namely, the acid produced at the spot by growths of microörganisms. This presentation would be incomplete without the mention of other factors. While caries of the teeth is the most prevalent disease known to man, those in dental practice who have not made a careful study of the teeth of persons who have no need for dental operations perhaps do not realize how many are immune to caries of the teeth. Many grow up from childhood and pass on to old age, without ever having a carious tooth. These persons are aways to be found, if we look for them.

In the mouths of these persons the same microörganisms are found growing, and growing as abundantly, as in the mouths of persons who are very susceptible to caries. In an examination of the fluids of the mouth in these persons, it is also found that the saliva is as acid, as shown by tests with litmus paper, as in persons who have caries of the teeth. Cultures of microorganisms from those immune persons have been made over and over again, and it has been found that these microörganisms are of the same character and species and produce the same results in culture media as do microörganisms taken from the mouths of those who are very susceptible to caries. Some of these persons have been followed for years, occasional examinations and cultivations being made, so as to leave no possible doubt as to the general facts. Therefore, there is something lying over beyond the active growth of microörganisms and acid formation by them, controlling caries of the teeth. We have, therefore, persons who are predisposed to caries of the teeth and persons who are immune to caries of the teeth.

A predisposition to disease is generally considered to be a condition of the body juices and cells which renders the person liable to that particular disease. We do not always know in what that condition consists, but, from the developments thus far, we know it to be dependent upon some material form or combination of matter. We do not know this now of all diseases, but we do know it of some. Bacteriologists and chemists are succeeding in demonstrating the material nature of the causes of disease by finding alexins, antitoxins, etc., and the conditions in which these are produced and in which they are not produced.

An antitoxin will prevent persons taking a certain disease. For instance, the antitoxin of diphtheria, if properly applied in time during a diphtheria epidemic, will prevent children from taking diphtheria. It acts as a control. Here we are introducing into the blood a material, or combination of matter, which controls or prevents the development of disease. So many of these have now been proved as to give the strongest possible evidence that all of them are material. We go through the process of vaccination to produce a material condition in our own bodies that will prevent us from taking smallpox. An antitoxin is produced in the blood, in the juices in the tissues of our bodies, which is antagonistic to the disease known as smallpox. In these ways we are learning to control a number of the most destructive diseases.

Disease is also said to be hereditary. Tuberculosis has been reputed to be intensely hereditary. That condition depends upon some material element in the body; just what this is, we may not know now. A person is not born with tuberculosis; it is not transmissible from parent to child, but the child is born with a material constitution of body which renders it particularly liable to contract the disease, but it will not have tuberculosis unless exposed to the tuberculosis infection; but it contracts it more readily than other people. There is that element in the body juices and tissues which enables that particular microörganism to grow more freely or produce more injury than in other persons. That is what constitutes a hereditary predisposition to disease.

We find in certain families a hereditary predisposition to caries of the teeth that is strongly marked. If a family of children is presented for treatment and it is found that the father or mother, or both, have suffered severely in early youth from caries of the teeth, we may be reasonably sure that the children will suffer likewise. We find this almost universally true of families. Not only this, but we find in very many instances that the first beginning and the order of progress will be in the same teeth, and otherwise similar in character and form. I have followed these peculiarities now through four generations of persons, and find these particular characteristics to be hereditary. There are certain conditions, however, that seem to influence these hereditary peculiarities in a very marked degree. It is noted perhaps most in those families that come from Europe and settle in America. In these, where the parents are immune, or very nearly immune, to caries of the teeth, we find them pre-

senting us with children who are very susceptible to caries. There seems to have been some change brought about in the change of climate or conditions under which they live. The reverse of this has been noted in a few instances. Also, it has been noted that parents who have come to the city from the country and who did not suffer much from caries, present us children reared in the city who suffer greatly from caries. Here again a change in the mode of living seems to have influenced the hereditary factor. These changes are quite frequent.

The predisposition to caries is much stronger in youth and tends to disappear as persons arrive at mature age. Indeed, caries of the teeth is a disease of youth rather than of adult age, for it is now found, after much careful observation on this point, that if caries of the teeth occurring in youth is well and successfully managed, very little caries will occur in after life in the majority of persons. Cases of persistence, however, of the beginnings of caries at new points are sufficiently plentiful; and, also, cases are frequently occurring where persons have been immune from caries for many years, and suddenly we find their teeth decaying very badly, showing that there has been a marked change in the predisposition to this disease.

Again in pregnant women there is often a renewal of the conditions giving rise to caries of the teeth that are apt to continue also during the period of lactation. It has happened that girls who have grown up under the best of care and arrived at adult age with many fillings, perhaps, but with teeth in good condition and showing unmistakable signs of immunity to decay, have married, and, during their first pregnancy, developed a considerable number of new cavities in which decay progressed rapidly. This recurrence of susceptibility is not at all uncommon, and marks a change in bodily conditions with consequent changes in the oral secretions, favoring the development of caries of the teeth.

The fact that caries of the teeth is more prevalent in children than in adults, conforms with what is known of many other diseases. We have a whole list of diseases that are peculiar to children, as measles, chicken-pox, diphtheria, whooping-cough, scarlet fever, etc. As persons arrive at adult age, the predisposition to these diseases passes away, or immunity comes; and this is so complete that it is rare to find an adult person suffering from this class of diseases. They are practically confined to children.

Generally also they are self-limiting diseases. This term

"self-limiting" is applied to those diseases which run a specific course and, if the patient has withstood the attack, tend to recovery at about a certain period. In all of these, it is found that there has been a change in the blood, which renders the person immune, and this is known as the development of an antitoxin, which remains more or less permanent in the blood. In some of the diseases it seems to become a permanent fixture, as in smallpox. In others, it disappears after a time more or less completely, and the person again becomes susceptible. In this way, children may have scarlet fever and some other of the children's diseases more than once before they become permanently immune. In other cases, susceptibility to disease seems to go and come. At one time a person exposed to a contagious disease apparently under all conditions that would favor its development, goes free. The same person at other times, with probably other conditions of the body juices and cells, will take the disease readily under otherwise similar conditions. Most of the microbic diseases have some one or more of the peculiarities that have been mentioned, but there are some that are not in any wise self-limited. Tuberculosis is one of these. Although purely a microbic disease, there seems to be no self-limiting effect.

Something similar to the changes that happen in susceptibility and immunity to other diseases must occur in caries of the teeth, for to-day it is only upon this ground that we can explain the conditions of susceptibility and immunity that are so prominently before us. Formerly, the susceptibility or immunity of the teeth to decay was differently explained. It was supposed that hardness or softness of the teeth, the amount of calcium salts they contained, was in a large degree the controlling factor, and under that supposition, when the teeth of children were seen to be decaying badly, the interpretation was that the teeth were soft or poorly calcified. If the child grew up without decay of the teeth, the interpretation was that the teeth were hard and firm and for that reason did not decay. It was on this ground that the effort was made to explain the variations of susceptibility and immunity of which we have spoken.

Physical Characters of the Teeth.

The idea that some teeth are hard and some teeth are soft, grew up in the minds of the dental profession and of the laity many years ago, and this was generally regarded as a fixed fact.

These differences were supposed to be considerable, and caries was supposed to be severe in teeth that were very soft.

The fact is, that heretofore, when it was discovered that the teeth of an individual were decaying very rapidly, the interpretation was that the teeth were poorly calcified and were soft. If, after careful treatment, little or no decay occurred, it was supposed that the teeth had become hard and firm. Again, if a person had arrived at maturity with little or no decay of the teeth and later it was discovered that the teeth were decaying very badly, the interpretation was that, while the teeth had been very good in their structure, something had happened to cause them to become soft, and therefore they decayed badly. In this, the observation of clinical facts has been correctly reported. Many persons have grown to maturity without decay of the teeth and afterward their teeth have decayed very badly. It was quite generally held that, during pregnancy and lactation, the teeth of the mother were robbed of calcium salts to build up the bones of the fetus. This was because of the general observation that during such periods the teeth of women suffer more from caries than during other periods. These observations were shown to be correct by the testimony of many observers, and lines of treatment were undertaken for the correction of the supposed loss of calcium salts in the teeth. A large proportion of people who have decay in their youth, will, if that decay is well cared for, cease to have much decay later in life. This gave rise to the general opinion that the teeth were inclined to become hard with advancing age. These observations were carried on and discussed more or less for years, serving to fix the interpretation mentioned in the minds of both the dentists and the people. In fact, there seems to have been no question as to the correctness of the interpretation.

In 1895 I published a series of studies (*Dental Cosmos,* Volume 37, page 353) which were undertaken to determine the facts as to the differences in the physical properties of the teeth with reference to hardness and softness, as represented by the percentage of calcium salts in the dentin, and the relation this held to caries. The results of this investigation are given in great detail, but for our purpose very little of it need be repeated. The results surprised myself as much as they surprised others, for it was found that there were no differences of consequence. I give here a summary of that investigation, which will show the actual facts and also that the interpretation of soft teeth and hard teeth, as that interpretation then stood in the minds

General Summary of Results of Physical Examinations of the Teeth.

	No. of cases.	Average Age.	No. of Teeth.	Specific Gravity.	Per cent of water.	Per cent of calcium salts.	Per cent of organic matter.
Average for total number of teeth	111	32.33	268	2.092	11.06	63.54	25.36
The highest percentage	.....	.....	.....	2.133	13.56	65.75	27.59
The lowest percentage	.....	.....	.....	2.036	9.32	61.08	23.26
Greatest variation	.....	.....	.....	.097	4.24	4.67	4.33
Average for persons under 15 years old	11	11.	13	2.066	11.89	62.26	25.92
Average for persons 15 years old and under 20	8	17.	9	2.080	11.46	63.18	25.33
Average for persons 20 years old and under 25	20	21.55	48	2.081	11.47	63.43	25.23
Average for persons 25 years old and under 30	15	25.93	43	2.086	11.27	63.44	25.28
Average for persons 30 years old and under 40	26	33.	72	2.092	10.84	63.42	25.66
Average for persons 40 years old and under 50	12	42.66	38	2.094	10.91	63.73	25.34
Average for persons 50 years old and under 60	10	53.	19	2.105	10.85	63.83	25.29
Average for persons 60 years and over	10	63.60	27	2.109	10.66	64.56	24.81
Average for males 20 years old and under 30	12	.....	24	2.082	.....	63.30	.....
Average for females 20 years old and under 30	26	.....	67	2.083	.....	63.51	.....
Average for males 30 years old and under 40	12	.....	18	2.090	.....	63.35	.....
Average for females 30 years old and under 40	14	.....	54	2.094	.....	63.48	.....
Average for males 40 years old and under 50	6	.....	19	2.093	.....	63.54	.....
Average for females 40 years old and under 50	6	.....	19	2.094	.....	63.92	.....
Increase due to age	.....	.....	.....	.043	.....	2.30	.....
Decrease due to age	.....	.....	.....	.....	1.29	.....	1.12
Average for persons who lost their teeth from diseases of the peridental membranes	15	50.	51	2.101	10.88	62.90	25.19
Average for cases in which the teeth are classed as bad	32	28.	121	2.087	11.25	63.33	25.49
Average for cases in which the teeth are classed as good	63	33.53	105	2.090	11.16	63.53	25.31
Average for cases in which the teeth are classed as fair	16	36.19	42	2.090	10.95	63.56	25.48
Average for perfect teeth	42	36.26	103	2.095	11.03	63.59	25.36
Average for carious teeth	91	31.5	165	2.091	11.06	62.50	25.36

of the dental profession and of the laity as well, was wrong. There had never been any substantiation of that interpretation by careful physical examination of the teeth themselves.

This summary speaks for itself and shows that the greatest difference in the calcium salts in the dentin, including all exaggeration that might arise from errors, was 4.35 per cent, and the usual range of difference was very much less than this. The differences due to age are also given, and it is found to be 2.30 per cent. When we consider that ivory, or the tusk of the elephant, has 20 per cent less of calcium salts than the human teeth, and we consider its hardness as compared with the human dentin, we will see that these slight differences in the amount of calcium salts can amount to nothing whatever as rendering the teeth more or less liable to dental caries. It is clearly shown in the comparison of the amount of calcium salts in the teeth of those whose teeth decayed badly with the amount in the teeth of those immune to decay, that there is no difference whatever. Teeth that decay badly have just as much calcium salts, are just as heavy and just as hard, as teeth of persons immune to caries. Therefore, while the fact in regard to caries being severe in this person's mouth, while the teeth of another person escape caries entirely, was a perfectly correct observation, to attribute this to the softness of the teeth in the one and the hardness of the teeth in the other, was a wrong interpretation; but this interpretation has become so fixed in the minds of men that it is very difficult indeed for many of the older men, particularly, to change their minds upon this point. It is perhaps well for the human family that opinions so widely held should have great weight in all matters pertaining to human welfare. They should not be cast aside without the very best reasons for so doing.

At the close of the paper communicating these results, the suggestion was strongly made that the causes of immunity and susceptibility to dental caries would necessarily be found in conditions of the general system, influencing the qualities of the mixed fluids of the mouth by which the teeth were surrounded. The composition of these fluids influences the action of the microorganisms growing in them in such a way that caries occurs in one person and not in another. While the elements entering in to produce these differences in dental caries might be totally different from those in systemic conditions controlling susceptibility or immunity to other diseases, the search for them would be conducted on the same general principles.

The storm of disapproval that arose when these results

were published was what might be expected under the circumstances. They were regarded as revolutionary, and rightly, for the results proved that many of the ideas of dental caries that had existed before were necessarily wrong, and other opinions must take the place of those which had been regarded as correct. Many arguments were advanced from time to time in the effort to sustain the older view, most of which have disappeared.

The hardness and softness of the teeth to cutting instruments has troubled a considerable number of men. It has been difficult for them to feel that all teeth were of equal hardness, or nearly so, as had been represented. A further careful study of the subject shows that this has generally been due to differences found in cutting the enamel of different teeth, rather than in cutting the dentin. With the exception of its tubules running through it, the dentin seems to be very homogeneous in structure. There is no disposition to split in any one direction more readily than another. Generally no accretion lines are discoverable, though these may often be brought in view by decalcification. We can not find them in the calcified dentin with instruments. In careful experimental work in cutting dentin, I have been unable to distinguish differences that seem to be of consequence. In the crushing strength, quite a little difference has been noted, which will be found in the tables of the strength of dentin accompanying the studies to which I have referred.

In the enamel there are wider differences in the apparent hardness to cutting instruments. These are due (1) to the direction of approach, (2) and to differences in the relation of the enamel rods to each other. The enamel is not a homogeneous structure like the dentin, but is composed of the enamel rods cemented together by a cementing substance which is less strong than the rods themselves and allows them to part on the line of their length more easily than in other directions. When the rods lie parallel with each other, the enamel splits in their direction easily when a breach has been made and a sharp chisel is used in the right direction on the margin of the breach. If we undertake to cut it in other directions with steel instruments, it is found to be very hard. This is called straight enamel. Figure 146 is a photomicrograph of straight enamel in which the rods lie parallel and are straight from the dento-enamel junction to the surface of the enamel. This enamel with straight parallel rods is found on very many teeth; perhaps in the majority of cases we will find the enamel rods straight and parallel, except over the cutting edges of the incisors and the

Fig. 146.

Fig. 146. A photomicrograph of a section of enamel having straight parallel rods running through its entire thickness. Such enamel splits away from the margins of a break very easily.

FIG. 147.

FIG. 147. A photomicrograph of curled enamel in which the inner two-thirds of the enamel is composed of interlaced bundles of rods. These straighten up and become parallel in the outer one-third of the thickness of the enamel. Such enamel splits away from the margin of a break with great difficulty as compared with enamel having parallel rods.

Fig. 148.

Fig. 148. A photomicrograph of curled enamel.

Fig. 149.

Fig. 149. A photomicrograph of the gingival portion of the enamel on the proximal surface of an incisor having curled enamel, showing the direction of the enamel rods in the extreme gingival portion. The cracks in the specimen indicate the direction of cleavage.



FIG. 150.

FIG. 150. A photomicrograph of a portion of a cross section of a tooth in which a cavity has been cut through the enamel, E, reaching into the dentin, D. The strength of an enamel wall depends on its relation to the direction of the enamel rods. The enamel wall marked B is the strongest that can be made, because all of the enamel rods are supported, by other enamel rods, against splitting off. The enamel wall marked A is frail and very liable to chipping because the enamel rods have not as good support.

cusps of the molars and bicuspids. We will find only a variation from the straight line in these positions on many teeth without intertwining of bundles of rods. Enamel with straight, or parallel, rods may, when undermined, be split off about the margins of a breach that has been made in it almost as easily as straight grain pine, if it is touched just right with a sharp instrument. If not approached in the right direction, it is very hard to cut. On the other hand, many teeth have enamel over most of their surfaces that is curled; that is, the enamel rods, instead of pursuing a straight course, are much interwoven among each other, usually in the form of small bundles of rods, twisting in among other bundles of rods. This gives to the enamel, when cut in sections and etched, a wavy, twisted appearance. This is called curled enamel. See Figures 147, 148. This form of enamel does not split nearly so readily as enamel with parallel rods. In fact, it is much more difficult to cut it by ordinary means. It should be noted, however, that in nearly all cases of curled enamel, the rods straighten up and become parallel before reaching quite to the outer surface. The checking of this straight portion to the part that is curled in Figure 147 is suggestive. Often the inner half will be curled and the outer half of the thickness straight. There are all sorts of differences to cutting instruments between the perfectly straight enamel, as shown in Figure 146, and the abundant intertwining of bundles of rods seen in Figure 147. The gingival portion of the enamel from the labial surface of an incisor is represented by photomicrograph in Figure 149, which presents much variation in the direction of the rods in its different parts. Some places they are parallel but much bent. Then, for another short space, they are much interwoven. In this respect the specimen is rather remarkable. In the cross section of the tooth at the point where the section was taken, shown in the photomicrograph, Figure 150, the rods are neither quite straight nor quite parallel, but do not depart much from either. But it may be seen how the rods are split up and clinging across the crack near the letter A, reminding one of what occurs in splitting cross-grained wood. One would, however, split off chips from the cut surface at A very easily. But to split off chips from the cut surface at B would be very difficult, not because the rods are more interwoven, but because of the direction of rods toward the cut surface. These differences seem to have no reference to the calcification of the enamel, nor the amount of calcium salts it may contain. In studying the difference of structure in its relation to caries of the teeth, no

differences whatever are found. Caries seems to pass through the one just as readily as through the other. Therefore, from this phase of the question, these differences are of no consequence whatever.

Faults in the Structure of the Enamel.

Faults in the structure of the enamel, such as pits and fissures, have already been spoken of as of importance in the localization of beginnings of decay. The importance of these has probably been overrated in the past. Very few of the pits are properly termed faults. They are normal to the teeth. They become faults only when they are abnormal in depth. Grooves along the lines of junction of the lobes of the teeth are normal. When these are of such depth as to merit the term "fissure" they are abnormal and are faults. These, even when faults, are in no proper sense a cause of dental caries, but they furnish favorable conditions for the action of that cause. They must be regarded as giving opportunities for the beginning of decay when conditions otherwise are favorable. But decay does not begin in the pits of the teeth of immune persons, though these pits may be just as deep and just as sharp as the pits in other teeth which do decay rapidly, and even among those who are very susceptible to decay, many pits will be seen without decay, in those teeth that are decayed upon their proximal surfaces. This is so frequent that they are coming up continually in the laboratory study of caries. In the illustrations accompanying this article, these will be seen in Figures 107, 108, 110. Here we see that the pits have escaped the beginning of caries when the patient has been sufficiently susceptible for proximal decays to start and run a rapid course. So many of these occur that we must regard the condition of immunity as entirely sufficient to prevent decays starting in pits, unless the conditions locally are particularly inviting. This may be said to be true of all teeth which would be regarded as of normal conformation. We occasionally find malformed teeth in which the pits and fissures have failed of closure and in which some area of dentin is actually exposed. This, however, is rare. Ordinarily, all of the deeper pits have a fairly good layer of enamel covering the dentin, but this forms no considerable barrier to the beginning of decay, for, in susceptible persons, the enamel seems to decay readily in such positions, while in those who are not susceptible there is no decay in pits or elsewhere. I once obtained fourteen teeth, mostly bicuspids and molars, from the mouth of a woman

over fifty years old, who had reared a family of children, but had never had a decayed tooth. The teeth were lost because of disease of the peridental membranes. I split these with a fine saw and examined carefully the pits found in them. They were unusually deep and sharp, forming what seemed to be unusually favorable places for caries to begin, yet the enamel was perfect in the bottoms of all of these pits. Still, from my experience, I am convinced that a well-fitted band of some considerable width, immovably fixed, but with a buccal surface left without cement, would have produced caries in that mouth. There are certainly differences in the saliva that favor microörganisms becoming fixed upon and clinging to the teeth of some persons, while in other persons there is that which opposes this, and every part is washed so freely as to carry away all acid formed by any growths that may temporarily lie upon the enamel. The band prevents this dissipation.

These pits occur in the occlusal surfaces of the teeth of all animals that are omnivorous in their diet, and should not be regarded as abnormal in man. The fact, however, that decay in them occurs so frequently, gives abundant evidence that they furnish the opportunity for its beginning. Therefore, if the teeth are really faulty in their structure so that there are open fissures as well, decay is the more certain to occur. There are some faults in structure within the dentin which give rise to unusual forms of cavities. Sometimes the granular layer of Tomes is very much more considerable under some parts of the enamel than others, inviting the burrowing of decay in special directions, causing irregular forms of cavities. Often, also, we find irregular groups of interglobular spaces in the dentin into which microörganisms grow very readily and in that way produce irregularities in cavity forms. This occurs when there is no appearance of atrophy upon the enamel. In cases of atrophy, particularly where the occlusal surfaces of the first molars have been wrecked, caries is very likely to run through the sheet of interglobular spaces that occurs in the dentin, usually only a little below the surface. This often forms a broad, open cavity with the decay still following this sheet of interglobular spaces until finally the whole occlusal surface is cut away, the decay having extended but little in depth. The result is that the whole occlusal surface of the tooth has decayed, leaving a blackened stump, which may come to occlude with its fellow of the opposite jaw and do excellent service in mastication. It too often happens, however, that decay persists in those portions of the sheet

of interglobular spaces that dip down on the axial surfaces and finally reaches the pulp of the tooth. As the atrophy occurs in all four of the first molars, it is rather rare that some one or more of them is not destroyed. These are the principal faults in the structure of the teeth that seem to influence caries. It will be noted that all of these faults are such as are discoverable by macroscopic or microscopic examination. No faults in the chemical structure of the teeth have been found which seem to influence caries in any marked degree. Even some of those rare cases in which the cementing substance between the enamel rods has failed, leaving the enamel rough and chalky, have been found almost immune to dental caries. It would seem that such teeth would be especially liable to decay early and quickly, and they certainly would do so if they were in the mouths of susceptible persons.

Physiological and Pathological Differences Between Bone and Dentin.

ILLUSTRATIONS: FIGURES 151-155.

Some persons have seemed to suppose that the teeth and the bones, being calcified tissues, should have similar physiological processes of nutritional change and of repair, and that similar changes might be expected as results of pathological conditions. It is well known that, in certain diseases, as in rickets, the bones become soft and may become hard again; and that nutritional changes are going on continually in the bones up to an advanced age, if not during the whole life, and that the bones are very apt to become hard and brittle as persons grow older.

In the study of the bones, we find that, continuously, or at least frequently, portions of the bone are being removed by absorption and replaced by Haversian systems, so that the shaft of a bone that has been formed largely as subperiosteal bone, is finally converted almost or quite into bone composed of Haversian systems. This is shown in Figure 151, which is a photomicrograph from a cross section from the femur of a young person. In this figure the line drawn from the letter A passes over laminæ of subperiosteal bone, which have not yet been cut away. The lines drawn from B point to Haversian systems, where the subperiosteal bone has been cut away and new bone supplied in the form of circular whorls, with a canal in the center of each, which is called a Haversian system. In Figure 152, a photomicrograph from a section cut lengthwise of the same bone,

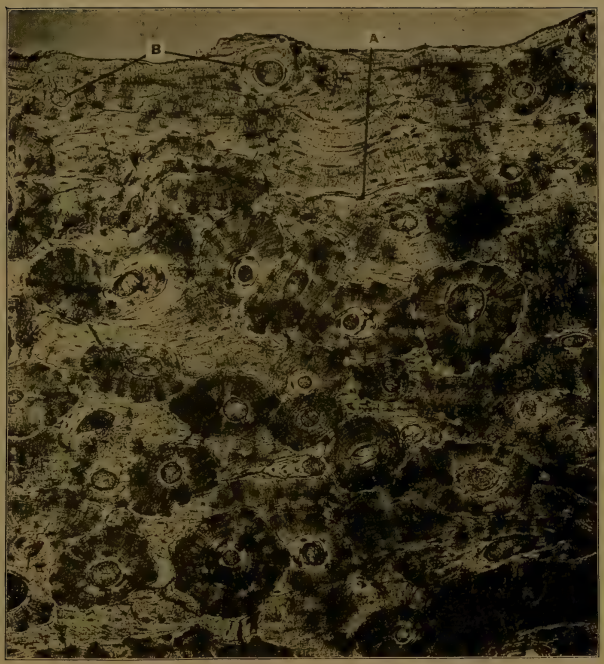

FIG. 151.

FIG. 151. A photomicrograph from a cross section of bone from the human femur from a young person. A. This line crosses laminæ of subperiosteal bone. B. These lines point out Haversian system bone. These Haversian systems that are seen to form the bulk of tissue are formed by the absorption of the original subperiosteal bone and building in the Haversian system bone.



Fig. 152.

Fig. 152. Lengthwise section from the same bone, as illustrated in Figure 151, showing the Haversian systems and their canals cut lengthwise. A. Subperiosteal bone. B. A Haversian canal.

FIG. 153.

FIG. 153. Photomicrograph of a cross section of the root of a tooth in which absorption is in progress. A. Line of absorption, showing the usual notched appearance known as the lacunæ of Howship. D. Dentin. C. Cementum. P. Peridental membrane. The pulp chamber appears in the left-hand part. The dento-cemental junction appears between the letters C and D.



Fig. 154.

Fig. 154. A photomicrograph of bone in process of absorption. A. Line of absorption showing the lacunæ of Howship.

Fig. 155.

Fig. 155. A photomicrograph of a portion of the root and peridental membrane of a tooth in which an absorption has been repaired by a new growth of cementum. D. Dentin. C. Cementum. P. Peridental membrane. R. New cementum built in, in repair of an injury by absorption.

shows the Haversian canals cut lengthwise for the most part. In studying these, it will be seen that nearly the entire substance of the bone as first formed has been cut away and is replaced in the form of Haversian systems, and in many of the bones we find no traces of subperiosteal bone left, except, possibly, on the outer surface. In this cross section, however, we find many patches of subperiosteal bone scattered through it, though most of it is occupied by the Haversian system bone. Each Haversian canal has its blood vessels. In many bones we find the Haversian systems have been cut out again and again and new Haversian systems built in their places. This is not done by removing the old Haversian systems individually, but by absorptions that seem to run through the bone at random, often cutting out parts of these systems and leaving parts by which such additional cutting and rebuilding is readily recognized.

This is nature's manner, or the physiological plan of making nutritional changes in the bones; a plan perfectly well known to histologists and physiologists. There is no such plan for nutritional changes in the human teeth. Normally, there is no absorption of the roots of the permanent teeth, nor any absorptional changes going on. Normally, as a physiological process, however, the roots of the deciduous teeth are removed by absorption in the shedding process. Figure 153 is a photomicrograph from a line of absorption at A in a cross section of a deciduous tooth, showing the peculiar notching known as the lacunæ of Howship, where the dentin and cementum were being removed by the process of absorption. In the bones the process of absorption is practically the same in kind and quality, and though we name the cells which absorb bone, osteoclasts, and those which absorb the roots of teeth, odontoclasts, there is really no difference in the two processes physically or physiologically. Figure 154 is a photomicrograph from an example of this in bone, which may be compared with that in dentin and in cementum. An absorption of bone is always repaired with bone. It may, if it is on the surface, be repaired by subperiosteal bone. If within the bone, it is repaired by Haversian system bone. An absorption of any portion of a tooth, dentin or cementum, if repaired at all, is repaired with cementum; no matter how deeply it may have cut into the dentin, it is never repaired by dentin. Many of these repairs are found in the study of the histology of the teeth, where, for some cause, an absorption has occurred, cutting deeply perhaps into the root of the tooth. Several pictures showing this are published in my book on "Periosteum and Peri-

dental Membrane." The photomicrograph, Figure 155, shows the repair of an absorption which had occurred in the root of a tooth in which the full contour is rebuilt with cementum.

These illustrations are brought prominently forward in this place as the histo-physiological expression of the fact that dentin possesses no means of physiological repair. Additions may be made to it by the action of other tissues, but dentin never repairs itself. It is never repaired by dentin under any circumstances, excepting such as may be done by calcifications occurring in the pulp chamber. These may sometimes effect a repair of an exposure of the pulp. This latter is a physiological process, however, in which the pulps of teeth are inclosed by further deposit of calcified matter, by cells whose physiological purpose has been the building of the dentin originally. Their sphere of action is always within the pulp chamber, never elsewhere. The suggestion has been made that some additions of calcium salts may be made on the walls of the dentinal tubules, narrowing their caliber. This is plausible, but, as yet, no sufficient series of measurements have been made to determine the facts. An injury of any character occurring to the dentin during its development remains an injury for life. In the study of atrophy, we find sheets of interglobular spaces passing throughout that portion of the dentin being formed at a time of malnutrition. These are never repaired. They form an injury that remains permanently. Dentin, or enamel, once formed, is formed for all time; it never can be re-formed, changed, or improved in its character or qualities. It is fixed material; nature has furnished it with no physiological means of repair or betterment.

Studies by Dr. J. Leon Williams.

ILLUSTRATIONS: FIGURES 156-158.

Dr. J. Leon Williams, of London, published a series of studies (*Dental Cosmos*, 1897) of faults in the teeth of animals as compared with faults in the teeth of man, and of the beginning of caries under plaques formed on the surfaces of teeth, which he found to be composed mostly of microörganisms agglutinated together. He found the structure of the human teeth much more perfect than that of the teeth of the animals. The faults in structure were less frequent in man and generally of less consequence, notwithstanding the fact that animals do not suffer from caries of the teeth, except in a few rare instances of captive animals kept in cages, some domesticated house-dogs, etc.



Fig. 156.



Fig. 157.

Fig. 156. A photomicrograph of a plaque covering the surface of the enamel in which caries is beginning. *Williams.*

Fig. 157. A thick gelatinoid plaque over the surface of decaying enamel. *Williams.*

Fig. 158.

Fig. 158. A photomicrograph showing a stained film of microörganisms over the surface of decaying enamel. In pressing down the cover-glass in mounting the specimen, the microbic film has been parted slightly from the surface of the enamel. *Williams.*

It will be found by a review of the dental literature, that decay of the teeth of man was generally supposed to be because of imperfection in their structure, and many times it has been said that the teeth of man were degenerating and were not so well calcified as the teeth of animals. After a long series of studies, Dr. Williams' opinion was exactly the reverse; and further, that the decay of the teeth of man was not to be attributed to their faulty structure. This opinion seems to have been well supported by the histological structures developed by his microscopic work. His work took a wide range among the lower animals.

As I had been studying gelatinous masses formed on the teeth by microörganisms and their influence in shielding the organisms growing in them from washings by the saliva, which would dissipate the acids formed, I was much interested in this phase of his work. But later, in the study of his illustrations and methods, comparing these with my own work along similar lines, it seemed that he had included all manner of material that contained microörganisms (practically any material clinging to the teeth contains them), going wide of the line of those forms of fungi known to produce caries. He seems also to have included deposits through which water would run so easily that they would be no bar to washings by the saliva. Such coatings are found plentifully over the surfaces of the teeth of immune persons, and also in others where there is no decay of the enamel. Careful study shows that many kinds of deposits upon the teeth present similar appearances, when seen in microscopic sections, to those produced by gelatinous plaques, and yet seem to have no influence whatever in the localization of caries. A plaque, to have any considerable effect, certainly must have sufficient firmness in the moist state to act more or less perfectly as a dialyzing membrane.

In the technical sense, Dr. Williams' work was beautifully done, and there is no doubt that caries was shown under the aggregations of organisms in many of his photomicrographs. Three of these, Figures 156, 157, 158, are reproduced from the *Dental Cosmos*, of 1897, by permission.

Sialo-semeiology.

Dr. Joseph P. Michaels, of Paris, presented a brochure under the above title to the International Dental Congress, Paris, 1900, which has been translated into English and published in the office of the *Dental Cosmos*, 1902.

In this, Dr. Michaels claims to have found the means of determining definitely the existence of the conditions of susceptibility to, or immunity from, dental caries, by the examination of a few drops of the individual's saliva. Persons who have spent some time in Dr. Michaels' laboratory and looked over his work, seem convinced that he can do what he asserts. In this writing, the qualities of the saliva are summarized thus: (1) Normal, (2) Hypo-acid, (3) Hyper-acid, and (4) Cacochymic.

In the first, the normal, little or no caries occurs. In the hypo-acid condition, the susceptibility is intense or moderate, according to the intensity of the condition. In the hyper-acid condition there is immunity from dental caries. The cacochymic denotes a bad condition of the saliva, due to some functional derangement or organic disease without further specification, and includes very variable conditions. It has no special reference to dental caries.

The terms, hypo-acid and hyper-acid diathetic states, do not refer to reactions to litmus. He says: "The abnormal vital processes tend in mankind to pathological conditions, which we may classify under two humoral conditions, viz., hypo-acidity and hyper-acidity. The first state (lymphatism) is the expression of a vital over-activity and has as consequences the contagious diathesis (scrofula, tuberculosis, syphilis). The oxidations are over-active and the hydrations superior to the normal, hence there is a decrease in organic acidity and an increase in the saline chlorids excreted by the economy. Hypo-acidity, according to Duclaux, favors chemical changes in the tissues. In the hypo-acid diathesis all of the oxidations are exaggerated and above normal. . . . Hyper-acidity is a particular state of the organism characterized in a general way by slowness in the biochemical changes. . . . It is not doubtful that the activity of caries in some individuals and the immunity from or the slowness of decay in others are in correlation with diathetic states well determined, resulting from a lack of proper balance of the general factors, and in particular of the blood plasma."

Many of the expressions in this brochure seem difficult for many who have read them to understand, but it has seemed evident that, while many other substances in the saliva are found to influence conditions as to caries of the teeth, the absence or presence of the sulphocyanids, or the large or small proportions present, is the most constant mark separating the condition of susceptibility to caries from the condition of immunity.

Much of the work is done by the examination of crystals by

the microscope and micropolariscope, and is necessarily qualitative rather than quantitative.

Recently the committee of the New York State Dental Society on dental science has taken up the question of the influence of the presence of the sulphocyanids in the saliva as a special piece of work, and is making numerous examinations by clinical and laboratory methods. Its last annual report is not yet at hand, but from the information derived from private sources, it seems that this test alone is giving correct indications as to the susceptibility to, or immunity from, caries, in about ninety-six to ninety-seven per cent of the individuals examined. This is indicated by the absence of, or only very slight reactions, indicating the presence of none or a very small quantity of the sulphocyanids of potassium in susceptibility, as compared with more decisive reactions indicating a large quantity of the sulphocyanids in the saliva of immune persons. In the prosecution of this work, another point has developed which may prove of much significance upon further examination. In some cases which were examined a number of times, the teeth, after being well cleaned, were found again coated over with gummy material so quickly as to attract special attention. This gave rise to the suggestion of precipitation from the saliva of some material in it that was not held in solution. Therefore, this saliva was compared with the saliva of others, in whom there was an absence of such material, as to its power of dissolving the residue of saliva that had been dried. The result was that the saliva from which such deposits occurred would not dissolve such residue at all, while saliva from persons whose teeth remained free from such deposits dissolved them readily. It will be of much interest to know whether or not such deposits will form films that will act as dialyzing membranes and so inclose colonies of microorganisms as to protect the acids formed from a too free dissipation in the fluids of the mouth, and, in this way, become a factor in the production of the beginnings of caries of the enamel. This may lead to some important discoveries in the near future.

Dr. Carl Röse, of Dresden, Germany, is doing an immense amount of work on the saliva, especially with reference to its amount under different conditions of living and the variations in the salts it contains. In this work he is collecting an immense amount of data with reference to the effects of the salts found in the water used for drinking and cooking purposes. In this work he is developing important facts regarding the relation of

these salts to the percentage of dental caries, the relation of the amount of saliva secreted by the person to the percentage of caries, the relation of salts in drinking water to the development of the salivary glands, etc. The examinations have been mostly made in children. These have been widely distributed in Germany, Switzerland, Denmark, Sweden, etc. The work is still in progress.

This mention of work being done is given here to show the direction which thought is taking and the activity manifested, rather than for the purpose of giving specific information of its detail. The questions are of very recent origin. The question of immunity and susceptibility to dental caries as a systemic condition as known to-day, was first propounded in 1895. Years will probably be required before this problem, involved in such obscurity and difficulty, can be so unfolded and simplified that the general profession may make practical use of it in the treatment of dental caries. In the meantime, the general discussion of it belongs to the journal literature rather than to books.

The Saliva.

When the saliva is mentioned without designation of its special parts, it is most generally understood that the mixed fluid found in the mouth is meant. This is made up of secretions from several sources, any of which may be examined separately. These are the saliva from the parotid gland, saliva from the submaxillary and sublingual glands, and mucus from the mucous follicles situated in the mucous membrane of the mouth. The different salivas are much alike. Though variable, they are generally very limpid, watery secretions. The mucus, on the other hand, is more generally found to be a thick, ropy secretion. If the parotid saliva is collected directly from Stenson's duct it will generally be found to be about neutral in its reaction with litmus, varying from slightly alkaline to slightly acid. If the mucous membrane of the mouth, say the roof of the mouth, is dried and the mouth held open for some time, one will generally find here and there globules of fluid collecting on its surface. Sometimes many of these will be seen; sometimes very few, and, occasionally, none without a very long wait. The secretion seems to be very variable. Touching litmus to this generally brings a very definite acid reaction. In the lips, I have usually found much larger glands than elsewhere in the mucous membrane. Some of the larger of these seem to emit a much more watery fluid than the usual submucous glands. It is more of the nature

of that from the salivary glands. This seems to have to do with the moistening of the mucous membrane of the lips especially. The mucus is very variable, both in amount and consistence. Often it is very thick and viscid, so much so that, by touching the finger to a globule, it may be drawn out into a very long thread.

The variations in the viscidity of the general saliva have been commented upon by most of those who have examined it in many individuals. Often it is found to be very thin and watery. Not very infrequently it is almost as thick and viscid as the mucus itself. I have met with persons whose saliva was so viscid that I could at any time draw out threads two or three feet long by touching my finger to it and drawing it away. In filtering this, it will leave an unusually large amount of gummy material on the filter. In such cases an excitation of the flow of saliva generally causes the thinning of the mixed fluid for the time, which seems to be due to the larger proportion of the parotid, submaxillary and sublingual salivas.

There are great differences in the saliva as to deposits. Many persons are found whose teeth are free from deposits of gummy or slimy material. The saliva seems to hold all of its ingredients in complete solution, and is capable of dissolving quickly all of the ordinarily soluble things with which it comes in contact. Therefore, the mouth is always clean and free from debris. In others the saliva seems habitually incapable of holding its own ingredients in solution. The teeth especially are continually covered with a slimy, viscid coating, and more solid deposits are frequently found. Many writers have noted these differences in persons, and also at different times in the same individuals.

The salts of the saliva seem to be very variable. If a person consults many authors, who have reported their findings, he is soon lost in a maze of discrepancies. Dr. Michaels quotes the following from Hammerbacher as representing normal saliva in an analysis of 1,000 parts:

		Salts:	
Water	994.203	Carbonates	....
Mucin	2.202	Phosphates	....
Ptyalin	1.390	Chlorids	2.205
Fixed constituents	5.790	Sulphates	....
		Nitrates	....

In normal and abnormal salivas, somebody has found almost every normal, abnormal and accidental constituent of the body.

Some seem to be of the opinion that much of the make-up of the saliva is a transudation from the blood, of constituents that it may happen to contain at the time, together with some constituents that are characteristic of this fluid. It seems to be on this idea that Dr. Michaels bases the proposition that in the saliva an index is to be found of the general and special bodily conditions, when one has learned to read them. For the present I must conclude that the finer pathological reading of the indications given by this fluid are in a chaotic state; that only a few things are assuming definiteness and that much time will yet be necessary to unravel its complexities.

ACIDITY OF THE SALIVA.

The question of the reaction of the saliva has been under especial discussion for a century, and still men are differing so widely as to their findings that quotations would lead to confusion. My own conclusion, after many examinations, is that the saliva as it comes from the glands is very nearly neutral, but varies within a rather narrow range from alkaline to acid. On account of the acidity of the mucus, the mixed fluid is generally slightly acid. This becomes more decisively acid by the fermentation processes of the microörganisms that are continuously growing in the secretions in the mouth. Some of the elements of the saliva seem to be fermentable, and sugars and starches taken into the mouth quickly become fermentable. If examined in the early morning at the time of rising from bed, the saliva will, as the general rule, redden litmus sharply. If examined after breakfast, the acidity is much reduced. The acidity will then increase until the next meal time, after which it will be reduced again. This is being continually repeated. When the flow of saliva is least, as in sleep, its acidity is increased by the fermentative processes of the microörganisms growing in it. At meal time fresh saliva is secreted in larger quantities, and this, with the food, carries the superacidulated saliva away, replacing it with that which is normal. The degree of acidity may depend in some part upon the differences in the saliva as it comes from the glands. But, from my own examinations, the evidence seems to point especially to differences in the fermentation going on in the mouth. Differences in the constitution of the saliva — probably in its salts, possibly other matters also — seem to render decompositions by microörganisms much more rapid in some than in others. Again, the complexities of the saprophitic organisms in

the saliva, are matters of time, place and the prevalence of special forms of these growths in the surroundings.

Under the idea that caries of the teeth was caused by acidity of the saliva, this subject has, in the past, been regarded as very important. I do not now so consider it. Acidity of the general saliva does not become sufficient to cause caries. Those immune to caries have saliva fully as acid as those most intensely susceptible to caries. The two seem not at all related as cause and effect. Microörganisms produce caries only when they are secluded from the general saliva by some kind of covering, as has been sufficiently indicated on previous pages. Conditions of the saliva that enable microörganisms to form these coverings, or which form them independently of the action of microörganisms, are, apparently, the important objects of search. It is in no proper sense a search for conditions in which microörganisms will or will not grow in the saliva. They grow in all conditions yet found, and just as freely in the saliva of immune persons as in the saliva of the most susceptible.

VISCIDITY OF THE SALIVA.

If the conditions of the fluids of the mouth be studied from week to week, in each of a considerable number of persons with reference to accumulations on the teeth, it will be found that the saliva of some persons is habitually very thin and watery, and that the teeth are habitually clean. The saliva of other persons will be thicker and more viscid. This latter may be drawn out into long threads by touching the finger to it and drawing it. This has been termed "ropy saliva" or "viscid saliva." Generally the teeth will be difficult to keep clean when the saliva is ropy. The person may, by care, keep the teeth looking well, but a close examination will show them to be covered by a transparent slimy material of sufficient thickness to be clearly apparent. If this be cleaned away, a new deposit will be found the next day. In many of these cases, if the saliva be touched by a rapidly rotating disk or stone, it will quickly thicken up into a more or less firm coagulum around the disk or stone, reminding one of the clotting of fibrin. The opportunity to observe this can be best obtained by holding the buccal mucous membrane well away from the lower bicuspids and molars with one finger and waiting a little for some accumulation of saliva and then touching the margin of the rapidly rotating disk or stone to the surface of this accumulation. Often the saliva will quickly ball

up on the disk or stone in a clot of considerable firmness. The degree of stickiness of this mass and the firmness of the clot formed is perhaps the best index to the degree of ropiness of the saliva. In some individuals this ropiness will be very marked at each examination for months and years together, but will differ in degree from time to time. This test, when applied to a number of individuals, will give a very marked contrast between those with thin, watery saliva and those with ropy saliva, and will show all manner of gradations between the extremes. While the degree of ropiness of the saliva is not a certain index to the degree of susceptibility to dental caries in the person, it will almost uniformly be found that caries occurring in the presence of this condition will be more difficult of management than when occurring in similar degree in persons with thin, watery saliva. Proximal cavities, particularly, will more certainly spread broadly bucco-lingually, and deposits on fillings will be more likely to overstep the margins and cause recurrence of decay. Therefore, decay is much more likely to recur after fillings have been made.

GLUTINOUS DEPOSITS FROM THE SALIVA.

Another condition not frequently noted by writers, but one to which my attention has been strongly drawn clinically, is the tendency to slimy or glutinous coatings upon the teeth of some persons, which, apparently, is a deposit from the saliva. These deposits may be found especially upon the axial surfaces of the teeth. They also tend to keep the mucous membranes slimy and slippery to the touch. There is also a degree of viscosity clearly discoverable by rubbing buccal surfaces of the teeth back and forth a few times with the finger and then rubbing this material between the finger and thumb. This seems, often, to be independent of any considerable ropiness of the saliva. It seems to be a deposit from the saliva of a material which it fails to hold in solution. I have supposed this deposit to consist chiefly of mucin, but I know of no examinations that certainly indicate its nature. It is different entirely from the material forming the gelatinoid plaques. It is apparently not formed under the influence of microörganisms, or, if so, it is through their influence on the saliva as a body.

A very curious and possibly important discovery has been made by the committee of the New York State Dental Society on dental science, alluded to previously, which may be thus

stated. The deposit is insoluble in the saliva of the person in whose mouth it is found, but is readily soluble in the saliva of persons in whose mouths such deposit is not found. From recent examinations, I have been led to strongly suspect that this may favor the beginning of caries or actually furnish one of the necessary elements, by affording coverings that will shield micro-organisms and their acid products from washings by the saliva; but, as yet, this is by no means assured. This condition seems to be much less constant in the mouth of an individual than ropy saliva.

The conditions in which solid deposits from the saliva occur, as salivary calculus, are, of course, well known from observation of results. As a rule, this condition belongs to immune persons or those who would have become immune if caries had been kept under control. It used to be a saying that diseases of the gums from deposits of calculus destroyed the best dentures, that is, teeth that did not decay. In these later days we are often finding dentures destroyed from this cause after caries had been controlled with much difficulty up to the time when immunity to decay had given relief. Some cases of extensive deposits of calculus occur, however, coincidently with rapidly progressive decay of the teeth.

There is to-day no more promising field of useful discovery than in qualitative examinations of the saliva recorded with intelligently observed conditions of the mouth and teeth. All the aids that scientific instruments can give should be brought to bear to bring out the details of its chemical constituents.

SIGNS OF SUSCEPTIBILITY AND IMMUNITY TO DENTAL CARIES.

In the meantime, the recognition of the conditions of susceptibility and of immunity, and the more prominent symptoms by which these may be known, becomes important. As yet, no language expression regarding this has taken such form that the conditions may be readily conveyed in words. I suppose that most dentists at present wait for the disappearance of superficial beginnings of decay before announcing the coming of immunity to caries, but those who are accustomed to looking for signs of the coming of immunity to the beginnings of decay depend more upon other conditions that may be seen earlier; which point out the approach of the condition of immunity, or a condition in which the predisposition to caries is abating. These signs are practically the same as formerly relied upon for determining the condition of hard teeth as distinguished from soft teeth. While

this interpretation was wrong, the appearances pointed out those conditions in which little or no decay occurred, as distinguished from conditions of marked susceptibility to decay. The observations as to the liability of the person to caries were correct, as most of the older men can testify from long experience; yet I think that there will not be a very close agreement among men if different persons undertake to put these signs into word forms. The assemblage of differences in the things seen is difficult to form into language. It is much like the remark an old and very skillful physician made in speaking of the difficulties of young men in medicine, "The best asset is the ability to read the physical expression of disease, which is acquired only by much careful observation." This physical expression of the assemblage of conditions in immunity is such as gives the impression of solidity and firmness to the denture. There is a slight darkening of the teeth without uncleanness. Especially there is more apt to be a gathering of dark color here and there instead of lodgments of a lighter shade. However, until some more apt expression of this in words arises, which will appeal to many persons as having weight, any considerable discussion of it will be of little value. We can certainly recognize it by the fact that new beginnings of decay cease to appear. Gradually the assemblage of appearances which foretell the coming of this will be recognized. These differences are evidently due to changes in the constitution of the saliva.

Microörganisms of the Mouth.

It is not the intention to enter into any lengthy discussion of the microörganisms of the mouth. That subject should be studied in the bacteriological laboratory. It may be well, however, to mention here that the numbers of species of microörganisms habitually growing in the saliva, as mouth organisms, seem to have been greatly exaggerated. The fact is, the human saliva becomes a harbor for any and all microörganisms floating in the atmosphere, or introduced with food, and many of these will grow for a little while in the saliva, or will grow in culture media when removed from the saliva. These strangers are always being caught up by persons who cultivate microörganisms from the saliva. In the culture media used, many of them grow very much better than the mouth organisms proper and form much more attractive growths. A number of men have given large numbers of species of microörganisms as found in the saliva, but they seem not to have undertaken the work of determining

what organisms are habitually found in the mouth and separating these from the occasional or frequent visitors there. These visitors are of no consequence to us, except as they happen to be pathogenic in character. The great bulk of them are harmless.

At one time, when I was studying this subject, I found that very much dreaded organism, streptococcus pyogenes, in the saliva and under the finger nails of six nurses in a hospital ward. All of them had been engaged more or less closely in the handling of suppurations in which this organism was the principal factor, and, of course, would have been in serious danger from any lesions that would have allowed the organisms to enter their tissue. From observations made at the time, it was my belief that they had infected some operation wounds that otherwise would have escaped infection. A week later I was unable to find any trace of these organisms in the saliva of these persons.

I have cultivated microörganisms from the mouth in several different cities and noted particularly the varieties found. Further, I have compared cultivations annually for many years with a view of, in some degree, separating the regular habitues of the saliva from those organisms that grow accidentally, or are caught in the mouth, but do not belong there. As a matter of fact, the great bulk of microörganisms found in the mouth are there by accident, and yet it requires very persistent work to separate them from the regular habitues of the mouth.

In 1891 and 1892, in Chicago, I found rather a large bacillus growing in chains that stained in distinct lines, running diagonally around each, other parts of the cell not taking the stain. This made a very beautiful appearance as a mounted specimen. It occurred in almost every mouth examined, both among students and patients in the infirmary, and it continued during these two years. The next year, however, it had disappeared.

By this method of elimination, I have reduced mouth microorganisms proper — those that are found in practically every mouth, either in children or grown-up people, in which there are some differences — to about twelve or fourteen varieties, certainly not more than fourteen. Of these, only about one-half can be cultivated in artificial media.

By far the most important of these that I have ever examined carefully, and the one that is found in every mouth, is the streptococcus media, streptococcus buccalis, or caries fungus. This is in the saliva of young children, and in old people, and all ages between. A short bacillus that was seen and described by Dr. Miller, but not named by him, which I have called bacillus

alba, because of its white color in growths upon gelatin or upon agar-agar, is a persistent inhabitant of the human mouth. That which I have termed a zigzag coccus is also very generally found, and often it may be found very deep in carious dentin. It is a staphylococcus, liquefies gelatin readily and is often found in alveolar abscess. The familiar tetragenous is sometimes missing, but is very usually found by a little search in the mouths of young people. Another organism, that I have called micrococcus irregularis, because of the irregular size and form of the individual cocci, is sometimes pretty hard to find, but is generally found. Dr. Miller describes this also, but gives it no name.

Other organisms habitually found in the mouth are all of the non-cultivatable varieties, the most prominent among which is leptothrix buccalis — the soft threads — and the leptothrix of Vignon — the stiff threads — that often, under the microscope, look almost like so much hay. This later organism I have succeeded in cultivating through three generations, and find that it runs through three forms: A straight stiff stem, which finally breaks up into bacilli, which, in turn, give rise to spores, which appear as cocci in stale cultures. These have grown and run through a similar change, running to the third generation, but I could not proceed further with artificial culture. It is very difficult to isolate, for the reason that it does not form colonies on gelatin or agar-agar.

The streptococcus continuosum, which, when the threads are broken up, has often been confounded with the caries fungus, is occasionally seen in broth cultures in isolated threads. A few times I have succeeded in isolating it and getting a pure growth, but could not grow it a second time from such cultures. The growth, when pure, is in great festoons that will fill the whole tube for a space, while the broth shows none of the cloudiness usually found when microörganisms are growing. These festoons are almost a pure white. As it will not form colonies on either gelatin or agar-agar, it is extremely difficult to isolate.

Another, of very peculiar form, is the micrococcus vaginatus, described by Dr. Miller, which refuses all of the anilin dyes, and thus far can be stained only with iodin dissolved in a solution of potassium iodid. This organism may usually be found without difficulty about the necks of the teeth, wherever there is a little accumulation, if properly looked for, using iodin stains. Otherwise, they are not seen, though they may be plentiful in smear preparations. They have never been cultivated.

These, with the varieties of the threadlike forms, do not

grow in any culture media. These latter may be seen in active motion in saliva taken from almost any part of the mouth when a drop is covered simply with a cover-glass without other preparation.

This forms about a complete list of the microörganisms found sufficiently constant in the saliva to regard them as regular dwellers in the mouth. We know very little of the functions of these uncultivatable varieties. So far as we are now able to judge from clinical observation, they are of no especial consequence. The microörganisms which produce putrid decomposition, so frequently found in the mouth, are there by accident, if we may term it such, for they are apparently always on hand, wherever there is a material for putrid decomposition in the mouth or elsewhere. To produce true putrefaction, they must be in a position of complete exclusion of oxygen. There are, however, decompositions closely resembling true putrefaction, which occur without complete exclusion of oxygen.

UTILITY OF STUDIES OF DENTAL CARIES.

When Dr. Miller made out the life history of the micro-organisms which cause caries of the teeth and fully determined their action in carious dentin, it was hoped by many that this would be a guide to treatment that would become of great advantage in the practice of dentistry. The profession did not appreciate the wide difference between caries of dentin and caries of enamel, and did not realize the greater importance of an understanding of caries of enamel — which is necessarily the first tissue involved in dental caries — in the practical application of filling operations for the control of caries. The importance of this factor in the practical use of Dr. Miller's findings in the treatment of dental caries has come very slowly to the minds of men; but it must now be seen that these findings have been the basis of advancement in the study of caries of enamel, which has directed the formulation of our principles of treatment. The interpretation which held that the teeth decayed because of inherent weakness in the teeth themselves, or from variations in their calcium salts, seems to have been responsible for much of this delay. The profession has been very slow to understand that caries of the enamel is the principal factor to be considered in any treatment that may be instituted for the control of dental caries. We can not prevent the growth of microörganisms in the saliva, as has been determined by Dr. Miller and confirmed by numbers of men; therefore our attention must, for the present, be turned to the question of preventing or limiting the injuries they do to the teeth.

Caries of enamel is the initial lesion and always occurs as the beginning process of dental caries. When the enamel has been penetrated and the carious process becomes established in the dentin, the only possible method of treatment is by its eradication by excavation and filling. In caries of dentin, the micro-organisms have become established within the tissue itself and can not be reached by any antiseptic or prophylactic measures. Caries of enamel, however, always begins upon the outside of the tooth, or in pits and fissures in the surface, most of which are readily reached by careful cleaning and are amenable to prophylactic measures, when these can be applied with sufficient frequency. This, however, as to frequency, seems very nearly

impossible in all of those positions which patients can not themselves successfully reach.

The work that I have myself done in the prophylactic treatment of buccal surfaces shows plainly that decay of these can be perfectly controlled by the use of the tooth brush and plain water by the patient, whenever the habit is sufficiently formed that it will not be neglected. The principal utility in sight just at the present time in the study of caries of enamel is that, by these studies, one will learn to apply extension for prevention logically to the cases that present, and will not make the mistake of cutting too wide or of cutting too little, so frequently as is being done now by men in dental practice. The indications are sufficiently plain to those who know them.

It seems to me that these principles have been described with sufficient accuracy for all men to learn them. To make these descriptions better and plainer is one of the objects in writing this book. Heretofore they have never been illustrated as we are able to illustrate them now. The idea that dental practice is purely mechanical and not dependent upon knowledge of the pathology of dental caries, should be abandoned forever. To learn to use instruments deftly and to make an excellent filling from the mechanical standpoint is essential, and it is well that so many persons are becoming able to do this, but it is not enough to make a splendid filling from a mechanical standpoint. The planning of the filling must be such as to adapt it, not only to the cure of the particular decay, but to prevent the recurrence of caries in the future.

To do this wisely requires a closer study of the beginnings of dental caries in the enamel than has yet been made by the general body of the profession. When this has been accomplished and the better knowledge of these processes has become generally diffused, the treatment of dental caries will be far more successful than it is to-day. The dentists of the future must have this information. The prophylactic treatment, or systematized cleaning, for prevention of caries of the teeth, which is claiming attention just now, can not be wisely done without a closer study of the conditions that cause the beginnings and the localizations of decay, and of the signs of susceptibility and immunity. The existence of these later conditions, as now understood, has been recognized so recently that, as yet, no common technical language has been developed by which the symptoms of coming immunity can be adequately described. Indications are pointing, however, to means of doing this in the early future which will give a more

definite phase to prophylaxis as applied to dental caries. The complete divorcement of dental practice from studies of the pathology of dental caries, which has existed in the past, is an anomaly in science that should not continue. It has the tendency plainly apparent to make dentists mechanics only.

Vital Phenomena in Caries.

ILLUSTRATIONS: FIGURES 159-161.

Because of the fact that the teeth are vital, it has been contended that vital influences play a very important part in caries. This idea, however, has been gradually disappearing for the last seventy-five years, and but little of it is seen in our literature of to-day. We must not conclude from this that the teeth are not vital, that they are not living tissue. Teeth that have lost their pulps, the dentin of which has lost its vitality, decay the same as teeth with living dentin. This was disputed for many years, and the opinion asserted that the decay in teeth that had lost their pulps was of a different character from that occurring in teeth with living pulps. This also has been definitely given up and has disappeared from the recent literature. To-day, the vitality of the teeth is not regarded as influencing caries in any considerable degree. Caries progresses the same in teeth with living pulps as in teeth with dead pulps. Some thought decay was more rapid in teeth with dead pulps, others have disputed it; certainly there is no difference worth contention.

Generally, caries of the teeth progresses without pain until such a penetration of dentin has been reached that the pulp of the tooth becomes hypersensitive on account of irritation of its tissue. While this is the general rule, not a few persons complain of more or less pain or of an itching sensation almost as soon as the enamel has been penetrated, and the examination of such cavities with an instrument point develops the fact that they are sensitive to any mechanical interference. Other persons have no perception of anything going wrong in a decaying tooth until they notice that a cavity has formed. There has been no pain or other noticeable sensation because of caries of the dentin; this is the general rule. Sensitiveness in the early stages of caries, without some mechanical disturbance to arouse it, is the exception, though it is by no means rare.

The rule is, that all progressive decays in teeth with living pulps are sensitive to any form of mechanical interference, such as probing with a sharp explorer, or to the use of cutting instru-

ments. This sensitiveness varies greatly in different persons and in different carious cavities in the teeth of the same person. Therefore, we may recognize subnormal, normal and hypernormal sensitiveness. Similar grades of sensitiveness will be found if we cut into the dentin of perfectly normal teeth free from all decay. The great variety of grade of sensitiveness in normal healthy dentin has seemed to me very remarkable. Some persons have cut into so many teeth that, apparently, were not sensitive at all, that they have expressed a doubt as to whether a tooth that was perfectly normal was sensitive. Even in these cases of failure to find sensation at a first cutting, sensation is usually aroused and it may soon pass the normal point and become hypersensitiveness.

Sensitiveness to cutting instruments is not materially different in carious teeth from normal sensitiveness of dentin, only that, in a long run of cases, it will be found somewhat greater for equal areas. Those who have had some experience in removing enamel from living teeth in the preparation of abutments for bridges, have found that a high degree of sensitiveness has been quickly developed in a large proportion of cases. This is so general and creates so much difficulty that most dentists prefer to destroy and remove the pulp before beginning this preparation. Sensitiveness in carious teeth is not greater; it seems to be subject to the same degree of increase under similar treatment. Well planned and firm work with sharp cutting instruments arouses the least sensitiveness; dull instruments arouse much more sensitiveness than sharp ones; burs arouse much more than hand instruments, and grinding with stones more than any other form of cutting.

Sensitiveness of dentin is greatest along the dento-enamel junction, where the fibrils are much branched, and diminishes perceptibly in the deeper parts. For this reason, practically the whole work of removing the enamel cap, as in preparing abutments for bridges, is cutting in the area of most acute sensitiveness. For the same reason, broad, shallow areas of decay, such as are often found in labial and buccal surfaces, are more sensitive than those of deeper penetration and less superficial breadth. In any and all cavities, the more sensitive areas are along the dento-enamel junction about the circumference. In a few positions the form of the finished cavity will permit of cutting off the fibrils supplying such a part deeper in the dentin, and save considerable pain to the patient. A good knowledge of the histological structure will always indicate these in the particular

cases in which they occur. It is difficult to understand the wide variations of sensitiveness that occur in different cases, sometimes between teeth in the same mouth, but more commonly between the teeth of different persons. Occasionally, we may find that much of this apparent difference between persons is a difference in the disposition, or ability to endure pain. Apart from that, however, there is a real and tangible difference among persons in the sensitiveness of dentin. The teeth of some persons are extremely sensitive, no matter when or how they are cut, while the teeth of others are not.

The rule is that sensitiveness of the dentin to cutting instruments indicates no especial danger to the pulp of the tooth, no matter how extreme it may seem at the moment. Generally, it is all over the moment the cutting is done. More rarely distinct pain is felt for some time after the cutting is finished. Danger to the pulp is indicated, however, when there is much mutilation of the tooth, as by cutting away the enamel with a considerable amount of dentin over wide areas, as is often done in preparing teeth for abutments of bridges. Distinct hypersensitiveness of the pulp tissue itself is developed and also, in many cases, thermal sensitiveness and hyperæmia, which may seriously endanger the life of the pulp.

Sensation in dentin is derived from the dentinal fibrils. The dentin has no nerves. Sensation is conveyed by the fibrils. Whenever those of any part are cut off, the dentin, to which the severed fibrils are distributed, loses sensation at once. These fibrils are not simply glue-giving fibers, such as the fibers of ordinary connective tissue, but are prolongations from the odontoblasts and are probably formed of the same material as the nuclei of these cells. I have removed the fibrils from the dentinal tubules for a considerable length and stained them together with the odontoblasts to which they belonged, and found them to have the same reaction to staining agents as the nuclei of these cells. Röse has examined this point with great care and expresses the opinion that the fibrils are not glue-giving material, as are ordinary fibers, but, chemically, are closely allied to nuclein. We conclude, therefore, that the dentinal fibril is a most highly endowed, living, functionating tissue, really a part of the odontoblast — a prolongation of its nuclein and a functioning part of it. Therefore, when we have touched a dentinal fibril, we have touched the prolongation of an odontoblast, a living part of the cell itself. The odontoblasts are in physiological relation to nerve endings, as has been demonstrated by many



Fig. 159.

Fig. 159. A diagram illustrating sensation without nerves in the dentin. E. Enamel. D. Dentin. O. Layer of odontoblasts. P. Pulp of tooth with nerve endings in physiological connection with the odontoblasts. The fibrils of the dentin are prolongations of the odontoblasts. Any injury to them is an injury to a portion of the odontoblasts and is transmitted by the nerves to the brain.

authorities, hence the sensation arising from an injury to a dentinal fibril is transmitted to the brain and registered as pain. This is illustrated in the diagram, Figure 159. An injury to dentinal fibrils near the enamel, E, is transmitted through the thickness of the dentin, D, to the odontoblasts, O, without nerves, because the cell is continuous through the dentin. The impression is then transmitted to the proper conveyors of sensation — the nerves in the pulp, P, and by them to the brain.

Sensation is a function of living cells especially. Nerves, while they may have sensation of themselves, as other living tissue, are, functionally, the conveyors of sensation from, or impulses to, the cellular elements of the body. An injury to a sensitive nerve trunk is usually represented in the sensorium as coming from the tissue to which its fibers are distributed. Most persons have felt the shock of an injury to the ulnar nerve in the little finger and the half of the third finger next to it, when they have struck the so-called "crazy bone" near the elbow. This is because the nerve injured is distributed to these parts. Impulses are conveyed outward by motor nerves, the same as the impressions of pain or touch are conveyed inward by sensory nerves. A muscular fiber is often very long, yet there is generally but a single nerve plate, or nerve ending, on a muscular fiber. An impulse through that nerve plate may, however, set the whole length of the muscular fiber into contraction. This is the analogue of the transmission of the sense of pain through the thickness of the dentin without nerves.

Besides the sensory function, the dentinal fibrils have also the function of the maintenance of the integrity and qualities of the dentin. It goes no farther than this. The dentin has no reparative functions. The fibrils, though highly endowed with sensation, do not exhibit any function of repair. But that there is a power of maintenance of the qualities of the dentin, seems clear from clinical evidence. There is a slow but distinct deterioration in the qualities of the dentin in pulpless teeth, which is too apparent to escape the clinical observation of a close observer of long experience. This becomes especially apparent in careful laboratory study. The enamel is much easier to split off from the dentin in teeth that have long been pulpless. The dentin very slowly loses strength as compared with neighboring living teeth from the same or other mouths. It loses much of its translucency, loses elasticity and becomes more brittle. The younger the person at the time of the loss of the pulp, the more rapidly these changes occur. This occurs, however, much less

rapidly in teeth that have been so treated and filled that no septic matter, saliva, or other extraneous decomposable material has reached the dentin, than in those in which the dentin has been exposed to such material. This much has been clearly shown by my own examinations of the physical characters of the teeth. In cases in which there is much abrasion, deposits of secondary dentin on the walls of the pulp chamber often obliterate, or very nearly obliterate, the crown portion of the pulp. The pulpal ends of the dentinal tubules are closed, cutting off the fibrils of the crown of the tooth from the pulp. Figures 160, 161. Where this is complete, as often occurs, the crown of the tooth has lost its vitality and undergoes degeneration, the same as in teeth that have lost their pulps. Often the deterioration will be greater in these, because, apparently, of the wide area of dentin exposed to the fluids of the mouth. A perfect enamel covering, or, in case of a cavity, a perfect filling, serves to limit deterioration. Filling operations in such teeth should always be conducted on the hypothesis that they are, or will become, less strong than normal.

How, when and by what agency are the dentinal fibrils destroyed in dental caries? This question has often been asked and variously answered, but I know of no answer based upon evidence that seems to me conclusive. My own conclusion, derived from combined clinical and laboratory study, has been that the fibrils are practically destroyed between the line of beginning solution of calcium salts and the invasion of microorganisms. In other words, that the death of the fibrils is not the result of actual contact of organisms, but always a little in advance of them. Also that many of the fibrils — not all — are destroyed for a considerable distance in advance of the softening process, or even to the pulp itself, and that this, in some way, produces the flamelike cloud or hyaline area of Tomes, streaking away toward the pulp from a carious area. This whole subject, however, will require much close investigation before it is satisfactorily made out.

OBTUNDING SENSITIVE DENTIN.

The treatment of sensitive dentin for the purpose of relieving or limiting the pain in the excavation of cavities, has been prominently before the dental profession since the first discovery of anæsthesia, and, perhaps, for many years before that time. Personally, I have watched the progress of this effort through

FIG. 160.

FIG. 161.

FIGS. 160, 161. Photographs of split incisors that have been badly abraided. In Figure 160 the outlines of what was the pulp chamber are sharply apparent in the incisal portion, but the whole pulp chamber is solidly filled with a calcific deposit which has obliterated the dentinal tubules, cutting off all connection of the dentinal fibrils with the pulp of the tooth. This has destroyed the vitality of the crown of the tooth and obliterated all sensation in the dentin. In Figure 161 there is very nearly the same condition, but in the light line in the central portion of the pulp canal there was a shred of living pulp tissue that may, or may not, have retained connection with a few of the dentinal fibrils of the crown of the tooth.

many years of what has been fairly close, careful observation in clinical practice, and always with an earnest desire to relieve patients of suffering in the necessary cutting in the preparation of cavities. In all of this time, and up to the present, the results have been so poor, or so uncertain, that, as compared with skillful use of well-selected cutting instruments, well tempered and always sharp, they have not been a success. I do not mean to say by this that pain has not been obtunded and made less severe. But, through fussing with such obtundants as have been used, the dissipation of energy by the operator, the repetition of partial failure and disappointment to the patient, the increased time employed, and, finally, the amount of injury that has been done, prompts me to say that thus far the operator of fair skill will do his patient the better service if he lets obtundants alone almost entirely. Thus far, the man who bends his energies to developing the most thorough systemization of the use of cutting instruments and personal skill in controlling patients suffering pain, will dismiss his patient at the end of an operation in better condition than he could possibly do with the use of any local or general obtundant at present known.

In saying this, I am not unmindful of the apparent fact that a few men have seemed, personally, to have developed a very successful use of some particular form of obtundant and seem to have done much good by its use. Many will remember the great craze caused by the introduction of cataphoresis — the electric application of cocain — to this purpose a few years ago. It was shown conclusively that pain could be relieved, or even abolished by this method, and thousands of men were sending orders for the necessary apparatus. Soon it was found that in the hands of the average man, or even of those much above the average, great harm was being done which far outweighed the advantages. Under the stimulus of demand, manufacturers had turned out an immense supply of the apparatus that became so much junk, practically, over night. Yet, I know a few men who used and are still using that method to great advantage and without the evil results that have befallen most men who undertook its use. But it was incapable of assimilation by the mass of even the better professional men.

Other obtundants have been heralded, with less ostentation, perhaps have been tried by hundreds of dentists and then faded out of the memory of men. Such has been the fate of every obtundant for sensitive dentin, except a few now on trial, that has come forward during seventy or more years of dental prac-

tice. But the relief of suffering is an ever-present duty and the search for this very desirable thing should continue.

THERMAL SENSITIVENESS.

The consideration of thermal sensitiveness more properly belongs to special pathology and therapeutics, but it is so closely interwoven with the management of cases in filling teeth that it is necessary to consider it here. Thermal sensitiveness is a peculiar painful sensation in the teeth caused by changes of temperature. This may be illustrated by taking ice-water in the mouth and letting it come suddenly in full contact with the teeth. This causes sharp pain, lasting only a moment, the character of which is well known from personal experience by most persons. This is peculiar to the teeth, no other tissue in the body, no other organ, showing a like resistance to thermal changes. This is normal. Under certain conditions, this becomes a hypersensitiveness to thermal changes; it becomes augmented and becomes a pathological condition. The actual condition in this case is a hyperemia of the pulp. There is an injury to the walls of the veins, particularly, and, to some extent, to the arterioles of the pulp, by which they become very much dilated; indeed, each manifestation of pain in this way is brought about by a dilation of the blood vessels of the pulp and forcing of an extra quantity of blood into them. When the walls of the vessels become so injured that they are more readily expanded than normal, this becomes a pathological condition and every slight change of temperature produces a paroxysm of pain. This is called thermal sensitiveness. It is entirely separate and distinct from sensitiveness of dentin. We may have sensitive dentin existing and continuing for a long time without any particular thermal sensitiveness, or we may have thermal sensitiveness without abnormal sensitiveness of the dentin, or we may have the two existing together. They are distinct conditions.

Thermal sensitiveness may be aroused in many different ways. It is sometimes caused in the incisor teeth by the heat of a cigar in smoking; it may be caused suddenly by an extraordinary exposure to cold, as ice-water; it may be caused suddenly by exposure to hot drinks, and the dentist may develop it suddenly by the heat of a disk in finishing a filling, or the heat of a bur in excavating in any tooth that has a living pulp. Often thermal sensitiveness is aroused during the progress of decay, especially when the decay has reached the neighborhood of the pulp, sometimes when the decay has not nearly reached

the pulp, and the patient will have paroxysms of pain from every exposure to thermal changes. Usually these pass away quickly. As it becomes worse, the paroxysms of pain will continue longer. This continuation of the paroxysms of pain marks the severity of the case, and, finally, if it continues to grow worse, the patient will have pain when lying down, will have pain at night; the difference in blood pressure between the horizontal position and the upright position will be sufficient to determine a condition of pain. Cases occur occasionally in which a stream of water three degrees off either way from the normal temperature of the body will induce excruciating pain.

In the management of cases, it is of the utmost importance that we recognize what may occur, and exercise due caution in the use of disks, whether dry or lubricated, stones even when wet, or in running burs too long or too rapidly in excavating, or any of these things that are calculated to produce heat which may suddenly precipitate a condition of hyperemia of the pulp or thermal sensitiveness.

There is only one thing to do in the treatment, and that is to protect the case as absolutely as possible from thermal changes until it recovers. This may be done in various ways. In some of the worst cases, caps of gutta-percha may be put over the teeth involved, covering them in completely, particularly for persons who must be out in the cold air. Patients may protect the teeth from thermal changes; they may avoid cold or hot drinks; they may avoid cold or hot foods; they may avoid breathing through the mouth when out of doors in cold weather, and, in this way, protect the teeth. This is very much the best way to protect them from thermal changes. Gutta-percha caps over the teeth will be very annoying, and it is often difficult to induce patients to wear them. A thing that seems so simple to do often becomes very annoying because of failure. But the fact is that, in moments of freedom from pain, patients forget and in an unguarded moment precipitate another paroxysm of pain.

Cases of very severe thermal sensitiveness will generally get well promptly, or within a week or ten days, if properly protected. Sometimes, however, it may require more time, and whenever we find thermal sensitiveness developed to any extraordinary degree so as to be very annoying, we should desist from all operations upon the tooth involved, except those calculated to mitigate this condition. If it has occurred from a cavity of decay, it is best to remove all decayed dentin com-

pletely so as to remove the irritants in the decaying mass. When the cavity is prepared, it should not receive a metallic filling, but a temporary filling of gutta-percha, which should be a tight filling. The walls should be dried first, as dry as absorbent cotton will make them; they should then be moistened slightly with eucalyptol, so that the gutta-percha will adhere and make the filling tight. This is the best treatment, for gutta-percha is the best nonconductor we have with which to make these temporary fillings. A gold filling at such a time would be contra-indicated, because it so readily conducts thermal changes. Time should be allowed for the sensitiveness to disappear before making any other operations upon the tooth, and, if the condition is severe, all operations in the mouth should be omitted until that tooth shall have recovered; or, at least, any operations that are not absolutely necessary at the time.

This condition often ends in death of the pulp from strangulation, which leads to infarction. To-day the tooth may be extremely sensitive to thermal changes; to-morrow the pulp may be dead and this sensitiveness may have disappeared completely. The sudden disappearance of this thermal sensitiveness marks certainly the death of the pulp, and when the pulp of a tooth has died under these conditions, it is of extra importance that it be removed as quickly as possible. There is more blood than normal in the pulp at the time of its death and the blood globules are very liable to be broken up and the hemoglobin set free in solution. This may penetrate the dentinal tubules in every direction, a red color appearing through the enamel. Such a tooth is likely to become very dark in time, and it is especially difficult to bleach it. Early removal is also important for the reason that pericementitis, and possibly alveolar abscess, may soon develop after the pulp has died. This condition of thermal sensitiveness will come up continually in the cases in practice, and require treatment along with the other items in the management of conditions in filling operations.

MANAGEMENT OF PATIENTS.

In dentistry there is nothing more important than the development of skill in the management of people in their sufferings, or in so managing patients as to gain the opportunity to do that which is necessary and best for them and to do operations in the best way. A student came to me and complained that he could not place the rubber dam for a lady in his chair, stating that she could not bear to have it in her mouth. I went to the patient, spoke a few encouraging words, and started to place the rubber dam. There was some spasmodic retching, which I assured her would pass away in a moment. Then I finished placing the dam without apparent discomfort to her. There was nothing wrong with the patient, except that she had come with a prejudice toward the rubber dam that needed to be recognized and overcome. Patients will have their little prejudices and notions that interfere with their comfort and with the performance of necessary operations for their benefit. The dentist should learn to appreciate these quickly and develop the tact to smooth them away. The management of these is not well within our power to teach with any set of maxims or rules. Men of widely different temperament and trend of thought seem to manage people equally well. But in all there is a feeling of profound respect for people in suffering and an earnest desire to aid them, which serves as the basis of thought and action. With such a basis, and a careful study of mental states and qualities of mind, of conditions and impulses that move men, or influence people's thought, one should succeed. It sometimes seems to be more important that the dentist should begin his professional work with a well grounded notion of the humanities and of the psychic nature of man than the devotees of any other profession. The nature of his calling keeps him indoors — secludes him from the more general social and semi-professional mixture with people; he is confined with one patient at a time day after day. The physician is going hither and yon, mingling with people socially, semi-professionally or professionally continuously; he has the opportunity of studying the psychic conditions in those whom he meets tenfold more than the dentist. Yet the dentist needs such information of people, and the impulses that move them to action in this direction or that, that he will be able to read in their actions the manner of approach that will influence the

particular person best, or place him or her in a state of mind that will give the opportunity to do dental operations to the best advantage and greatest good to the patient. This requires a close sympathy of mind with mind, a development of confidence on the part of both operator and patient, a matter that every dentist should cultivate with great care.

The dentist has a duty also as a teacher while doing his duty as an operator. His professional life should be an exhibit of the helpfulness that earnest dentistry can be to his community. This gives him power for good. Aside from this, he should in his daily office work be continually but judiciously giving information regarding dentistry that will be helpful in developing the ability of people to make the best use of dentistry. To-day only about fourteen per cent of the people of America employ dentists or make any intelligent use of dentistry. Still, no other country has done as well. We can and will do better, and every dentist has a duty in furthering the information of the people to this end. This he can do best in his professional intercourse with patients in his own office by giving judicious and careful advice that will be helpful on any points that may come up. That which proves helpful to one person will gradually be disseminated to others, and, in time, the whole community will be benefited and will make a wiser and better use of dentistry. Much more good is done through these bits of information thus given in a careful manner at proper times than can be imparted in any amount of printed matter, however wisely written, intended to give the people information as to the care of their teeth.

Cleanliness.

Cleaning which patients should do for themselves. One of the important features of the management of a practice is the management of the artificial cleaning of patients' mouths, or instruction of patients in the use of the brush, the toothpick, silk floss, rubber bands, etc., and the recognition of conditions under which these should be used. Persons will be found who have no use for any of these things, persons whose mouths will be clean without them. Examine them before breakfast, after breakfast, or any other time of day, and the mouth will be found clean, there will be no lodgments of food, there will be no debris about the teeth. They have no use for tooth brushes, they have no use for toothpicks or any of these affairs for artificial cleaning. Such mouths are practically perfect; the health of the

person is generally good, there is immunity from decay and they go along, possibly through life, without any need for artificial cleaning. There are no deposits from the saliva of these persons, their saliva is thin and watery and seems to dissolve and remove the last trace of debris. But such perfect conditions are the exception to the rule.

The tooth brush. Most persons need to use the tooth brush, and it becomes the duty of the dentist to prescribe the manner of its use; not only to prescribe the manner of use, but to teach his patients the correct use of the brush. Nearly every person who uses the brush will fall into certain fixed habits. Some will take the brush and make a few strokes in this direction or that, and are done. They have brushed their teeth, and they will tell you very conscientiously that they have brushed them carefully. Others will use the brush vigorously. They form the habit of going through certain motions. An examination will show the cleaning to be very imperfect in that certain parts are missed and not cleaned at all. Make it a rule to say to little patients, "The next time you come, bring your brush with you; I want to see how you brush your teeth." They will generally do it very carefully, better than they do it at home; or some will and some will not. Impress in some way the lesson that it is necessary for them to do this thing carefully, and then prescribe the method of doing it. One may brush the buccal surfaces of the teeth with a back-and-forward motion, but this will not brush the embrasures well; the bristles of the brush will not get in toward the proximal surfaces of the teeth. Teach patients to use the up-and-down motion along the length of the teeth; the bristles of the brush will go into the embrasures and clean the surfaces close to the contact points when used in this way. This may be done all over the mouth. It is just as easy a motion as the other when once learned. The manner of brushing will depend a good deal upon the tendencies in the case. Children and young people particularly, should brush their teeth with this up-and-down motion, for the tendency in them is usually for the formation of proximal cavities. As they come to adult age, there is more necessity for brushing the buccal surfaces; they are more liable to be developing gingival third cavities. If patients are found with a tendency to the development of gingival third cavities, the back-and-forth motion becomes the important method of brushing, because it cleans the portions of the surfaces of the teeth that are then most liable to decay. Wherever patients show a tendency to buccal decays, say to them, "By

care in brushing you may avoid other cavities in similar positions, for this is a part of the tooth that you can clean, and, if you do it well, you will stop all of the tendency to decay in these surfaces." These surfaces are in positions that can be reached and can be cleaned perfectly with the brush and water without other aids. Caries will not begin on well-cleaned surfaces of the teeth. If there is any one fact regarding decay of the teeth that is well fixed by careful clinical observation, it is this one. Of all the surfaces of the teeth, the buccal and labial surfaces are cleaned with the brush the easiest and most perfectly. To do this properly, however, the brush must be used so that the teeth will be well brushed fully to the free margins of the gums. Proximal surfaces or fissures can not be perfectly cleaned with a brush. The cleaning of the lingual surfaces is mostly for the purpose of preventing disease of the gums. One can run around all of these surfaces with a motion very nearly lengthwise the arch with an ordinary tooth brush. Only the lower second and third molars will need a diagonal motion. There are very few persons who need other than the ordinary straight tooth brush. A cheap tooth brush is generally the best tooth brush, because it is small, there are not so many bristles in it, and they will get in between the teeth better.

The frequency of using the brush is an important item. This should be regulated somewhat by the needs of the particular person. Some persons do not need to use a brush. On account of our artificial manner of preparing food, we do not make that use of the teeth that Nature seems to have intended. If patients form the habit of using the brush, they will, once the habit becomes fixed, prefer to do it. It is necessary, however, for the dentist to watch them carefully until this becomes a fixed habit. In persons where the susceptibility to caries is not great, moderate use of the brush is sufficient; in fact, many persons, if they use the brush once a day, will do well and will perhaps have no necessity for using it more frequently, but the habit of using the brush after each meal is the best. This is sufficient to keep off calculus and keep the gums in condition; but where we use the brush as a prophylactic against caries of the teeth, and especially where the tendency to caries is very considerable, the brush ought to be used as often as four times per day — after each meal and at night before retiring. This frequency is necessary to prevent the formation of colonies of microörganisms, or microbic plaques in positions reached by the brush. If it does not entirely prevent proximal decay, it will materially lessen

the bucco-lingual breadth of the decay, and in filling these cavities for those who have this habit well fixed, the necessity for breadth of cutting in extension for prevention will not be so great, because cleanliness extends deeper into the embrasures.

We sometimes hear of the brush doing injury to the teeth. It does not seem possible that the brush, used with water only, will do injury to the hard tissues of the teeth. In some cases it has appeared as though the brush might be responsible for injury to the teeth near the gum margin, but other cases where the brush had not been used at all are so nearly like these as to show that the injury had not been done by severe brushing. Sometimes it would seem that the gum had been torn, lacerated and caused to recede, particularly from the upper cuspid teeth on the labial surface. It would seem that we might easily injure the gums in this position and cause a recession by the too vigorous use of a stiff brush; and yet, again, many cases of apparently the same kind of recession appear where a brush has not been used. This brings us to doubt whether even this has been caused by the too vigorous use of the brush. In a number of these cases it was found that the patient failed to brush these points. Yet the dentist should have a care about the vigorous use of a very stiff brush if he saw a tendency to this kind of recession; in fact, it is not well to use a very stiff tooth brush in any case; a brush with comparatively few bristles, the bristles being sufficiently strong, but not so many of them as to make it very stiff and harsh, is better. Injury by the vigorous use of such a tooth brush is not to be feared. A few persons will be met with who state that they use the brush several times a day for ten or even fifteen minutes. This is too much and should be moderated. Any one ought to do sufficient brushing in from two to five minutes.

Mouth washes, tooth powders, etc. What mouth wash should be used with the brush? What the mouth wash is, is not important. Plain water answers a good purpose and is sufficient, but it is often a valuable point to prescribe some particular mouth wash for this or that person. If it does no other good, it seems to have an influence in inducing patients to use the brush. Many persons have more confidence in the use of some wash of this kind than they have in the mechanical cleaning, and wherever a mouth wash will do good in this way it should be prescribed. But never prescribe any tooth powder, or tooth paste, or other mixture that contains any kind of grit. Dr. W. D. Miller's report of his experimental

work on erosion shows clearly that these may do harm, and also that many of the tooth powders offered on the market contain much grit. It is best not to prescribe any kind of tooth powder. We can not render the mouth aseptic by the use of any of the antiseptic mouth washes. This has been tried very thoroughly by Dr. Miller. He reports that he was unable to render his own mouth aseptic. He could remove most of the microörganisms for the time being, but in a few hours they would be as plentiful in the mouth as before. My own experiments have given similar results. The most we can do is to eliminate those not habitual in the mouth. Most of the microörganisms that are not habitual in the mouth, i. e., whose natural habitat is not in the mouth, can be effectually removed by the use of antiseptic mouth washes, coupled with vigorous mechanical cleaning. The same can be done just as well, probably, by the mechanical cleaning alone. I have found that the pus microörganisms, the staphylococci, except the one white staphylococcus which is habitual in the mouth, could be very effectually removed by the use of the brush. I have tried this with nurses in the hospitals who were dressing suppurating wounds. Nurses who were dressing suppurating wounds generally had pus microörganisms in their saliva before the closer drill of recent years taught them better plans of aseptic and antiseptic work. These can be very effectually removed within a few days so that we will be unable to find pus microöorganisms in the mouths of these persons in plant after plant. If they are taught especial care as to reinfection, their mouths can be kept fairly free from pus microörganisms or other pathogenic microörganisms, except those whose natural habitat is the mouth. These we are utterly unable to effectively remove. Of course, the harmless saprophites floating in the atmosphere are continually being caught in the saliva, and it is soon reinfected with them. These are of no consequence.

THE TOOTHPICK, LIGATURE, TAPE AND RUBBER BANDS. As the proximal surfaces of the teeth can not be cleaned with the brush, it is necessary to use other means, and the ordinary rubber bands and the silk floss are best. One may carry a ball or a disk of silk floss in his pocket, or have one on his dresser, or may carry a few small rubber bands. They are cheap and may be used and thrown away. The rubber band is perhaps better and easier handled than the silk floss for cleaning the proximal surfaces. It is a very simple matter to use it; pass the rubber band into the interproximal space, bring it against the distal surface of one tooth, well under the gingivæ, rub that

back and forth, bringing it out at the occlusal; then against the mesial surface of the next tooth, and so on around the arch. Generally, it is a pretty difficult thing to get patients to clean all of the proximal surfaces. If it is a full denture, there are sixty-four surfaces to clean; it requires sixty-four distinct motions to go around the arch and clean all of these surfaces. It is a simple matter to clean one or two or three, but to get the patient to clean all of them and do it regularly is quite another matter. It takes a little time, not very much; but to form the habit in such a way as to clean every proximal surface is difficult, and very few persons accomplish it completely for any considerable length of time.

Perhaps the use of toothpicks is the most common method of cleaning proximal surfaces, but the toothpick, as it is habitually used, removes only lodgments of food. With the toothpick, however, the proximal surfaces may be pretty thoroughly cleaned; microbic plaques that have been formed upon these surfaces can be removed, but generally it is very imperfectly done. For this purpose the quill toothpick is much better than the ordinary wooden toothpick. Nowadays machinery has been made for making the wooden toothpicks and large factories are established for the purpose, and they have become so very cheap that every one may use them. But the wooden toothpicks that come to us are not always perfectly smooth. There is more or less slivering of the wood in many of them, and we are liable, in using these toothpicks, to leave little slivers of wood in the gum tissue that do injury. A good many cases of injury are caused by forcing spiculæ of wood into the peridental membrane between the tooth and its alveolar wall, causing soreness and suppuration. However, some wooden toothpicks are made very smooth and very nice; but, upon the whole, the quill toothpicks are very much the better to use; they will get into places where the wooden toothpicks will not reach and will clean the surfaces better.

The difference in persons as to the need of toothpicks is very great indeed. Most young people have very little use for the toothpick, if their teeth are well formed, if the proximal contacts are good. The rubber band is much better. Wherever lodgments occur, the person should be instructed to use the toothpick and to use it regularly after each meal. Persons who habitually have lodgments between their teeth are very liable to neglect them; the lodgment from one meal remains until the next meal, and that original lodgment is forced farther

on to the gum tissue and a new lodgment occurs, and this continues meal after meal, day after day, until the gum tissue is pushed aside, and a great pocket is formed between the teeth. If this food lies continually between the teeth, fermentation will go on, giving rise, perhaps to caries; or putrefactive decomposition may occur with disease of the peridental membrane. Many cases of disease of the gums are begun in that way, and the dentist should guard this point very carefully.

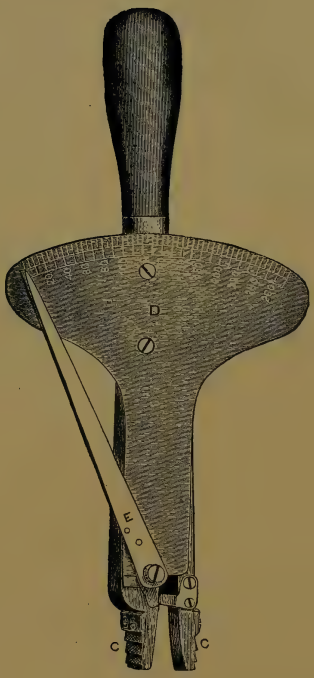

FIG. 162.

FIG. 162. The gnathodynamometer, about two-thirds natural size. Face view. C, C. The rubber pads bitten upon in determining the pressure of the teeth. D. Scale of pounds. E. Needle which marks the pounds. In use this needle remains stationary at the highest point reached until it is moved by the fingers.

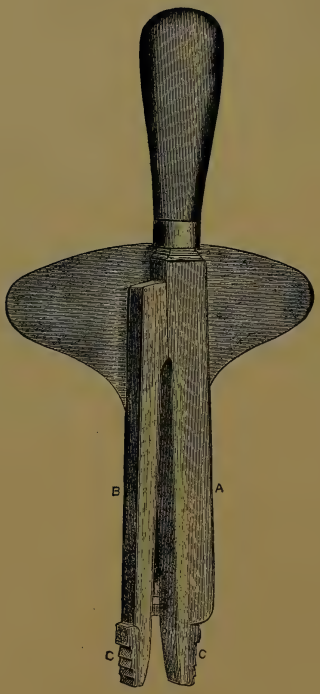

Fig. 163.

Fig. 163. The back view of the gnathodynamometer. A. The rigid bar. B. The spring bar. C, C. The rubber pads bitten upon in determining the pressure of the teeth.



FIG. 164.

FIG. 164. The dynamometer with micrometer attachment. A. The register dial. B. Part of the apparatus beneath the register dial which moves the fingers S, S, when the double bow spring C, C, is compressed by turning the screw D. The index hand S, carries the marker hand S — the one with the slender point — around with it, and if the substance to which pressure is applied suddenly gives way, the marker hand remains at the highest register. K. The micrometer dial. A rod from the spring C, C, passes under the micrometer dial K, and abuts by suitable exchangeable points for different purposes with the squared end of the screw J, which passes through the stop G. See Figure 165. The dial hand N, of the micrometer is thrown out of commission by the lever O, when not needed, or with screw D, turned back, the points are opened with lever O to place a substance between them. In order to determine the number of pounds a block of dentin, or other substance, will bear without crushing, the points of the rod from the spring C, C, that passes under the micrometer dial K, and abuts with the screw J, are thrown back as seen in Figure 165 and the block placed between them. Then pressure is turned on with the screw D. This compresses the spring C, C, which carries the hands S, S, around the dial plate A, showing the number of pounds. In case it is desired to note the compression of the block at any given pressure in pounds, the hand N, on the micrometer dial is placed in commission at the beginning. Its movement will show the compression in thousandths of an inch. This hand also has a marker hand directly under it — in the picture — which remains in position, making the starting point. The length of the frame on which the instrument is mounted is thirteen inches.



FIG. 165.

FIG. 165. The dynamometer with micrometer attachment with the micrometer dial removed to show the rod E, which passes under it, and the cog bar B, that controls the hands of the dial A.

THE FORCE USED IN MASTICATION IN RELATION TO THE STRENGTH AND HEALTH OF THE PERIDENTAL MEMBRANE.

The Force Used in Chewing Foods.

ILLUSTRATIONS: FIGURES 162-165.

Until recently there was no accurate knowledge of the force used in mastication. Inquiry was begun in 1893, and in my articles on "Physical Characters of the Human Teeth," etc. (*Dental Cosmos*, 1895), a pretty full exhibit of the subject was given. Since that time, the subject has frequently been under investigation. The results then given underwent severe questioning, but have not been materially changed by further examination. There have, however, been published some results obtained with rudely constructed instruments that have been different, evidently through inaccuracy of observation, and others apparently different through misconceptions of the nature or of the condition of material used.

The force of the bite, or the pounds force with which the jaws may be closed upon any object, varies greatly among different persons, and is dependent in larger degree upon the condition of the peridental membranes and upon personal habits in the use of the teeth in mastication than upon muscular power. It has been my habit to make a trial of the force of the bite every year among the students of my classes and record the results. In these tests a familiarity with the instrument was brought out and rivalry was pretty sure to occur among those of the highest strength which served to develop the full power of the occlusion. In a tabulation of results in one thousand persons, the average force exerted was 171 pounds on the molar teeth, and considerably less on bicuspids and incisors. In this, there was no selection of persons, further than a careful exclusion from the trials of persons whose teeth were so badly weakened by caries as to cause danger of injury by breakage. In spite of this prohibition, there were a few accidents to cusps of teeth that had very large fillings. The variation was from 25 pounds to 275 pounds. Two hundred and seventy-five pounds is the full register of the instrument used and among the trials there were seventeen persons who made this full register. A

number of these could have registered a greater number of pounds. The instrument used is called the gnathodynamometer. Figures 162, 163. A variation from accuracy of results occurs from biting very close to the end of the rubber pads, or from catching too far from the ends, which may altogether produce an error of about ten per cent. With this exception, the instrument is as accurate as ordinary spring scales. In these trials, the instrument generally rests on two teeth in one jaw and but one in the other. It is only occasionally that it can be so placed as to rest fairly on two teeth in each jaw.

The force of the bite of an individual is modified very materially (1) by the use habitually made of the teeth, (2) by the loss of the pulp, (3) by disease of the peridental membranes. Nearly every one who makes trial of his bite on the gnathodynamometer stops because of pain in the peridental membranes rather than from having reached the full limit of muscular effort. Therefore, modification of the condition of these membranes is prominently brought out. Full and free use of the teeth in mastication, and especially the disposition to use them freely on hard foods, contributes to strength. Any considerable limitation of the use of the teeth, for even a few days, shows in tenderness of the peridental membranes, and, in cases where the person has fallen into the habit of swallowing food practically without mastication, the power of the bite will be found as low as fifty pounds, or even lower. Any considerable pressure causes pain. Very marked cases of this loss of power occasionally occur where persons have fallen into the habit of disuse of the teeth because of exposure of the pulp in one or two teeth, which causes pain that prevents them from chewing their food. In such cases, bolting of food is liable to become habitual. This condition is readily recovered from by careful training.

In disease affecting the peridental membranes, the power of the occlusion is rapidly reduced; that is, the muscles of mastication are held from exerting their full power by pain warning them to go no farther. A tooth from which the pulp has been removed seems never again to completely recover. Even though the person has not recognized the difference in the ordinary use of the teeth, it shows in these trials. The difference is generally considerable, but there are wide variations.

Therefore, the limitations of the force of the occlusion as shown by the gnathodynamometer is a register of the power of resistance by the peridental membranes and not a register of possible muscular exertion. Only a few instances have come

to my attention in which I was satisfied that the full capability of the muscles had been registered. The most notable of these was a young man, who, for some years, had made a business of crushing glass and other hard, brittle substances with his teeth, as a show, for a living. He was a slender fellow with no considerable muscular strength. He could register 215 pounds and would stop at that every day very precisely in each trial for a week. He claimed stoutly that he used all the muscular power he was capable of without the slightest pain about the teeth. I am inclined to believe his statement. He was much chagrined to find others registering more pounds than he, "a professional hard biter," could do.

The strength of the teeth is ample for all the stress that is brought against them, provided very hard substances are excluded, such as the harder metals, pebbles and similar things. This is made clear by trials of the strength of freshly extracted teeth. These were cut squarely off at the junction of the middle and gingival third of the crown, so that the occlusal portion would stand solidly on a flat piece of steel, and arranged in a registering dynamometer. Figures 164, 165. Then a steel point with a squared end was applied directly to the cusp and pressure slowly turned on. Another test was made in the same way, except that a slip of hard vulcanized rubber three thirty-seconds of an inch thick was interposed between the steel point and the cusp of the tooth.

TESTS WITH HARD STEEL DIRECTLY APPLIED.

(1.) Mesio-buccal cusp of an upper second molar; a fairly sharp cusp. A portion of the enamel of the buccal portion of the cusp split away at 125 pounds.

(2.) A rather obtuse lingual cusp of the same tooth. The enamel checked over a small area, and the tooth not otherwise broken with a stress of 350 pounds.

(3.) Disto-buccal cusp of an upper second molar, rather sharp. The enamel began to check at 135 pounds, and a part of the cusp split off at 165 pounds.

(4.) A well-rounded lingual cusp of an upper first bicuspid. A check in the enamel began to show at 100 pounds, but no further break occurred with 350 pounds. On removing the tooth, the enamel was found disintegrated over a small area where the steel was applied.

(5.) A sharp buccal cusp of an upper first bicuspid. A

check in the enamel began to show at 125 pounds and the buccal portion of the enamel split off at 150 pounds.

(6.) The disto-lingual cusp of a lower first molar. The mesial portion of the tooth had been destroyed by caries. A check in the enamel began at 115 pounds, and the cusp crushed at 150 pounds.

(7.) A sharp disto-buccal cusp of a lower second molar. A check began at 100 pounds, and a part of the enamel split off at 140 pounds.

(8.) A lingual cusp of an upper third molar. A check was seen at 100 pounds, and a part of the enamel chipped away at 140 pounds.

TESTS WITH VULCANIZED RUBBER, THREE THIRTY-SECONDS OF AN INCH THICK, BETWEEN THE STEEL AND THE CUSP OF THE TOOTH.

(9.) A fairly sharp buccal cusp of an upper first bicuspid. No injury at 350 pounds, but the rubber was cut nearly through.

(10.) A sharp mesio-buccal cusp of an upper second molar. No check appeared up to 325 pounds. At 335 pounds the rubber suddenly parted, letting the steel come onto the tooth, and the cusp was split off.

(11.) The cusp of a cuspid. No injury at 350 pounds.

(12.) Edge of a central incisor. No injury up to 240 pounds, at which point the rubber suddenly cut through, allowing the steel to be thrust against the tooth, which was crushed.

These few cases show the strength of the teeth as well as many additional examples would do. A hard substance, like tempered steel, bitten upon with full force, is liable to check the enamel or even split off a portion of a cusp, for the reason that, with the sharply rounding surface of the cusp the full pressure is concentrated on a very small area of the enamel. But, whenever this is distributed to a larger area of surface, as is done by a cusp sinking a little into the hard rubber, no harm is done by even a greater force than is ever used in chewing food. Indeed, the teeth have sufficient strength above that actually required, so that, when considerably weakened by caries, they are still strong enough to withstand the full force of the occlusion on any substance used as food. These may be injured, however, by the accident of catching a small pebble or any very hard substance that might, by accident, be mingled with food, or by biting upon the harder metals. Also the teeth are sometimes, though rarely, broken by catching unawares a lead shot or some such thing in such a way that it wedges between two cusps and splits



FIG. 166.

FIG. 166. The phagodynamometer, an instrument designed to measure the force required to crush foods that we eat. A, B. Upper and lower teeth carved of metal. With the lever E, E, these are forced together. The bar D, impinges on the heavy spring F, at G, and the compression of the spring F, moves the hands of the dial H, which registers the pounds force applied. With this the pressure required over the surfaces of two molar teeth in each jaw may be measured in pounds. It is, in fact, an ordinary spring scale in principle, but arranged for measuring the force of thrusts.

one off. A cusp that has been weakened by decay may occasionally be wedged off in a similar way by softer material, such as bread crusts, but it is rather rare that a perfect tooth is broken by any accident in the mastication of food.

Force Required in the Mastication of Food.

ILLUSTRATIONS: FIGURE 166.

The force required in the mastication of different characters of food is important in this connection. Our artificial modes of preparing foods have the tendency to render them softer and softer as so-called improvements are made. During recent years these have followed each other with great rapidity. In almost every line of foodstuffs, the so-called improvements have rendered them easier of mastication. I give here a table of the force required for the crushing of meats from trials in 1895 (*Dental Cosmos*). The instrument used is the phagodynamometer, Figure 166.

PHAGODYNAMOMETER RECORDS.

CRUSHING POINT OF MEATS.

Boiled corned beef, nice and tender	30 to 35	pounds.
Beefsteak, medium done, chuck	40 " 60	"
Beefsteak, well done, chuck	45 " 60	"
Beefsteak, rare done, very tender, loin	35 " 40	"
Beefsteak, round	40 " 50	"
Beefsteak, well done and rather tough	60 " 80	"
Mutton chops	30 " 40	"
Mutton steak	35 " 45	"
Roast veal, tender and nice	35 " 40	"
Roast loin of veal	30 " 35	"
Roast beef	45 " 60	"
Roast beef, loin	35 " 50	"
Pork chops, loin	20 " 25	"
Roast pork	30 " 35	"
Broiled ham, tender and nice	40 " 60	"
Cold boiled tongue, central part	3 " 5	"
Cold boiled tongue, near root	15 " 20	"

The following were selected by an experienced butcher as the toughest of meats. Only pure muscular tissue was used.

Cut from shank of an old animal:		
Fried, rare done	60 to 80	pounds.
Fried, well done	70 " 90	"
Cut from the neck	70 " 90	"

Rarely the needle reached 100 pounds before the crush occurred.

These were made from meats placed on sale within two hours after killing and generally used the same day. This was

the custom in most of the smaller cities up to the time when it was supplanted by the cold storage meats prepared by the great packing houses, which have now almost universally taken the place formerly occupied by the local butchers. These meats are crushed at from one-fourth to one-third less number of pounds than fresh meats, and they are sometimes even softer than this figure, when tried with the same instrument under otherwise the same conditions.

A similar change to softer foods is found in every direction. Gardeners are vying with each other in the selection and cultivation of the tenderest vegetables possible in the effort to satisfy the general demand of our people for tender foods.

Some of the confections are so hard as to be dangerous to the cusps of teeth that have become weakened by caries.

Crystals of rock candy crushed at	30 to	50	pounds.
Lemon tablets crushed at	50 "	70	"
Hard candy (stick), old, crushed at	90 "	120	"
Hard candy (stick), fresh, crushed at	45 "	60	"
Small cinnamon drops crushed at	30 "	60	"

Some gum drops which were mashed out of shape at twenty to thirty pounds offered great resistance when wedged in between the cusps. Indeed, it often would happen that these could not be completely crushed with less than 250 pounds. Small sticks of licorice offered similar resistance. These and similar articles prove dangerous to the cusps of teeth that are weakened by caries, or to bridges or artificial crowns. In the construction of these great care as to strength should be used. Bread crusts are equally dangerous. Indeed, within my personal observation, more teeth that seemed sufficiently strong have been broken with bread crusts — and not over-hard crusts either — than with any other one thing. I used sometimes to feel that persons relating these accidents were not quite honest in their statements, but when I tried the bread and found that it would wedge in between the cusps of the teeth and not be crushed out with a force of 350 pounds, I changed my mind.

Some persons have objected to my findings on a number of these points because only the direct up-and-down motions were used in tests; claiming that if the lateral or grinding motion were used the crushing would have been accomplished with much less force, and especially that if bread crusts are first wet with water or the saliva they would crush easily. All of this is perfectly correct. Rock candy or lemon drops will melt away in the mouth if the person does not bite upon them, and

bread crusts will become soft. But the trouble is, that people will bite upon them and bite very hard before they have become wet. Certainly persons may use the grinding motion on bread crusts, and these, being brittle, will crush easily, but the fact is people are not always careful to do this. Therefore, for the purpose intended, the manner of trial and the results given must stand as correct.

The dentist should give warning to such of his patients as have had their teeth weakened by caries, about biting on any of those things that are liable to become wedged between cusps and split them off. It is his business to know these dangers and to give the necessary instruction to bring his patients to understand the nature of these dangers to the teeth. He should also guard weakness of cusps closely in his manner of preparation of cavities and placing of fillings that they may stand the severest strain possible. All that we have learned of these points urge this course in the strongest terms. But those whose teeth are perfect need no warnings against the full use of any of the things used as foods. They should only avoid recklessness in biting upon the harder metals, pebbles and things of a similar nature, which occasionally are mingled with food by accident. The hazelnuts that formerly grew wild all over the Western States generally required from 150 to 200 pounds to crack them. The boys, many of the girls, and grown folks, too, used to crack them with their teeth as a regular habit. Many a laugh was had on seeing a boy with one of these hard nuts between his teeth, all of the muscles of his body in tension, both hands on the lower jaw helping; yet with all of this effort no perfect teeth were broken. The hazelnut modified by cultivation — the filbert that we get nowadays, is broken with less than half the force required by the wild hazelnuts. Any one whose teeth have not been weakened by caries should be able to crack filberts with perfect freedom. If the peridental membranes have not become weakened by failure of proper use, it should be a pleasure to chew the hardest of ordinary foods.

The cleaning power of vigorous mastication is greater and better than artificial cleaning. It does much for the health of the teeth and the membranes about them and contributes to the general health and vigor of the whole person. Therefore it seems to be the duty of the dentist to cultivate this in his community by careful advice to his patients as he meets them professionally whenever he observes that the teeth are insufficiently used.

Sensitiveness of the Peridental Membranes.

From what has been said of the force that may be used in mastication, it has been seen that, normally, the peridental membranes are very resistant and not sensitive to even very heavy pressure. But extreme sensitiveness of these membranes is frequent as a result of disease. This may occur quickly as a result of pericementitis, which often occurs after the death of the pulp of a tooth. Within a few hours this membrane, that could bear from 100 to 200 pounds without complaint, becomes so sensitive that the slightest touch upon the tooth causes intense suffering. In this condition any operation, such as cutting for the opening of a cavity, is prohibited by the intense pain produced, except in cases when the urgency of gaining immediate access to the pulp chamber of the tooth in order to clear the pulp canals for relief of the condition is imperatively demanded. Then the tooth should be supported in the best possible way and the cutting limited to the least that will effect that object. However, this particular subject belongs to another department and is mentioned here only as an illustration of the fact that this normally insensitive membrane may quickly take on a condition of extreme sensitiveness.

Forms of hypersensitiveness differing from the above occur in which there is, apparently, no pain from ordinary light pressure; yet any considerable pressure, and especially blows or strokes, upon the teeth, arouse much more pain than is normal to these membranes. This is due to various causes. The condition is habitually overlooked by the patients themselves unless it has been rapidly developed, which rarely happens. It is usually chronic from the first. In many of the cases there is very little that the eye would detect as wrong about the gums, the teeth, or the mucous membranes. But the teeth will not bear the normal amount of pressure without more or less considerable pain. In other cases there will be marked redness of the gingivæ, tumefaction of the interproximal gum septums and a tendency to bleeding from slight causes. This condition, however, is not a necessary accompaniment. When a patient is found with peridental membranes that are tender to pressure on the teeth, who complains of the force of blows used in filling teeth, or of other necessary force used in ordinary dental operations, strict inquiry should be made regarding the cause of this abnormality. Something has happened which has prevented the normal use

of the teeth, which is necessary to the health and strength of the peridental membranes.

Disease of the peridental membranes is now becoming a far more serious menace to the teeth than dental caries. Not by greater frequency of occurrence, but by its greater destructiveness when it does occur. This is to be guarded against as well as dental caries. In both, cleanliness is the principal factor. This is an additional reason for inquiry as to cause of tenderness of the peridental membranes. The cause will generally be found (1) in tenderness of carious cavities which has prevented proper use of the teeth for a time, (2) actual beginning of disease of the peridental membranes about the gingival margins, (3) tenderness in the apical space from diseased tooth pulps or following the death of the pulps of one or several teeth, (4) from the habit of bolting food without the proper and normal mastication, or the adoption of articles of diet not requiring force in mastication. Any one of these causes may be found by such examination as will exclude the others. Frequently the diagnosis is so difficult as to require that this plan of rigorous exclusion be followed. Causes 1, 2 and 3 may usually be found by physical examination, and in any case of difficulty this examination should be rigorously made. Cavities of decay sufficient to cause pain in chewing food, are generally sufficiently apparent or are well known to the patient. The same is true of teeth, the peridental membranes of which have become sensitive because of disease or death of the tooth's pulp. In disease of the peridental membranes, the patient is generally not conscious of any cause for the pain to pressure, for they have already ceased to use the teeth with vigor.

When the cause of the difficulty has been established, the treatment becomes simple, if the condition is causd by tenderness resulting from dental caries. Diseases of the peridental membranes beginning at the gingival margins will not be discussed. If the cause is found to be teeth that have become sensitive to the pressure of food in mastication due to caries, the first thing to be done is to remove this by temporary expedients and put the patient in condition to rebegin the vigorous mastication of food. No attempt should be made to make gold fillings for persons whose peridental membranes are abnormally sensitive, (1) because unnecessary pain will be inflicted, (2) because the operation can not be so well done. If there are exposed and inflamed pulps the first thing to do is to remove these pulps and place the patient in a comfortable condition by the use of

temporary fillings of gutta-percha. If the difficulty is from alveolar abscess in any of its forms, the treatment of these must be done and completed temporarily with gutta-percha fillings. These should be good enough for temporary use, made smooth and neat and of such form that the patient may use the teeth without difficulty. If decays are in proximal cavities, the greatest care must be had that there is ample space for the interproximal gum tissue to resume its normal form, and with such interproximal contact as will prevent food from leaking into this space. The whole treatment must be planned with the view of freeing the gums and peridental membranes from irritation, restoring them to the normal and giving the patient the full use of the teeth in the mastication of food. The excavation and formation of cavities should be ample for this purpose. When the tenderness is very considerable, extensions of cavities and the final finishing to form may be left until another time, or, in cases less acute, this may be practically completed.

When this has been done, the patient should at once go into training in chewing food. For this purpose many persons should make a more or less complete change in diet. Nowadays people often adopt a diet that does not require the use of the teeth; when such is the case, the diet should be changed to foods that will give exercise to the teeth. This should not be too severe at first, but the work should be increased as rapidly as practicable until full vigorous mastication has been established. With the continuance of this for a few weeks, the sensitiveness of the peridental membranes will have mostly disappeared. Most cases of extreme sensitiveness to the mallet should be watched to see that the patient is using all parts of the mouth. Any hindrances to this should be corrected and the treatment continued.

Patients who could exert only thirty pounds on the molars without extreme pain have often exerted 100 pounds within one month, and 150 pounds within three or four months. Any person who can give a gnathodynamometer record of 125 pounds will not suffer much inconvenience from such malleting as may be required for the building of any ordinary gold filling. The operator can then make fillings as he pleases and do himself and his patient full justice.

If in the diagnosis it is found that the patient has fallen into the habit of using a diet in which mastication is not needed, or has formed the habit of simply patting food into a bolus with

the teeth and bolting it, the necessary training will be the same, but the preparatory treatment will be unnecessary.

In preparatory work of this kind the utmost care should be had to see that food does not crowd into some interproximal spaces and cause pain or injury to the gum septums. Leaving opportunity for this will often defeat the whole scheme of treatment. The key to the whole matter is that the patient shall find that chewing food becomes a pleasure.

MANAGEMENT OF LIGHT AND CARE OF THE EYES.

The management of light is one of the essential things in operating. The light should always fall fairly on the field of operation and this should be the brighest light in the room. In localities in which the weather is generally fair, the office is best arranged if direct sunlight does not enter; but in some localities where there is much cloudy weather and many dark days, positions with the greatest amount of light will be preferable. Then on bright days the light can be modified by window shades. Very much may be done for the comfort of the eyes in the choice and arrangement of the wall decorations of the office and still preserve a tasteful color selection. The principal wall colors should never be bright. Neither should there be any form of glaze on the walls that will reflect light. The worst possible arrangement for a dental office would be a full white shining wall. All of the ground colors should be mild and subdued in tone. If bright colors are desired, they should be confined to a very small amount of surface in order that they may not affect in any marked degree the general tone of light in the room. Still, it is essential that the light in the operating-room be cheerful and that practically all parts of the room be reasonably well lighted. But it should not be brightly lighted.

The operating chair should generally be lighted by a single window. This should be low enough, when possible, to admit horizontal rays of light when needed, or as nearly that as practicable. A long window from which a high light may be obtained is also desirable but less important than the low and medium range of light. If more light should be desirable for the room, it is best that it be from a window in the same wall some distance away on the right side of the chair. The shade for this should be so arranged that this source of light can be conveniently closed. In certain positions at the chair such a light will be very undesirable. The operating window should be furnished with a shade, or two shades, by which light can be had from any part of the window at will, shutting off any part not wanted for the particular operation. The single window shade that may be run down from the top and close any part of the window below, obtaining the light entirely from above the shade, or by running it up and obtaining all the light from below, is generally suffi-

cient for a short or medium length of window. But for a long window, two shades that work independently of each other, are desirable. One of these may be lowered from the top, the other may be run up from below, enabling the operator to use any part of his source of light he may desire at any moment and place it on his work from high up or low down. Direct sunlight should always be shut out. The light from the clear sky is the most desirable light for dental operations. In all positions this should fall directly upon the work, without shadows. The arrangement should be such that a bright light will not fall in the operator's eyes while actually engaged in any operation. In positions, at the chair, right side in front, or left side in front, the operator's back should be to the light, while it falls full upon his work. In positions right side and left side behind, the arrangement of the chair should be such that, with the inclination of the head of the operator, the eyebrows will fully shade the eyes. There should be no windows in the rear or to the sides in any well-arranged dental office that will throw light into the eyes of the operator in any position that is necessarily assumed in operating.

In schools where many students must be accommodated such an arrangement is often impracticable, but even in these the student may generally manage to avoid having a bright light fall in his eyes by turning the operating chair into a favorable position. In offices unfavorably lighted for these purposes much may be done with suitably arranged window shades. A shade made to raise from below will exclude rays of light that come from too low a source, and confine the inlet higher up, or an upper shade may change this to a lower source, etc. In a room with several windows, certain ones may be closed by heavy shades at certain times in the day and the light modified to suit the time or position of the sun.

CARE OF THE EYES.

The care of the eyes should be a constant factor in the daily routine of office practice or school work in dentistry. There are few callings that are so taxing upon one's eyes. Many men have eyes just a shade off in focus so that long continued close application becomes tiresome. This will not occur readily if the adjustment is exactly what it should be. In any such case the exact nature of the error in vision should be found promptly and remedied by artificial means, i. e., properly adjusted glasses. This will not only conduce to comfort and accuracy of work, but

will prevent eye strain that might subsequently lead to disease of the eyes, and save much physical wear and tear. Such glasses should be adjusted especially for the operating chair and not used elsewhere. Others should be provided for reading and such work when that is necessary. The light should be sufficient, but should not be too bright. Too bright a light for the retina of the eye to bear with comfort causes a strain of the muscles contracting the pupil that becomes even more tiresome than the effort to see with too dim a light. One should carefully guard against both extremes. Either may easily become injurious to the eyes. If one's eyes are not good and can not be made good by artificial aids, he should not become a dentist. Many men learn too late that the care of the eyes is one of the most important considerations. Dentistry is especially trying on the eyes because of the exactness of vision required and because of the long fixation of vision at a certain fixed distance that is unnatural to the normal human eyes. The perfectly normal eye should be at ease from all muscular tension when viewing objects at some considerable distance, as when walking or riding through a woodland. To bring the eyes to see clearly at the very short distances at which the dentist operates, two sets of muscles that are coördinate in their movements are put in tension and are held in tension every moment of the time actual operations are progressing. The first of these controls the focusing of the lens of the eye for near objects; the second converges the two eyeballs so that both eyes see the near object. When the eye is normal and this position is held but momentarily, it is done with ease and is a perfectly normal use of the eyes. But to hold this near vision for many hours together is an abnormal use of the eyes. The human eye with all its wonderful versatility of use was never intended for this fixed use on near objects at distances of from ten to twelve inches. Such a use subjects the eye muscles to a continuous strain similar to that which one experiences when holding his arm full length in a horizontal position for a considerable time. Without the relief that comes from momentary relaxations in looking up from the work, changing instruments, etc., no person could maintain this close vision very long at one time. The reasons for this are precisely the same as the reasons for the inability to hold the arm extended in the fixed horizontal position for a long time without the relaxation of change of position.

The time of life is important in the consideration of this maintenance of near vision. In childhood the lenses of the eyes

are soft and their forms are controlled by slight muscular effort. As the person grows older the substance of the lens grows harder and a continuous increase of muscular effort is required for the control of the near focus. The boy or girl of twelve years may readily obtain perfect focus at six inches or even less. At twenty-five years ten inches distance is required. At thirty-five, fifteen inches and the maintenance of this requires more and more muscular effort. At this latter age the dentist begins to need help. This is a statement of something like averages for normal eyes. But within the range of normality considerable personal differences must be allowed. Some will need help almost from the beginning of dental practice, while others will be able to go longer without help. There are variations among persons that are so wide as to become abnormal, producing far-sightedness and near-sightedness, or hypermetropia and myopia. In hypermetropia of considerable degree one is unable, or soon becomes unable, to adjust the lens of the eye for near vision and requires the artificial lens for its correction when young in order to use near vision comfortably and effectively. In case of a very considerable degree of myopia, the person may need glasses in childhood to enable him to see clearly even at short distances. With a mild degree of short-sightedness one may need glasses for distant vision but may see well at short distances without them. The slighter grades of these difficulties usually pass unnoticed until some trouble with the eyes calls for an examination. Few persons are absolutely free from imperfections in the symmetry of the curvature of the cornea, known as astigmatism. This distorts the vision. It is capable of correction by suitably fitted glasses. This should be done wherever it is found to prevent eye strain and its attending consequences, even though the vision may be regarded as perfect.

The first aid necessary to the person with normal vision is usually in the focusing of the eye. This is done by placing an additional lens before the eye to do a portion of the focusing, relieving the muscles. Only partial relief can be given so long as the muscles focusing the lens retain their activity, for the reason that the muscles bringing the eyeballs in position for short vision are coördinate in their action with the muscles focusing the lens. One can not converge the eyes for short vision without setting the focusing muscles in action also. This adjustment of the artificial lens must be such as to balance the difficulties between these two sets of muscles. Therefore, for continued relief as the person grows older, a continued increase in the

power of the artificial lens is required to adjust the balance of muscular effort.

Some persons, on a false hypothesis, fight against the use of lenses as aids to near vision, believing that the habit contributes to early changes in the eye. This is incorrect. The eyes are relieved and made better. The correct statement is that the person finding relief will continually find the desire for it. He should have it.

For the near vision used by the dentist both sets of muscles may be relieved artificially to advantage. The movement of the eyeballs in converging from distant vision to near vision differs among persons, but may, as a general statement, be placed at ten degrees. If prisms are placed before the eyes that will do this instead of requiring the muscular apparatus to do it, and if combined with this there is a lens which gives the near focus of the eye without effort, the eyes may see at ten inches at ease and obtain a much larger retinal image than can be had with the unaided eye. As a statement of fact, this is literally true, but in its realization there are certain serious difficulties that must be understood and avoided. When the eyes are adjusted to distant vision, the person can not by any effort adjust his eyes so that he will have divergent vision or crossed vision. All of these movements are the coördinates of the one effort — to see — and can not be separated by the will. One may cross his vision by an effort to fix his eyes on an imaginary near point, but he will do it much easier by placing his finger before his eyes. But he has no power of will to fix his eyes in divergent vision. Therefore, if, by aid of the prism and lens, the eye is placed at ease for near vision, there is no power of will to change this into more distant vision. The only way in which the person may see at a greater distance is to remove these aids, or look over them. Therefore, if these aids are combined, the adjustment must be only partial, relieving in part but giving some opportunity for more distant vision. In this way the dentist may have relief for both sets of muscles for his purposes at the operating chair. The use of the prism before the normal eye must be confined to use in seeing small objects. The prism distorts all portions of objects outside of a small area of central vision and is therefore totally unfit for reading or other work in which any considerable form is prominent before the eye. While letters in the center of vision may be very clear, the book page will be very annoyingly distorted. In the mouth, where there are no straight lines, these distortions soon pass out of notice. These combined aids must

be confined to operating glasses or other work of similar smallness of area in which the outlying areas of distortion will not be annoying. Even this annoyance will disappear after long practice. In this I speak from a clinical experience of forty years' use of prisms in operating. In my seventies my vision is as good as in my thirties.

The use of prisms is not equally valuable to different persons. There is much difference in the pose of the eye muscles of persons who are capable of perfectly normal vision. This is best illustrated by comparison with a muscular pose that soon destroys normal binocular vision. When the pose of the muscles of the eyes is abnormal to a degree that renders it impossible for the person to continue the adjustment for binocular vision, squint occurs. This is called strabismus. This may be convergent or divergent, i. e., the eyes may be crossed or they may spread apart. The same thing to a lesser degree occurs in persons permanently capable of normal binocular vision; the pose of the muscles controlling the positions of the eyes may be a little abnormal one way or the other, but by a greater than normal effort they succeed in doing the work. The person with a slight tendency to divergent strabismus in the pose of the eyeballs at ease has much more effort to cross them for near vision than he who has the opposite pose tending to cross the eyes. It is the person who has the tendency to divergence of the eyes who derives the most important benefit from the use of the additional aid of wisely adjusted prisms.

It will now be apparent that all of this adjustment must be brought about by aid of the experienced oculist who has the necessary apparatus and is skilled in making the measurements upon which the adjustments of these aids to vision are based. There is no other profession or calling in which men do so much fine vision work with binocular vision as in operative dentistry. The watchmaker and the engraver give up binocular vision and use a single magnifying lens. The dentist does not. Therefore, the dentist, of all others, should have the greatest care as to his eyes and make the wisest use of the aids to accuracy of binocular vision. One of his special cares should be comfort of binocular vision and the continued usefulness of his eyes. The skilled oculist should be his helpmate.

EXAMINATIONS OF THE MOUTH.

A complete physical examination of the mouth and teeth is a matter of considerable difficulty. Every examination should begin with a cursory examination of the patient, in which the operator will learn the general physical condition in such degree as may be necessary. He should notice the patient particularly on first presentation, and it is best for the operator to see the patient on his or her feet at the first meeting, noting the carriage, the walk and step, and the manner of speech carefully, as these will often give indications as to the health and strength of the person. Such notice will also frequently be sufficient to determine whether the patient is in general good health or general poor health, facts that should be known. Further, it may also determine whether the patient is at the moment suffering pain, and give some indications as to the character of the ailment. In greeting a patient, one should generally inquire as to his or her health and whether it is as good to-day as usual. This will often bring out information that will direct further inquiry.

Of course, up to this point, the inquiry should appear simply as the manifestation of interest in the patient and the condition of the patient, as a friendly greeting, but to the dentist it should be really the beginning of an examination. When the patient is seated in the chair, a few well-directed words often will put him or her at ease and prepared for the examination. It is well, in the few words that are said at this time, to drop the hand upon the wrist of the patient, carefully noting the pulse; see whether or not it is normal, and note any variation from the normal. If the pulse is too frequent, it may be caused by a little temporary excitement upon first taking the chair. That is usually easily told by the demeanor of the patient. Otherwise too frequent a pulse may denote a condition of fever, and then the cause of the fever will, of course, be a subject of inquiry. A clinical thermometer should always be at hand to take the temperature. Sometimes a too frequent pulse may denote a lesion of the heart; if that is suspected, a very careful scrutiny of the pulse should be made, and, if necessary, an examination to determine whether or not the heart lesion is so serious as to require special consideration in dental operations. Sometimes the quality of the pulse becomes important. If it passes under the finger like a

hard shot or ball that is not readily compressible, or if it is stopped by the pressure of a second finger upon the artery above the one with which the examination is made, it would be described as a quick pulse, one in which the pulsation passes under the finger quickly and is gone, as distinguished from the frequent pulse. A quick pulse may be an infrequent pulse or a frequent pulse.

The opposite of the quick pulse is the slow pulse, where the pulsations may be of the usual frequency but are much longer in passing under the finger. The upward beat of the pulsation comes slowly and it dies away slowly, leaving but a limited space between the two, varying from the normal in the slowness of the pulsation in passing under the finger, as contrasted with the pulsation that passes under the finger quickly like a shot. Such a pulse may be frequent, normal or infrequent.

The quick pulse is apt to represent a condition of general tension or nervous excitability, while the slow pulse, other things being equal, represents a languid condition of the general system and may be induced by severe disease, but does not otherwise appear prominently in the person's appearance. Persons presenting either of these extremes in the quality of pulse are not in good condition to endure long-continued painful operations in the dental chair.

Being satisfied as to the general condition of the patient, the examination of the mouth should proceed. In doing this, it is usually best to so raise or lower the chair to bring the head of the patient to the proper height, with the chair thrown a little bit back, in a position between that which we would use for operations upon the lower and the upper teeth, in order that both the teeth of the upper jaw and the lower jaw may be seen without changing the position of the chair. Then it is best to take the position of right side behind, and passing the fore-finger of each hand into the mouth, one on either side, raise the lips and examine the buccal mucous membrane as far as can be done by the eye; or this may be examined first on one side and then on the other. One should look particularly for any points of swelling or of abnormal redness, and for the openings of abscesses upon the mucous membranes of both the upper and lower jaws. It is best to run the eye around the teeth, particularly noting, as far as practicable with the eye, the conditions present, and especially the condition as to cleanliness. This will give the operator a fair indication as to the care the patient is taking of his teeth.

A similar examination of the lingual mucous membranes

above and below, and also of these surfaces of the teeth, should be made with a mouth mirror. In doing this, it is well to include, or to make a separate movement for, the examination by the eye of the occlusal surfaces of the teeth. Finally the lips should be raised and the cheeks retracted, while the patient closes the teeth for the examination of the occlusion, whether it is normal or abnormal. From this point a close scrutiny should be made of any suspicious points on the mucous membranes that indicate the death of the pulp of a tooth, or trouble arising about the gingival margins of the gums or the necks of any of the teeth. In this first examination careful note should be made of any discolorations of the teeth, and whether these discolorations indicate the death of a pulp or are due simply to some deposits upon the teeth. Any suspicious places upon the gum tissue should be gone over with the finger, and the sense of touch noted. One who is careful to do this in the examination of patients will soon find that the sense of touch will indicate disease about the alveolar process and apices of the roots of teeth, which does not appear to the eye, or will give further information when disease is apparent to the eye. Often a blind abscess will exist at the root of a tooth and there will be no appearance to the eye to indicate it, whereas the sense of touch will indicate it very clearly after some practice. Again, the condition as seen on the gums may give evidence of some slight irritation, while the sense of touch will reveal an extensive absorption of the alveolar process.

The patient will probably have mentioned having come for a particular purpose that will direct an examination for some particular thing, but this should be put aside until this general examination has been made. However, if it should at any time appear that the patient has come in an emergency and is the patient of another practitioner, only such examination should be made as will properly direct the treatment immediately required. The patient should then be referred back to the dentist who cares for the case. Otherwise we suppose the care of the case is to be undertaken. If it is on account of dental caries that the patient has called, it will generally be best to examine for caries at this point, but in doing so it is just as well to have in view atrophy, erosion, or any other of the defects to which the hard tissues of the teeth are liable, such as white spots, pits in abnormal positions, etc. In examining for caries, the three explorers, a pair of rights and lefts and one with single curve, the mouth mirror, foil pliers, cotton or spunk, or both, the water syringe and warm water should be at hand. Any deposits upon the sur-

faces of the teeth should be removed and the teeth washed with a stream of tepid water. Then the surfaces of the teeth should be gone over in some definite order which will bring the instrument over each of the surfaces of each and every tooth in the mouth. Any cavities of considerable size will be obvious at once, but a closer examination than this should always be made — an examination that will reveal the beginnings of decay anywhere.

It is not important as to the particular order of this examination, so that a regular order is pursued. We may begin with the buccal surfaces and go over them, passing the instrument along the gingival border of each, and also passing the instrument into any pits that appear in the buccal surfaces, noting whether or not there is any softening, and whether the instrument catches or enters at any point. This should be done in both the upper and lower jaws, passing from side to side around the mouth. Generally it is best to take the upper jaw and then the lower, changing the position of the patient as may seem best. The recognition of the defects or disease of the hard tissues of the teeth must depend mostly on the knowledge one has obtained of these by lectures, reading and practical observation.

The examination of the occlusal surfaces should be done in the same way; each pit in each tooth should be examined in succession in both the upper and lower jaws and the conditions noted. Next, the lingual surfaces should be examined. Although decay is infrequent upon the lingual surfaces of the teeth, examinations reveal them sufficiently often to make this necessary, and particularly the grooves that may occur upon the lingual surfaces of the molars and pits upon the lingual surfaces of the incisors.

This leaves the proximal surfaces to be examined, and they are very much the most difficult. The discovery of incipient decay, or decay of the enamel before the enamel rods have fallen out, is difficult upon these surfaces, without the separation of the teeth so that the eye can assist in the examination. The instrumental examination should generally be made with a delicate pair of exploring tines, with rather short right and left curves, that may be slipped into the interproximal space from the gingival, with the point turned against the proximal surface toward the contact point for the detection of any roughness or break in the surface of the enamel. With a pair of these every part of the surface of the enamel may be explored very close about the contact between the two teeth. An important aid may be had in this examination by the passing of a ligature through the contact

point into the interproximal space and pulling it back and forth while holding it against the proximal surface of first one and then the other tooth. Usually the practiced hand will discover any roughness by the drag of the ligature. Often the sharp edges of a very slight break in the enamel will cut the ligature. It often happens that a slight decay will be discovered in this way that has been passed by the exploring tines. In cases where great precision is required, the teeth should be cleaned thoroughly and the rubber dam put on and then the teeth dried for this examination. In some cases it will be necessary to use the separator and separate the teeth at some one, or several, points in order to be satisfied as to the condition. At every point where the instrument catches or there is a roughness that gives a suspicion of decay, a special examination should be given that particular point. The teeth should be cleaned and dried, and the whitening, if any, noted, or any color that is off from the normal. In this way the amount of beginning caries of the enamel may be determined, but without this cleaning and drying it is almost impossible to be sure of the extent of the injury or whether the injury is caries or some other form or roughening of the surface.

Caries of the enamel that has whitened the surface always needs immediate attention, either in the way of filling or in cleaning. Cleaning by the patient, properly directed, may often be successful in stopping decay in the enamel of the buccal surfaces, but on proximal surfaces the patient can not, by anything he can do, prevent the progress of the decay that has once begun. The only recourse now known to us is the filling of such decays, and it is much the better plan to fill them very early, while the cavities may be shallow, not penetrating much into the dentin.

A dark color appearing in pits does not necessarily indicate decay. It may be simply some dark deposit, and very generally a dark deposit indicates a condition of immunity; yet it is the wisest plan to always try such pits with the explorer, for it occasionally happens that a dark spot is covering a decay that is making progress and should receive attention. As a general rule, pits should not be cut out nor filled unless there is some tangible indication of actual softening of the dentin beneath. If there is caries of the dentin, however, a filling should always be placed at the earliest practicable moment before great injury to the dentin has occurred, keeping in mind continually the principal object of keeping cavities as shallow as possible.

With this brief description of the process of examination for caries, one who has studied carefully the subject of caries, as

presented, should be able to make a proper and sufficient diagnosis after some observation and practice in making these examinations. One thing that is more frequently overlooked or passed without sufficient attention is the lodgment of food between proximal surfaces. Often patients go to the dentist time after time — so they relate — on account of pain in chewing food, located between some two of the teeth, and are assured that there is nothing wrong. The fact that there is pain from such cause is, in itself, evidence of something wrong that needs immediate correction.

When patients come suffering from pain, they usually know the seat of the trouble or cause of such pain, and can relieve the operator from any considerable trouble in making the examination. But it occasionally happens that the patient has no correct idea of either the location or the cause of the pain. When the pain occurs from the penetration of caries at some hidden point unknown to the patient, the pain from irritation of the pulp approached by the decay is often referred to some other point by the patient, and maybe to various points. It should be remembered distinctly that the sense of touch is the localizing sense and that the pulp of a tooth has not the sense of touch. Consequently it does not in itself localize painful impressions. If there has not been something, as the knowledge of a cavity, to indicate to the patient the location, it may be referred to the opposite jaw, upper or lower, or to any of the teeth on that side of the mouth, or to points in the neighborhood. In that case a search must be made for the cause of the pain. If the cause of pain is obscure, it is important to obtain from the patient as full a history of the beginning and progress of the pain as possible. This should first be related by the patient in his or her own way, without question or direction by the dentist, further than that required to bring out the complete story of the suffering, the points in which should be very carefully noted. After this story of the beginning and progress of the pain has been made as complete as the patient can do, the dentist may follow out any thought his knowledge of disease, or that the indications in this particular case, may suggest, and obtain further information by carefully directed questions. These should go as far into the history of the patient as the conditions brought out may seem to require, but when such pain seems to be from purely local causes, it is not necessary to seek far into the general history of the person. Generally pain referred continually to one side of the face, though apparently occurring at different points, will be found to be due

to exposure of the pulp of a tooth by decay in some secluded locality. The character of the pain will indicate, to one who has had some experience, something as to the nature of the cause. Pains that are due to inflammation of the peridental membrane, such as incipient alveolar abscess and the like, are usually accompanied by soreness of the teeth, which usually separates them quite sharply from inflammation or hyperemia of the pulp of the tooth; for the sense of touch for the tooth is in the peridental membrane. In this case the patient is able to locate the cause of pain definitely. In hyperemia of the pulp, the pain is fitful, coming and going, and is readily aroused by thermal changes. The patient, if he has been observant, finds that hot or cold drinks, or hot and cold foods, taken into the mouth arouse the pain, which passes away in a short time when these are removed. This character of pain is almost always from hyperemia of the pulp of a tooth, or it may be from inflammation and suppuration of the pulp of a tooth that has occurred from some exposure by a proximal cavity that is hidden between the teeth, or a cavity that has become covered by some fold of the gum about the gingival margins. This latter will usually be indicated by a redness of the gum at that point, which will appear to the eye, or a flabbiness that will be told by the touch when the finger is passed over it, either of which will lead to an instrumental examination revealing the facts.

In examinations of this character, it must be remembered that hyperemia of the pulp may occur in a tooth that is perfectly sound and normal in every other respect. It may have been aroused by ice water, by a blow, by catching something between the teeth, or in many ways that will be very difficult to find from anything that will appear in the examination or that the patient can tell, but the fact that warm or cold water will arouse pain in the particular tooth is usually sufficient to determine a condition of hyperemia of the pulp. In a few cases an inflammation of the peridental membrane of low degree has been found to show considerable thermal sensitiveness that serves to confuse one in this examination, but such a condition is rare and has usually occurred in teeth from which the pulp has recently been removed.

It is also well to remember that some forms of neuralgia occurring about the jaws simulate a condition arising from exposure, or hyperemia of the pulp, very closely, and it requires a very particular examination of the teeth to exclude diseases of the pulp in determining a condition of neuralgia. Often the pains in facial neuralgia shift from place to place, as much as the pains

from the pulp of a tooth shift, for both are apt to do this, but generally the neuralgia has not the thermal sensitiveness that occurs in hyperemia of the dental pulp. In neuralgia the pain is more likely to be excited by some movement of the jaws or touch upon the tissues of the face or gums. It is occasionally very difficult to arrive at a final judgment between these two causes of pain.

The diagnosis of erosion must be made by following the indications given in the presentation of that subject. The diagnosis of atrophy becomes so simple after one has seen a number of cases that it is readily made by following the indications given in the treatment of that subject. Pits appearing in abnormal positions in the enamel of the teeth should be very easy of determination as to their character after a few of these have been noted. They generally require no especial attention unless decay has actually started in them.

Although the treatment of pathological conditions of the dental pulp and of the peridental membranes are not included in the scope of this book, the recognition of these conditions is necessary in determining the course to be pursued in filling teeth, and for that reason their determination is necessary.

In all cases the condition of the gingival margins, or free margins of the gums, which overlap the gingival portion of the enamel, should have careful attention, because of the frequency of disease beginning at this position, which rapidly diminishes the strength of the peridental membranes. Any abnormal condition of these parts that may appear to the eye, or of sensitiveness, should lead to close scrutiny. In this it must not be forgotten that there may be an abnormal degree of sensitiveness of the peridental membranes that arises from lack of use of the teeth. This is generally common to all of the teeth. The conditions found vary considerably:

(1.) There may be a slight swelling of the festoons of the gingivæ between two or more teeth, while all other parts of the gum tissues are normal. In many cases this will be found to have been caused by leakage of food into the interproximal space in chewing food, and demands such examination as will reveal the cause and lead to its correction. Neglect of this condition even in cases in which the patient makes no complaint of pain from lodgments of food, often leads to serious conditions.

(2.) There may be a general redness of the gingivæ arising from some morbid systemic condition, usually of little moment, the correction of which generally requires little else than careful cleaning until the general condition causing it passes away. It

is very generally temporary. Such a condition occasionally follows the use of mercury, iodin and some other medicines that affect these parts prominently. In filling operations during the continuance of such a condition, the peridental membranes are apt to be more sensitive than normal to the mallet.

(3.) Hypertrophy of the gingivæ, in which occasionally much thickening occurs, covering much more of the gingival portion of the crowns of the teeth than normal.

(4.) Recession of gum about the necks of the teeth on the labial surfaces, often without other appearance of disease, but sometimes with a surrounding area of inflammation. This occurs most frequently on the cuspids, upper or lower.

(5.) Simple gingivitis of local origin.

(6.) Calcic inflammation of the gums and peridental membranes. This is a result of deposits of salivary calculus close against the free margins of the gums, or serumal calculus under the free margins. If such calculus is removed before considerable injury has been done and carefully kept from accumulating again, no considerable harm results. If neglected, the peridental membranes may be destroyed and the teeth lost.

(7.) Inflammation beginning at the gingival border of the peridental membrane, with pus forming and destroying the membrane in the form of pockets extending lengthwise the roots of the teeth. (Phagedenic pericementitis.) This form of disease, when once established, is so difficult to cure that the most careful examination should be made in cases in which there is reason to suspect disease of these membranes. In phagedenic pericementitis, pus is generally exuded from about the gingivæ by pressure of the finger over the part, but is sometimes not clearly observable. The peridental membrane and alveolar process is slowly destroyed, usually in the form of deep pockets, which may be found by exploration with a smooth-end flat blade, otherwise similar in form to the push scalers. These are generally confined to one side of the root of the tooth, as the proximal, lingual, labial, or buccal, until very considerable progress has been made, and there is a general tendency for the tooth to move away from the diseased side. Often when a pocket forms on the proximal side of the root, the teeth will separate a little; if on the lingual side of the upper incisors, the teeth will protrude, etc. When such movements of the teeth are observed, one should expect to find disease of this form. In the mind of the general profession these different forms of disease, beginning at the gingivæ, seem to be confused under the term "Pyorrhea Alveolaris." Any of

these conditions may be controlled if taken in time; if neglected, the last two named tend directly to the destruction of the peridental membranes and the loss of the teeth.

(8.) Lateral alveolar abscesses, occurring on the sides of the roots of teeth, the pulps of which are alive, usually occur in connection with phagedenic pericementitis. More rarely such an abscess may occur from accidental causes, and then will usually heal promptly when the pus is discharged.

TREATMENT OF DENTAL CARIES.

In what is said in this volume of the treatment of dental caries, attention will be directed to general principles of the plans that may be employed for its prevention, and for its eradication and cure, the management of cases and classes of cases in combating pathological conditions, and the discussion of prophylactic measures that may be used by patients themselves. The technical procedures in filling teeth are fully presented in the second volume. No discussion of methods of operating will be given here.

Prophylactic Treatment of Caries by Artificial Cleaning.

If the local conditions surrounding the beginnings of caries of the enamel and controlling its localization are as have been represented in preceding pages, and, if it also be true that without these, or equivalent conditions, the beginnings of caries would not occur, which all logical consideration of the conditions seem to declare, the first inquiry as to treatment should be directed to the question of the possibility of preventing the beginning of caries of the enamel in susceptible localities by systematized methods of periodical removal of all deposits. In the consideration of the beginnings of decay of the enamel, the natural processes of the cleaning of the teeth by the mastication of food have been pointed out in brief and its limitations cited in connection with Figures 101-103, inclusive. This shows that the points of failure of cleaning, in the chewing of food, are the points at which the beginnings of caries occur. Then, if these points could be cleaned artificially at sufficiently short intervals, dental caries ought to be prevented. The proposition that dental caries never begins on a clean surface of any tooth is old, and all modern research tends strongly to support and to strengthen it. It therefore seems certain that if such parts of every tooth as have been indicated could be kept clean, dental caries would be banished. From time to time, propositions looking to the cleaning of every part of every tooth at frequent stated intervals in order to prevent caries have been made. Most of these have also had in them some form of medication applied to the surfaces of the teeth accompanying the cleaning. Recently Dr. D. D. Smith has

revived this idea in its simpler form, relying wholly on artificial cleaning for results. This work consists in the cleaning and polishing of every part of every tooth with fine pumice, or some similar grit, finishing with a finer powder. The powders are used on orange-wood sticks, or similar material, cut in forms to reach any and all parts of the teeth. Very thin slips of wood and strips of tape are used for the proximal surfaces and to pass the contact points.

As a proposition, there can be no doubt of its effectiveness if it can be carried out regularly at sufficiently short intervals, but to clean in this way every part of every tooth is not necessary. The plan has in it only the mechanical effect of cleanliness, and in susceptible persons it would appear that the cleanings would necessarily be very frequent to effect the desired result. No sufficient experience has yet been had with this treatment that will determine its necessary frequency in any possible classification of cases. Neither has it been shown that patients will have the fortitude to present themselves for treatment at sufficiently regular intervals month after month and year after year to render this method of treatment effective. It will require years of experience to determine these points, and there is the suspicion that failure of the method will result from inability to maintain sufficient enthusiasm in patients to bring them for treatment at sufficiently short intervals and with the necessary regularity. The proposition is certainly correct; to carry out the treatment is the difficulty.

The method, so far as it is yet developed, has been purely empirical. It should be directed and simplified by a much closer study of the beginnings of caries of the enamel. This will render very much of the labor now being bestowed upon it, by those who are developing this treatment, unnecessary. While all parts of the teeth should, of course, be kept clean, much the greater part of the surfaces may be sufficiently cleaned by the patient by the brush and the proper use of the teeth in chewing food. Therefore, the dentist, while directing the whole of the work, may limit his manipulation almost entirely to the points of liability to beginnings of caries.

My own success in the treatment of buccal and labial surfaces by the brush and water in the hands of the patient, which has been mentioned, has been so uniformly successful in those cases in which it was done faithfully, that I have but little doubt of its success in other positions. The difficulty with this plan is in the sufficient control of any considerable number of people.

At present it seems unwise to discuss the subject at length. Its development belongs to the journals rather than to books.

It must be understood that treatment by filling should be supplemented and supported, in all cases of considerable susceptibility to caries of the teeth, by fairly vigorous and healthful chewing of food and by artificial cleaning with the brush in the hands of the patient. For this purpose, careful training of the individuals should be seriously undertaken by the dentist with the same care that he would bestow upon any operation he performs for their relief. This should be pursued to the minutest details of the motions of the brush necessary to do the best work in each particular case. Examinations should be made at intervals to see that regular and correct habits become fixed, so that important points will not be neglected by errors in handling the brush. This work will prove prophylactic in a high degree. It should entirely prevent the formation of the gingival third buccal and labial cavities. Even in cases of marked whitening of the enamel in several teeth, my experience shows plainly that the decay of the enamel can be effectively checked in any case in which the enamel has not been penetrated. The brush and water are all that are needed, but these must be correctly used to be effective. Thus far, prophylactic work done in this way will be successful. If coupled with careful watching for special periods of increased susceptibility, frequent examinations, or a special effort directed to treatment locally to prevent injury to the teeth, great good will be done.

Treatment of Dental Caries by Fillings.

ILLUSTRATION: FIGURE 167.

After decay has once begun in the dentin of a tooth, the only treatment that has thus far been found effective in preventing its progress or in curing the decay has been the complete removal of all of the carious area and the filling of the cavity with metal, or with some substance that is durable. Thus far, gold holds the first place for filling teeth, amalgam the second place, and recently porcelain and gold inlays are demanding important consideration. There are a few persons who would also give tin an important place. Besides these there are in use gutta-percha and the cements; these latter more especially for temporary fillings. In this treatment we would seem to be violating some of the general principles of physiology and pathology. Certainly we can not place any of these substances in the soft tissues with-

out causing more or less irritation; there will be a reaction against the presence of a foreign body, whether it be in the soft tissues or in bone. Any plug that we may place in a living bone will be loosened by absorption about it within a short time. If we drill into bone for the purpose of attaching apparatus for holding the ends of a fractured bone together and fasten gold, silver, iron, or what not, into the bone and apply force, we find that they will hold for only a short time; absorption will occur about them and they will be loosened. In the teeth it is different. No irritation is produced in the dentin by a process of this kind, except such an irritation as is produced by cutting the dentinal fibrils in the preparation of the cavity. This is manifested only in the production of pain. No absorption of the dentin occurs about the filling. There is no vascular system that is interfered with; there are no physiological changes occurring in the hard tissues of the tooth. The only changes of this kind occurring in the teeth are the changes in the sensations, which have been presented, and these changes in the sensory function do not involve changes in the hard tissues of the tooth. Do what we may, we fail to bring about any absorption of calcium salts or any deposit of calcium salts in the substance of the tooth. There is all of this difference in the physiological conditions in teeth as compared with the physiological conditions in bone. This enables us, by the insertion of fillings, to make an artificial repair of an injury by caries. If we had the same conditions as to the circulation, or the disposition to absorption or to inflammation that are manifested in bone through the system of Haversian canals, or the periosteum, it would be impossible for us to make repairs by filling; as a matter of fact, if such conditions existed, fillings would be unnecessary, as the tissue would have the power of self-repair. Absorption would occur and fillings would be loosened and thrown out, the same as such things are loosened and thrown out from the bone.

This much to emphasize the fact that we are working on a special class of tissue, the pathological conditions of which are different from those we find in other parts of the body. In other words, the enamel and dentin, when laid down are laid down once for all; they are not changed afterward by physiological processes.

For repair by filling to be successful, it must be very minutely done. It has been said that it is not necessary that a filling be water-tight to exclude microörganisms; and, since we have learned that microörganisms stand in a direct causative

relation to decay, some persons seem to have the thought that if we exclude microörganisms we necessarily prevent recurrence of decay. This is wrong. In conditions of susceptibility to dental caries, it is necessary that fillings be absolutely water-tight. A full conception of what that means is not very easy to obtain. A fairly clear conception of the size of microörganisms has been obtained in the bacteriological laboratory. Roughly speaking, a couple of thousand of them can be laid in a straight row across the head of a pin and not fall off, and yet they are large enough so that by the use of the microscope and microscopic methods we can see them, handle them, count them and measure their size. We can not see the molecules of water; they are so infinitely smaller than microörganisms that we gain no real conception of their size; we can not see them, count them nor measure them; we have no means of getting at the size of a molecule of water, or a molecule of acid, or a molecule of alcohol. They are infinitely small. Yet we must make our fillings so perfect that a molecule of water will not go in between the walls of the cavity and the filling material; that a molecule of acid will not go in; because, if microörganisms happen to lie on the margins of our fillings and form acid, the filling must prevent that acid from seeping in. It must not only simply prevent microörganisms from going in, but must also exclude the acid, for if the acid goes in it will soon make room, by the solution of the calcium salts, for the microörganisms. It will be seen from this again why we should lay our enamel margins in regions least susceptible to decay. But, do as we may, the margins of the filling are the vulnerable lines, and these we must devise means of making tight enough so that acid may not seep in between the filling and the margins of the cavity.

If the walls of a cavity are wet, we can not remove the last trace of water by any pressure we can bring to bear upon gold or amalgam placed against them. Capillary attraction is sufficient to resist all effort to remove the last trace of the film; afterward, there will be, in accordance with physical laws, an exchange of fluids in this space whenever a different fluid or solution comes in contact with its margin. An action occurs similar to dialysis, which has been explained in considering caries of dentin and of enamel. In this way a solution of any acid upon the surface of the tooth will be exchanged for the water in any such film.

The removal of water from the walls of cavities must be done (1) by absorbents; (2) by evaporation; (3) by absorbents followed by evaporation, and, finally (4) by freshly shaving or

FIG. 167.

FIG. 167. A photomicrograph of salts dialyzed from the saliva to separate them from the gummy material with which they are associated, and crystallized on a clean glass. When a cavity that has been wet with saliva has been dried by hot air, both these crystals and the gummy substances of the saliva are left on the walls of the cavity. They dissolve out after the filling has been made, causing a leak.

planing the surfaces. Absorbents, such as absorbent cotton, which has been prepared for this purpose, will readily remove the moisture almost completely, and the last trace may then be removed by evaporation. But the fluid wetting such a surface is seldom pure water. The water will carry something in solution and this something will be left as a film after evaporation of the water. If the cavity be wet with saliva instead of water, the saliva will be loaded with salts and mucus, and, when dried, will leave a film of these that will prevent contact of surfaces. Therefore, in order to obtain actual contact of surfaces, it is necessary, after all this has been done, to freshly trim the surfaces of cavity walls after they are dry and immediately proceed in placing the filling material. These are principles of physics that the dentist should understand well and appreciate their importance in filling teeth. The serious mistake of drying a cavity with the hot air syringe without other cleaning, when it has been wet with saliva, will be better appreciated by the examination of Figure 167, a photomicrograph of the salts dialyzed from the saliva to remove the crystallizable salts from the mucin and other gummy material. For this picture a very minute drop of the water into which the salts of the saliva were dialyzed, without the least concentration by evaporation, was placed upon an ordinary glass slide used for mounting microscopic objects, and allowed to dry. As soon as it had crystallized, the photomicrograph was made. Without the dialyzing, the gummy material in the saliva would add to the bulk of the film. Any one may see this residue by placing a drop of saliva on a clean glass and allowing it to dry. When this has crystallized on the wall of a cavity, it is white and can not be seen because it is of the same color as the tooth tissue. This gummy material and these crystals are freely soluble in the saliva, and when a filling is made against them they afterward dissolve out, making a slight leak, which is an imperfection. Therefore, after drying, these deposits must be cut away and then removed. This is only one of the points in the extreme care necessary in the treatment of dental caries by filling. Many others belong more properly to the technical procedures.

Curative Effect of Fillings.

The necessity of making fillings water-tight in order that they may be curative has been presented. Fillings cure purely and simply by shutting out everything from contact with dentin. They should be alcohol-tight, and alcohol will go in where water fails; acids will go in where plain, pure water fails to enter.

Fillings are not curative in the same sense that vaccination is curative against smallpox — preventive; such remedies remove the tendency to disease; something of a material nature is introduced into the blood and cellular elements of the whole body that tends to counteract the disease. Nothing of this kind is done in filling teeth. No systemic change is produced as a direct effect. That is to say, fillings do not remove the tendency to caries, and the curative effect of a filling is literally no broader than its outline. However, the filling has beyond this a prophylactic effect that is important, and how far this will extend will depend directly upon the skill displayed in laying the outlines of the cavity, shaping and finishing the filling. If the outlines are so laid that microbic plaques cover it and lap over its margins, it will not protect the area of liability; decay will begin again close beside the filling. The enamel margin is the vulnerable line. The filling itself, its own area, if it is made well and of material that is durable in the mouth, as gold or amalgam, is invulnerable; it should last a lifetime. But the enamel margins about it are not invulnerable. The shape given the surface of the filling has much to do with the protection of its enamel margins and the health of adjacent tissues. The enamel composing its margins is soluble in acids, and if these margins are laid in portions of the area of liability, decay is liable to recur immediately along the margins and the filling will be rapidly undermined. Then, in order that we may make this filling protective, we must study the area of liability in which it is placed, as has been indicated numbers of times, and in its preparation so lay the margins of the cavity that it will include the vulnerable portions of this area. Remember always that we do not cure in the sense of removing the liability, except as we replace the area of liability with an indestructible material. It is only in this sense that fillings are curative.

Fillings are prophylactic in a very much broader sense. A filling replaces a cavity which afforded opportunities for the collection of material for fermentation and formation of acid or other noxious products of decomposition. If the contact point is properly made in proximal fillings, the tendency to lodgment in the interproximal space is removed. This affords a protection to the immediate parts, to the neighboring gum tissue and to the adjacent parts. The filling becomes prophylactic in a very much wider sense than the local curative effect, because it not only protects the immediate surface liable to decay, but it protects the surrounding parts as well. It is also prophylactic in a still

broader sense, in that it gives the natural use of the tooth; a tooth that was sensitive, a tooth that the patient avoided chewing upon, is brought again into full use. That full use tends to the health of the part and the whole side of the mouth. Patients often, on account of one sensitive cavity, will avoid the use of that side of the mouth, chewing entirely upon the opposite side. Then disease is likely to run riot upon the disused side. In this way a single filling, by allowing full usage of the teeth, may serve to protect and guard the whole side of the mouth against future decay and against disease of the gums and peridental membranes. In this sense the prophylactic effect of the filling is wide and important. It is also important in a broader sense again than this, for, by giving the full use of the apparatus of mastication, it contributes to the general health of the person; the food is more perfectly masticated, is placed in a better condition for digestion, and the whole physical man is benefited by the operation.

What should be considered a permanent filling? What do we mean by permanent? This question might be answered in various ways. Possibly many dentists would regard a filling as permanent if it afforded a reasonable protection for eight or ten years, or four or five years. This would hardly be the highest idea of a permanent filling. There may be different degrees of permanence. Under some conditions I should regard a filling that protected the teeth for two or three years as doing good service under the circumstances, particularly in making fillings for children, where the conditions under which the operation is performed are very unfavorable. The child movement, to say nothing of the difficulties of self-control in the child, is such that operations are difficult. We sometimes find the equivalent of child movement in those who are no longer children, a condition of the nervous system in which there is continual movement of the person. This becomes so annoying that it is almost impossible to operate with accuracy. We speak of these as child movements because they are so common in children. They seem hardly to be voluntary movements; involuntary movements, as it were, but continuous or very frequent. Other conditions, such as general nervousness, sensitiveness that can not be well overcome, etc., contribute to the difficulties of making fillings, and make it necessary, upon occasion, that we make fillings that are not the best, because the conditions will not allow of the best operations. These should hardly be regarded as permanent fillings, and yet they do a service in protecting for the present, with the hope that

conditions will be so improved that later on better operations may be made. These are more properly fillings made for temporary purposes, but they are very valuable. A filling that will protect and prevent depth of cavities, even if it does not prevent the broadening of cavities, is valuable in protecting the deeper portions of the tooth and the pulp, and later, a second operation may be made which is broader and will protect the area of liability and be permanent. I should say a permanent filling should practically last a lifetime. A filling that is made broad enough to protect the area of liability, is properly seated and properly condensed, should stand. None of us will be able to operate with that perfection that will make every filling really a permanent filling, but a very large percentage of fillings should last a lifetime, or until the natural processes of wear have practically removed them, and usually, when that is the case, a refilling is not needed. A good many cases may be seen where proximal fillings have been made and the wear of the teeth has been excessive, in which practically the whole filling has been removed by the process of wear. Many of these have been made at a time when the patient was in a condition of extreme susceptibility to caries.

The conditions under which fillings are least likely to be permanent, even when well placed, are important for us to consider. More fillings will fail when made for children than when made for adults, even when just as well made. The conditions are such that they are not likely to be as well made. And in the observation of dentists in their practice and in the observation of their operations, it seems certain that they do not, as a rule, operate as well for children as they do for adults. It requires more force of the mallet to condense gold to a given density in the teeth of children, than in the teeth of adults. The force of a blow is measured, not so much by the momentum given the mallet, as by the resistance offered to the mallet. It is the old story told of the Irishman, who said, after he had received an injury from a fall: "Shure, sur, it was not the fall that hurt me, it was shtoppin' so quick." If he had fallen upon two or three feather beds piled on top of each other, or into a suspended netting, he would have escaped injury. And it is just so with the blow of the mallet; the number of pounds condensing power in the blow does not depend so much upon the momentum with which the mallet strikes, as the resistance offered. The peridental membranes of the teeth of children are very much thicker than the peridental membranes of the teeth of adults, so that they give

more, and it really requires from one-third to one-half more blow to produce the same result. It is demonstrable by actual tests with falling weights, that a little more spring in the resistance makes that difference; and it is a difference that should be very carefully studied in order to guard against the failures that occur in condensing fillings in the teeth of children. This less resistance, because of the greater spring in the peridental membranes of the teeth of children, is important. This is one of the difficulties met with in doing operations for children, in addition to the fact that they do not bear pain so well as adults. In older persons the conditions are better, the teeth are firmer in their sockets, a blow counts for more, and the percentage of success in making permanent fillings should be much greater. Take patients from sixteen to twenty years old as compared with those who are older, and the dentist who keeps his records as he should will find that the proportion of cavities filled for the first time will average much greater in the younger than in the older people. Many more refillings will appear in the records of the older persons. These represent failures. In a sense, however, such failures are not complete, for, in many of the cases, where carefully studied, it will be found that, while the cavities have become broader, increased depth has, in the main, been prevented. Also, some of the percentage of failure can properly be attributed to the greater difficulty of operating for the younger persons. In making fillings for the older persons, the conditions should be better, the patients will be under better self-control, and fillings that will be really permanent should be very generally made. But this requires the development of a high order of skill in the planning of the work for the protection of cavity margins and exactness in its execution.

There will be some patients who are older, in whose teeth small cavities have begun, perhaps, in their teens, decayed very slowly, stopped for a time, until conditions of susceptibility having come again, they have decayed a little more, stopped for a time and then decayed a little more; cavities that patients have not noticed until the occlusal surface has broken through and made an opening that the tongue discovers, or in which food lodges. In such cases as these, no man should fail. The patients are older, they bear operations better, the tendency to the recurrence of decay is almost nil, all the conditions are more favorable for making operations that are permanent. In fact, in many such cases, any fillings that will stay appear to protect the teeth. A man does not deserve especial credit for succeeding in these

cases, and yet it is important that he do his work well, because there may be a return of susceptibility that will try even these fillings severely. When persons have come to the adult age and the expression of immunity is apparent in the mouth, any tyro can make fillings that will be apparently successful. That which tries the skill of the dentist is the making of fillings which will stand the test of time for the very susceptible child, with a hereditary condition continuing this susceptibility on to maturity.

Selection of Filling Material.

In the management of cases, the selection of filling material should have careful consideration, and this is especially true in the management of families of children. The plan of management should always include this selection, and it should be determined early in the consideration of each individual case.

Gold should always hold the first place and be regarded as the material for use, unless displaced, for some specific reasons. Gold holds this place because of its intrinsic merits as a filling material for the cure of caries, aside from any consideration of its expense or of the popular consideration of its purity, indestructibility, or that glamour that comes from its universal use as money and consequent high consideration of its value. These points that make so much for the use of gold in the public mind, should have little consideration by the dentist intrinsically, and yet these popular fads can not be ignored entirely in our dealings with the people. They have their place in the minds of those with whom we deal and must be considered as fixed facts that can not easily be brushed aside. For these reasons, the dentist will often be induced to use gold in positions of extreme difficulty for both himself and his patient, when his own better judgment would lead him to use another material. Again, esthetic considerations will call for the use of gold in restorations in positions where the filling can not be hidden, and will call for long and tedious malleting upon a sensitive peridental membrane that will be in danger of permanent injury. In a general practice it will often occur that such circumstances limit the power of choice. This difficulty, that has been felt to be very real and trying in the past, is being much relieved by the use of the porcelain inlay in difficult cases that come in prominent view, and the gold inlay in large cavities in the molars.

The general rule should be that gold should be used for young people and for children, for the reason that with it the placement can be more accurate than with any other material,

and, therefore, with it the power of limiting decay during the period of the more extreme susceptibility is greater than with any other material. This should not, however, lead the zealous practitioner to undertake the use of gold under circumstances that will prevent perfect operating. It should be remembered always that gold is intrinsically better in limiting or curing caries only because it can be more accurately placed. If the circumstances are such as to defeat this accuracy of placement, another material should be used temporarily, in case gold has been determined upon, until better conditions may be attained.

In the care of families of children, it will happen that considerations of economy will require that a cheaper material be used. When this is the case, the facts should receive careful consideration and a course of action determined. In this the greatest care should be exercised, and even then it will be impossible to avoid serious error. Many times it has happened that amalgam was chosen for the molars and bicuspids of families of children, and when they have grown to adults they have been greatly chagrined because such a choice had been made for them. Changes in financial conditions of families, and in the mental attitude of persons toward such matters, will inevitably bring some very awkward conditions and relations not appreciated by the laity.

Under no circumstances can other than gold be used for fillings in the six front teeth, except inlays as indicated elsewhere, and cement fillings as a temporary expedient under some peculiar conditions. This is to be regarded as a law that can not be transgressed because of esthetic considerations, except under conditions under which porcelain inlays may be chosen. But in the molars and bicuspids, esthetic considerations become less prominent in proportion as fillings will be hidden from view. In these, amalgam may be used instead of gold, when required by the necessity of economy. Formerly, I had been much opposed to the use of this material in the teeth of children of very susceptible families for the reason that its power of limiting decay was so very much below that of gold, but lately, since we have had more experience with amalgams that neither shrink nor expand, it is found that the curative power of this material, when carefully and intelligently used, stands well up toward that of gold. This gives it a much wider range of usefulness in the teeth of susceptible young people than formerly.

Then if, through the necessities of economy, amalgam is chosen, it should be limited to certain portions of the mouth, and

used exclusively in those portions from the beginning. This may be the molar teeth or the molars and bicuspids. A question that I have found myself asking many times in this connection has been: "Will amalgam fillings in the mesial surfaces of the bicuspids in this mouth show a dark color that can be noticed in ordinary social intercourse?" The answer to this question should have decided weight in the choice of material for these teeth, and in young girls, particularly those with thin lips, light complexion and active facial muscles that will, upon occasion, show these teeth prominently, esthetic considerations should debar amalgam. It will not do to say, "This is only a little girl and the appearance is not important." In a very few years the girl of twelve or fourteen is the young lady of eighteen, with all of the pride of personal appearance belonging to that age, and esthetic considerations in case of the younger girl should have the young lady in society in view, and the choice of filling material should be made accordingly. On the other hand, if the lips are thicker, the facial muscles less active, the teeth better covered and the complexion darker, there will be less objection to the use of amalgam in the bicuspids.

These matters should be considered and determined for each person, and afterward there should be no commingling haphazard of amalgam and gold fillings in the back teeth. It should be all one or the other in the limits determined upon.

In older people, these considerations become less important, but are never obliterated. As a rule, they are stronger in women than in men, but they never disappear at any age, or in either sex.

The use of gold fillings becomes limited in many cases by reason of disease of the peridental membrane. Often a very little appearance of disease limits materially the endurance of the peridental membrane under the stress of mallet pressure to such an extent as to properly prohibit the building of large gold fillings. Further, when a very large filling is to be built in a molar tooth and the membranes are not particularly strong, the long-continued malleting necessary to the proper condensation of the gold is likely to do permanent injury. In all such cases, amalgam or inlays become the more appropriate material. These conditions usually occur at a more advanced age, when the intensity of the tendency to caries has become so much modified that the danger of recurrence of decay is much less.

In the front teeth, amalgam is debarred. In case the membrane has become so weakened that gold can not be used, it is

better to use inlays or tide the case along with cement fillings, renewed, as may be necessary, from time to time, awaiting better conditions.

In broken teeth, or teeth so badly decayed as to necessarily show much gold in fillings, the question of the use of porcelain inlays should be considered. For the present, I think it should be considered that the power of arresting decay is low in porcelain inlays set with cement, and there should be more caution as to their use in the teeth of young persons who show much tendency to caries. But when decided immunity to the beginning of decay has become apparent, this plan of repair may serve an excellent purpose in the restoration of lost parts. It is particularly well adapted to the hiding of such defects in the teeth of singers and others who are much before the public and in whom such blemishes become especially prominent.

Inlays are also very desirable in cases of weakening of the peridental membranes in cases of recession of the gums or other cases of injury to the peridental membranes of any of the teeth. In these cases the patients are generally older and the tendency to decay so limited that the power of protection from further decay has become less important.

The limitation temporarily of the use of gold in young patients, or in sensitive teeth, awaiting better conditions, will be sufficiently presented elsewhere.

In case of prominent loss of substance of teeth by wear (mechanical abrasion), the material used for repair or the building up of the lost part, should be the hardest that we can use for the purpose. Generally the platinum-gold foil shade No. 3 should be chosen. This has all the merits of a pure gold filling, but, if well condensed, stands severe abrasion much better than gold alone. There is apt to be some objection to this material in the minds of some patients on account of its color being not that rich yellow of pure gold. Because of this difference in color, they are apt to think it an inferior material. This is because the public is less acquainted with the value of platinum, and is, in fact, a prejudice. Or, better stated, the public is not sufficiently acquainted with it for its character and qualities to declare themselves at sight and it leads to questioning. It is richer than pure gold, more durable under abrasion, its color makes it less noticeable, and altogether it is intrinsically a better material than gold for all fillings that show in the front teeth because of its less prominent color. As this material can be worked conjointly with pure gold, it may be used simply as a veneer on those parts of

the filling that will be seen from the front. When used in cases of abrasion, those portions of the filling within the cavity proper may be made of pure gold, and all of the body of the filling that will become exposed to wear, or to view, made of platinum gold.

MANAGEMENT OF CAVITIES BY CLASSES.

Under this heading it is the intention to discuss the relation that the treatment of caries should bear to the local conditions of its causation, the intensity of susceptibility of the individual and the changes in susceptibility and immunity which may occur as patients become older. This will include the time in the life of the individual of the occurrence of the different classes of cavities and some notes on recurrence of decay at unusual times.

Classification.

Class 1. Cavities beginning in pits and fissures in any parts of the teeth in which these occur.

Class 2. Cavities beginning in the proximal surfaces of the bicuspids and molars.

Class 3. Cavities beginning in the proximal surfaces of the incisors and cuspids which do not require the removal and restoration of the incisal angle.

Class 4. Cavities beginning in the proximal surfaces of the incisors which require the removal and restoration of the incisal angle.

Class 5. Cavities beginning in the gingival third — not pit or fissure cavities — of the labial, buccal or lingual surfaces of the teeth.

This classification is especially intended for use in technical procedures. But, as it is also a classification of cavities which expresses the order in which they most frequently occur in the age of the individual, it will be of use here in bringing the questions at issue in more orderly form.

Caries of the teeth presents considerable differences when occurring in different localities in the mouth or upon different surfaces of the teeth, and at different ages of patients that call for differences in the management of cases. Occasionally all classes of cavities will be found in the same mouth and require treatment at the same time. This is comparatively rare, but when it occurs in a young person the case is a very grave one. The rule is that in very susceptible persons, particular classes of cavities make their beginnings at about a certain time after each of the several teeth has taken its place in the arch. This certain time will be early or late with different patients, accord-

ing to the intensity of the susceptibility and favorable or unfavorable local conditions. If the first molar is found with occlusal decay at eight years, two years after it takes its place, the second molar is apt to be decayed in the occlusal surface at fourteen, or two years after it presents in the arch. The same rule follows in pit cavities in other teeth. If, however, the first molar is not decayed until twelve, other pit cavities will also be late occurring, and not so many will occur. Pit cavities do not occur if there are no pits, but they do not necessarily occur if there are pits. The number and the time of their occurrence will be controlled mostly by the susceptibility to caries in the individual.

Cavities of the other classes occur at a later date as the rule. Therefore, when cases are closely followed with respect to individual teeth, we have to deal with one class first, then another and then a third, as our patient grows older. In following the history of one hundred persons, we find beginning decays in the first molars in five distinct localities which, in a considerable majority, appear in the following order as to time: (1) In the pits of the occlusal surface; (2) pits of the buccal surface (less frequent); (3) in the mesial surface; (4) in the distal surface; (5) in the gingival third of the buccal surface.

Cases occur frequently, however, in persons twenty-five to thirty years old or more, in which caries progresses so slowly that when the patient presents for treatment the several classes of cavities may be present at the same time. These must be sharply distinguished from cases in which the different classes of cavities begin very nearly together in persons of fifteen to eighteen years old. In the first, the intensity of susceptibility has been sufficient to start many areas of decay, but the early tendency toward immunity has checked the progress, and the case is readily manageable, while in the treatment of the second we have to deal with the full intensity of the susceptibility. Special conditions, which are due to early childhood. will be presented under the heading, "Management of Children's Teeth."

Cavities of the First Class.

Cavities of the first class, in the large majority of persons met with in practice, are first to appear. These include pit and fissure cavities in the molars, bicuspids, upper lateral incisors, and more rarely in the upper central incisors also. In a large proportion of persons, the first of these are in the molar teeth, and in many persons these are the only cavities of this class, the incisors being free from pits and fissures, and decay not occur-

ring in the pits of the bicuspids. Under equal conditions of susceptibility and local conditions among the different teeth, decay in pits and fissures would occur within about a certain time after the teeth take their places in the arch. In highly susceptible persons this will be within from one to three years, and at a later time as the susceptibility is less. Therefore, while this class is first to appear in the individual teeth, the cavities are scattered over a considerable period in the person, and, as both the susceptibility and local conditions vary greatly in different persons, we meet with this class of cavities at various ages of persons. It is only through the careful observation of records of many persons that general rules are made out.

The local conditions relate almost entirely to the form and depth of pits and fissures. Well-closed pits rarely decay. In very susceptible persons decay begins early in deep pits and in fissures. In immune persons, decay may not occur at all in these.

Pit cavities in the second molars begin to occur at from fourteen to sixteen, and often make rapid progress in highly susceptible persons. If it is remembered that these cavities usually appear in very susceptible families in from one to three years after the eruption of the teeth, and the order and time of their eruption is kept in mind, the whole matter will be materially simplified and the reasons for the order of their appearance will be readily grasped. One will therefore look especially after these teeth at the proper time. The pit cavities are the simplest of all cavities to treat, and, when taken in time, rarely present any considerable difficulty. It should be remembered, however, that in occlusal surfaces, the whole surface of the fillings is fully exposed to thermal changes by hot and cold drinks and foods. They are, therefore, in more danger from thermal sensitiveness in proportion to their area than other cavities. In proximal cavities, much of the area of the fillings is shielded by the proximating tooth. In buccal cavities the fillings are not so directly exposed to thermal changes, therefore where dealing with very deep cavities especial care should be had to shield the pulp from thermal changes. This is best done by covering the pulpal wall with a layer of oxyphosphate of zinc and making the filling over this, after it has become fully hard. Theoretically, gutta-percha is the best non-conductor, but, practically, it is too soft to serve as the support of a permanent filling and should never be used.

Filling over softened dentin. There is a practice among many in the profession of leaving a portion of softened dentin in deep occlusal cavities and filling over it, claiming that when

securely covered in, especially if saturated with an antiseptic, no more decay will occur. This procedure is very tempting in handling deep occlusal cavities. So far as continuance of the decay is concerned, the statement is correct, but this carious mass contains a poisonous substance elaborated during the carious process, which, when shut up in this way, especially endangers the vitality of the pulp. This is the principal reason why we find so many dead pulps under such fillings. It is always safer to remove the decay completely and, when it is very deep, use oxyphosphate of zinc. I am persuaded that much of the bad reputation of oxyphosphate of zinc as a pulp-capping and as a protection against thermal sensitiveness in deep cavities is due to its use over a more or less thick mass of carious dentin, and especially over pulps already infected and inflamed from undiscovered exposure to carious dentin. Pulps thus exposed must be regarded as inflamed pulps and not proper subjects for capping. Only those pulps that become exposed in the removal of the very last particles of softened material, or in cutting beyond, are suitable subjects for capping. The principal use for oxyphosphate of zinc is for the protection of pulps nearly, but not actually exposed. In deep cavities, the actual condition is not discovered until the last of the softened dentin is removed. Not infrequently a tooth is filled when the pulp is fully exposed to the softened material; death of the pulp follows speedily. Under all conditions every particle of softened material should be removed, and if the pulp be exposed in so doing, deal intelligently with the conditions found. This is the only safe line of treatment in any cavities whatsoever.

Pit cavities in the occlusal surfaces of the bicuspids are much less frequent than in the molars, and when there has been reasonable watchfulness, they may be filled when small. They are therefore easy of management. They begin to occur at from fourteen to sixteen. These, especially, should be filled early, for, if neglected, the burrowing of decay is pretty certain to undermine the marginal ridge and a portion of the enamel of the proximal surface. By this extension the simple pit cavity is converted into the more complicate occluso-proximal cavity, which greatly increases the difficulty of treatment. For this reason one should be especially watchful of the pits in bicuspids in the children of very susceptible families and fill them upon the first appearance of softening. This watchfulness is especially necessary in these teeth for the reason that the pits are generally small and the beginnings of decay very much hidden until

considerable burrowing has occurred. Careful examination of the proximal surfaces of these teeth for decay should always be made before filling these pits to see whether or not they may need treatment. The proximal surfaces decay much more frequently than the pits, and in the treatment of these, the pit fillings previously made must always be removed in cutting occlusal anchorages.

When examining for pit and fissure cavities in children of families highly susceptible to caries, the least showing of the beginning of caries should not be allowed to pass without immediate treatment. These decays are too often allowed to burrow deeply before treatment is instituted. The dentist should never lose sight of the fact that in young persons the pulps of the teeth are much larger and their horns are much longer than in the teeth of mature persons. For this reason the pulp becomes endangered by a decay of much less depth. Sometimes they will even reach the pulp of the tooth before making any noticeable showing upon the surface. The carious material is white, the surface of the enamel is complete except the pit or fissure. It may show through the enamel as a grayish area, or the decay may not be detected except by the fine-pointed explorer. All such decays occurring in susceptible children demand immediate attention.

After writing the above statement, a dentist of high repute told me of a case in which, in examining the teeth of a girl about eighteen years old, he was trying the pits as usual with the exploring tine, when, to his surprise, the whole enamel cap of a bicuspid came away with the instrument. He found the whole of the dentin of the crown a softened mass. The appearance of the tooth had given no suspicion of the actual condition.

This condition must be differentiated sharply from the conditions so often found in older persons, in which these pits and fissures are much darkened or actually black. This dark color occurs where some slight softening of the enamel has taken place earlier, and is often mistaken for active decay. It is rather an evidence of immunity from the beginning of new areas of decay. But there may be an active area of decay beneath this dark coloring, and this must be determined by the explorer. While the dark color is evidence of conditions unfavorable to decay, decay having begun may be continuing. This demands examination, and the operator will be controlled by the conditions found. Very many pits show evidence of some slight softening in early youth, which is stopped by the coming of immunity or some

change of local conditions. Then these become dark in color and so remain without further change. These should not be interfered with, as they are just as safe without any filling whatever.

Cavities of the Second, Third and Fourth Classes.

These include all cavities in the proximal surfaces of the teeth. Although properly divided into three classes from the standpoint of differences in technical procedures, the second including the proximal cavities in the bicuspids and molars, the third including the ordinary cavities in the incisors and cuspids, and the fourth those in which an angle of the tooth is involved, the conditions from the standpoint of the management of cases may in part be presented together. The fourth class includes only cavities of the third, in which extension of decay has involved the angle of an incisor and calls only for differences in the technical procedures. It may therefore be eliminated from present consideration. Decays of the proximal surfaces are the most destructive decays that occur in the teeth and occupy more of the dentist's time than any other. They also call for a greater degree of acuteness and skill in the management of conditions than any other.

In the order of occurrence, these cavities follow or occur later than those in pits and fissures, but are usually earlier than those occurring in buccal and labial surfaces. It must be understood, however, that this expresses the general rule found by making averages from many recorded cases and to which there are many exceptions. Between the time and the frequency of the appearance of proximal cavities in the incisors and in the bicuspids and molars, there is the utmost variation in different individuals. In some, the incisors will escape entirely or with but one or two cavities, while the back teeth will have many; and in others, the case will be reversed. In the aggregate, the liability is about equal, though where individual proximal surfaces are considered, the mesial surfaces of the central incisors are found decayed oftener than any others. The broad, flat mesial surfaces of the first molars stand next in the frequency of decay. In any of the teeth, except the first bicuspid, the mesial surfaces are oftener decayed than the distal surfaces, apparently because they are less rounded in contour. In considering these, it must be remembered that there are two areas of liability — one mesial and one distal on each tooth — while in the first and fifth classes there is but one, except as buccal pits in some of the molars furnish a second. Therefore, if the liability were

equal, the proximal cavities would be double the number of either the first or fifth classes.

These are all smooth surface cavities — that is, they occur in surfaces on which the enamel of the tooth is perfect and smooth, presenting neither fissures, pits nor grooves, which serve as starting points for decay. The conditions are therefore radically different from those presented in pit and fissure cavities. The beginning of decay in these smooth surfaces is not confined to a single minute point in the enamel, as when beginning in pits and fissures, but the surface of the enamel is attacked and the area will be great or small, coinciding with the size of the local areas of uncleanness. The close examination of a large number of cases shows that the size and form of these areas depend mainly upon the forms of the proximal surfaces, and the amount and form of those parts which closely approach each other. When the surfaces are well rounded, the contact points small and the embrasures wide and deep, decay is less apt to occur and its beginning is confined to a narrower area of surface, or often to a small point; while, if the proximal surfaces are flat, the contacts broad and the embrasures shallow, decay is more liable to occur and the area of enamel surface attacked will be proportionately broad. Other things being equal, this matter of forms of the surfaces, their contact points and the depth of the embrasures control the degree of cleanliness of these surfaces and their liability to decay. This will be better understood by reviewing Figures 86 to 95 inclusive, illustrating these forms, together with the text relating to them. All of this will be modified by the degree of susceptibility to decay and by personal artificial cleaning. The susceptibility of the person will constantly be the principal factor, modified and controlled to some extent by the conditions above detailed. At the present time, we are unable in any direct way to control this principal factor — susceptibility. In prophylactic treatment our attention must be directed to the removal, modification or improvement of those local conditions giving opportunity for its manifestations.

The key to the rules of management of these classes of cases is found by noting these local conditions, and in the study of the influences they exert for limiting, increasing or modifying the opportunities for the beginning and superficial spreading of caries of the enamel.

The forms of the areas of liability to decay are different in the molars and bicuspids from the forms presented in the incisors and cuspids, because of the differences in the contour of proximal

surfaces of these teeth, but the essential characters of the areas are the same in all, so that they are really much alike. The conditions which give opportunity for these decays are to the gingival of the contact point.

The proximal area of liability to decay is bounded to the occlusal. or incisal, by the proximal contact point, to the buccal, or labial, and lingual by the opening of the embrasures to the excursions of food during mastication, and to the gingival by the position of the margin of the healthy gum septum.

In a strict account of the examination of ten thousand persons who applied for treatment in the clinic in Northwestern University Dental School, only nine persons were found in whose teeth superficial spreading of decay of the enamel had passed across the angles of the teeth from one surface to another, or had extended from two surfaces and met across the angles. All of these were cases of unusual severity of caries that had been neglected until all effort to chew food had been practically abandoned by the patients. This marks the angles of the teeth, or an approach to them, as the line of safety along which to lay cavity margins in the preparation of cavities in proximal or buccal surfaces. It also points out that the angle of the tooth should not be passed in the extension of cavities unless some special condition presents, such as the extension of caries in dentin, requiring it.

The best management of these cavities requires that the operator make a study of each individual proximal surface involved, determine the boundaries of its area of liability to decay, and that in the preparation of the cavity, the whole of the area of liability be included within the cavity outline, together with such area of the occlusal surface in bicuspids and molars as may be necessary to give convenience in operating and stability to the filling. If present decay only be removed, the cavity lines not being extended as described, decay will recur about the margins of the filling, causing failure. The provisions for maintaining the health of the gum septum should not be overlooked. Caries never makes a beginning on a portion of the tooth surface covered by a healthy gum septum or free gum margin. All such portions are strictly immune. A margin of a filling so laid that it will be continuously protected by healthy gum tissue is as safe as if laid upon a surface fully exposed to the friction of mastication. Therefore, the preservation of the health of the septum of gum which normally fills the interproximal space to the contact point is one of the important factors in

treatment. It follows, that in the preparation of these cavities, they must, in order to be curative and prophylactic, be cut so far into the embrasures, both to the buccal and to the lingual, that the excursions of food in the act of mastication will sweep their marginal lines and keep them constantly cleaned, and the gingival margin must be so laid that it will be covered by the gum septum. Then, if the form of the proximal surface, and especially of the contact point, is so made that it will protect this gum septum, and is sufficiently prominent to preserve the full mesiodistal breadth of the tooth, the permanence of the filling made with technical skill is assured. The cutting of cavities to these lines is termed, extension for prevention. It applies to all proximal cavities.

In this connection, a very common misconception occurs with the observation that, in many cases met with in practice, spreading of decay on the surface of the enamel has gone no farther than the margin of the open cavity; therefore it is not necessary to extend farther. This is often a serious error. If, in the progress of caries of the enamel, the enamel rods fall away in the central portion before decay has spread to the buccal or lingual as far as opportunity would allow, the colony of microörganisms will usually become detached and not grow again on the surface while the cavity remains open. This seems to be because of the changed conditions caused by the loss of the central nidus of attachment. When a filling has been made and properly formed, this central nidus of attachment is restored and growth again occurs on the filling. The filling material being indestructible, this growth spreads to the full extent of opportunity to the buccal and to the lingual and will overstep the boundaries of the filling, causing recurrence of decay. Therefore, if safe fillings are to be made, the laying of the boundaries of every cavity prepared should be determined by a study of the area of opportunity for the beginning of caries rather than by the breadth of the present decay. The boundary of opportunity of spreading decay toward the buccal or lingual will be determined by the depth of the embrasures and consequent breadth of near approach of surfaces, which make the opportunity for cleaning by the sweep of food through them in mastication, or by the brush in artificial cleaning.

The study of recurring caries in its earlier stages, as it is presented in practice, is one of the best methods of informing oneself of the conditions causing it. For this to be most valuable, those cases in which the enamel has become whitened but in

which no enamel rods have yet fallen out, serve the best purpose; for in these the whole condition remains unchanged. After actual cavities have been formed, it is often difficult to be certain whether the case is one of extension of decay on the enamel, or a case of leakage from poor adaptation of the filling material, or the faulty preparation of an enamel margin. If these early beginnings of recurrence of caries are noted carefully with a study of the nearness of the approach of the surface of the proximating tooth to them, the opportunity for cleaning of the cavity margin by excursions of food, the shapes of the occluding surfaces as controlling food pressure through them, the actual conditions of cleanliness of the part, together with the habits of the patient in artificial cleaning, much will be learned of the conditions of recurrence of decay that will give valuable information for guidance in the management of this class of cases. These are conditions which, I am persuaded, very few dentists have learned to study in a really practical way that will make the information gained available in practice. While these studies, coupled with a proper and available development of technical skill, ought to place the dentist in such rapport with his cases that few recurrences of decay will be found in after years, it is too much to expect that these will be actually banished. This occurred to me some time ago. In 1875 I undertook the care of the teeth of a young man, then nineteen years old, who had many proximal cavities, and gingival third cavities in the central and lateral incisors, with some whitened areas on the gingival thirds of the buccal surfaces of the bicuspids. Altogether it seemed an ugly case. After a study of it, he was placed under pretty close instructions for prophylactic use of the brush and made comfortable by the removal of two exposed pulps, so that he could make full use of his teeth again and recover from sensitiveness of the peridental membranes so as to endure the mallet well. The fillings were made without hurry, occupying about six months' time. The extensions were full and free as I could now recommend. Within the next four years several other decays were found beginning, after which there was complete immunity. In 1903 he came to me for advice. No fillings had been lost. In several cases recent recurrence had formed cavities at the buccogingival angles of fillings. Whitened areas of beginning decay were demonstrable in a similar relation to every proximal filling and every gingival third filling that had been made. Many new decays were starting in areas not decayed before. Films of very firm gelatinous material (plaques) were present upon all of the

fillings on buccal surfaces or other positions of easy access for examination. These had spread beyond the margins of the fillings. The enamel was decaying under these extensions. Indeed, the whole denture was going to pieces with so-called "chalky decay." The man seemed to be in ordinary health, but he had had a reverse in fortune a few years before, which had left him despondent and he had become entirely careless in his habits of cleanliness. His teeth, gums and peridental membranes had become sensitive (there was no calculus) and he had almost ceased to chew food. The only chance for this man lay in a complete change to cleanly habits, with radical training in the mastication of food. Otherwise fillings would be of little value. No amount of extension for prevention would have been available for the prevention of extension of decay in such a case and the effort to meet such conditions in that way should never be made. Cases of lesser gravity will occasionally occur in practice which can not be covered with any reasonable extensions of cavity walls. A judicious operator will make no effort to provide for such cases in his general plans of management of his cases. He should, however, so manage in his treatment of proximal and gingival third cavities that such recurrent decay will not be found so long as persons are making reasonably vigorous use of their teeth in chewing food. During the past year I was consulted by a person who had unusually broad whitened areas on all of the buccal and labial gingival thirds of his teeth, and much of the same conditions showing in the proximal surfaces. From the history of his case, it appeared that he had recently had typhoid fever, during which his mouth and lips were much gummed over with gelatinous material (sordes). Except for this, he had been immune to decay. To all appearances, he was again immune. No enamel rods had fallen out; no penetration of enamel had yet occurred; the teeth were disfigured by the change in color, but the probability is that further decay will not occur. The whitened areas will probably become dark very slowly if the strict cleanliness and the habit of vigorous use of the teeth, as rebegun after his recovery, is maintained. Such beginnings of decay following typhoid fever, in which there has been much sordes, are not very uncommon, but such a case as above related is very rare. It serves well to point out the usefulness of vigorous mastication of food, and reasonable and intelligent use of the brush as matters of treatment.

These processes, taken as a whole, are carried out for their curative and prophylactic value. Many persons seem to think

that, in the matter of extensions of cavities, simpler fillings, in the technical sense, may be made, and have been made successfully in these cavities in the past. While this may be true of some, too many have failed. Experience in cutting and filling cavities, according to the rules given in technical procedures in filling teeth, will, by comparison of results, show such supposed simpler cavities to be lacking in prophylactic value. Decay is continually recurring about the margins of the fillings whenever they are involved in habitual uncleanliness of even moderate degree, and they are soon undermined and destroyed. For this, extension for prevention, intelligently adapted to the conditions and skillfully carried out, has been found an effective remedy.

LIMITATION OF EXTENSION FOR PREVENTION.

In the use of extension for prevention, there is no call for extension around the angles of the teeth onto either buccal, labial or lingual surfaces. Objection has been made in some journal articles and society discussions, that cavities had to be cut inordinately large in order to comply with the requirements, especially in the front teeth. This is from a misunderstanding of what is meant. In the front teeth, there should be no cutting over onto the labial surface, nor should there be any considerable show of gold fillings for the purpose of satisfying the rules of extension for prevention. Decay seldom begins on the angles of any of the teeth, and especially is this rare in the angles of the incisors and cuspids. When cavities in these teeth are so cut that the margins approach the angles sufficiently to free them well from near contact with the proximating teeth, extension for prevention is satisfied. An approach to the angle on that part of the surface rounding up to it is what is called for. Any cutting beyond the angle is in direct opposition to extension for prevention, because it is then approaching an area of surface that is less safe. In the preparation of a cavity in an incisor it should never be cut over onto the labial surface for the purpose of extension for prevention. It is only when decay has extended along the dento-enamel junction so as to undermine and practically destroy a portion of the enamel of the labial surface that it should be cut away. In these teeth, the necessities for extension for prevention relate almost exclusively to broadening the cavity to the labio-gingival and linguo-gingival angles of the proximal surface, or squaring out the ordinary rounded form of the gingival wall and making the labial and lingual walls straight from near the incisal angle to the labio-gingival

and linguo-gingival angles. This is distinctly pointed out and illustrated in the volume devoted to technical procedures in filling teeth. The same rules apply to bicuspids and molars, with this difference: Incisor cavities must be filled from the labial or lingual, because they are not cut out to the incisal. Proximal cavities in bicuspids and molars are cut out to the occlusal and are filled from the occlusal direction. For convenience in operating, and in order that the filling can with certainty be well made, it is necessary that the cavity be as broad bucco-lingually at the occlusal as at the gingival portion. Therefore, any extension made at the gingival portion toward the buccal or lingual must be carried out to the occlusal. This makes cavities somewhat larger in these surfaces. But in no case is it necessary in satisfying the demands of extension for prevention, to extend fully to the angle of the tooth, much less beyond the angle. Extension for prevention has no relation whatever to the depth of cavities. Every cavity prepared for filling should be as shallow as the removal of all carious material will allow wherever this will give safe anchorage in dentin. This should be taken as the expression of a principle in all treatment of caries by filling. Large fillings extending far out onto buccal or labial surfaces should be made only when demanded by actual extension of decay.

In highly susceptible persons, proximal cavities are very destructive to the teeth and destroy them quickly. In such cases, they are more liable to attack the teeth in the order of their eruption, and are often discovered within two to four years after the teeth have taken their places in the arch. These are the most difficult of cavities to treat successfully. We have the child to deal with, the teeth become abnormally sensitive, every movement in the treatment is painful, the self-control and endurance of the patient are low, and, yet, this is just the case in which prophylactic cleaning and the technical procedures in treatment need to be carried out with the greatest degree of minuteness to be successful.

For a number of years the fillings must resist the sharpest susceptibility to recurrence of decay. The operator may know well his duty and be skillful in manipulation, and yet, if he has not the moral courage back of his convictions, great patience and persistence, he will do well to transfer the little patient to some one better qualified in these particulars. Even with the most intense susceptibility some of the proximal surfaces usually escape decay, the local conditions as to form and cleanliness

being especially favorable. Often the proximal surfaces of the front teeth will decay very early, and those of the back teeth not until later, or not at all. In other cases, the front teeth escape and the proximal surfaces of the bicuspids and molars decay very early. In either case the decays are very apt to occur in pairs, similarly located one upon either side of the mouth.

A mesial cavity occurs occasionally in the first permanent molar while it is in contact with the second deciduous molar and it requires treatment very early. This is presented fully under the heading "Management of Children's Teeth," and need not be considered further here.

This is the only proximal cavity in the molars that begins at a very tender age. The second molar is not erupted until twelve, and rarely has a cavity before fourteen or fifteen in the most susceptible children. And it is only at this age that distal cavities in first molars begin to occur. At this age, however, we may expect cavities in the distal surfaces of the first molars and mesial surfaces of the second, and cavities are liable to occur in the proximal surfaces of the bicuspids almost as rapidly as they take their places. When this occurs, the teeth melt away with great rapidity and the most heroic and painstaking operating in respect to minute details and the full inclusion of areas of liability will be required to protect them until the coming of immunity relieves them of danger. All tinkering with temporary fillings should be avoided to the utmost, and yet cases will occur in which temporary fillings must be resorted to, to bridge over periods of extreme sensitiveness. But the time of their use should be confined to the shortest possible limit. At this age, the failure of effective use of the teeth in chewing food quickly brings with it sensitiveness and thickening of the peridental membranes, and it is of the utmost importance to have the patient using the teeth vigorously again in order that fillings may be made without inflicting unbearable pain, and also on account of the necessity for the greatest possible cleanliness. Often temporary fillings made with this special end in view, together with the arousing of the proper effort on the part of the patient, will accomplish the desired end quickly, or within a month or two, and then the case may be regarded as under control and the necessary fillings leisurely and effectively made. Many dentists push their young patients too strongly. That is, they make their sittings too frequent and too long. When the patient is suffering pain, extreme sensitiveness, or failing in

mastication, it is better to make the sittings short and frequent until comfort is restored and conditions obtained which permit of effective mastication. Then put the patient to vigorous work with the teeth, if possible, upon extra tough or hard foods, giving them vigorous exercise three times per day. When this has been continued for a few weeks, the sensitiveness will be so diminished that effective operating may be done without great pain. Sufficient time should be given between sittings — a week or more — to allow the hyperesthesia aroused by the one operation to pass away before beginning the next. In this way the operations may be continued to a finish with a continuous improvement of conditions. Definite plans of management with these ends in view are of the utmost importance in extreme cases of hyperesthesia with notable impairment of mastication. Cases that come to us before there is considerable impairment of masticating power are more easily dealt with, and permanent fillings may generally be made at once.

Hyperesthesia of the dentin does not limit the use of the teeth except when food is forced into the cavity in such a way as to affect the dentin directly. Cases of extreme hyperesthesia of the dentin will be met with in many cavities in persons who have no impairment of mastication. Therefore, in these cases, a solid filling, one that does not move or shift, cures the difficulty in mastication as soon as the patient gains confidence that the use of the tooth will not hurt. This, of course, relates to cases in which the sensitiveness has occurred so recently that there has been no impairment of the tone of the peridental membranes, a thing which often occurs when the occlusal wall of a proximal cavity has suddenly broken away, exposing the cavity to direct food pressure. There is, in such cases, no reason for deferring the final filling because of pain in malleting, for that will be borne without difficulty. The difficulty is only in the preparation of the cavity. But the question of thermal sensitiveness and the danger of hyperemia of the pulp will require consideration. In a large proportion of the cases of hypersensitive dentin there will be no especial thermal sensitiveness. This question generally relates to individual teeth and does not materially affect the treatment of other cavities. These may be proceeded with to completion without delay, or, in the meantime, the sensitive teeth with temporary stoppings will have so improved that the extension of the cavity may be completed and these also may be permanently filled.

Older patients, of twenty to thirty-five years, often present

with a number of slowly progressive proximal cavities in the bicuspids and molars, or cavities in which fillings have failed. If these cases are not so bad as to have materially limited mastication, or if the patient has not contracted mincing habits at table, they are generally easy to manage. They require little else than the careful performance of the required technical procedures after a study of the requirements of extension for prevention in the individual cavities.

If, however, the case presents many open cavities that have long rendered chewing painful and ineffective, and the habit of avoiding foods requiring effort in mastication has been long confirmed, they may prove exceedingly difficult to treat. The whole mouth is often in a condition of hyperesthesia; everything we do for them hurts. In operating we must treat them as we would treat children, but otherwise as adults. Often we must gain their confidence by selecting the least painful operations in the beginning, and then, as rapidly as possible, remove the hindrances to mastication and train them into the vigorous use of their teeth. It is often well to use temporary fillings in those cases requiring long, tedious packing of gold until chewing has become effective and the membranes strong and firm. Then the necessary malleting to make a good filling can be borne without difficulty.

If, in any such cases, there are pulp exposures that are preventing the patient from chewing food, these must be eliminated by the appropriate treatment as a first procedure whenever practicable. Operators most often overlook bad contacts or open cavities, which allow food to so impinge upon the gums as to continually cause pain. Whenever such places are present, they should be treated with temporary fillings in such a way as to substantially remove the difficulty without waiting for the more tedious permanent operations. The recovery of the health of the gums, and particularly of the gum septums, and recovery of the peridental membranes from sensitiveness caused by irritation and lack of use, should always be especially looked to in the making of temporary fillings. and these must be so made as to promote this. Often gutta-percha is forced upon the gum septum in such a way as to cause its absorption and do permanent injury. This should, by all means, be guarded against with jealous care; for, when it occurs. the interproximal space will be continuously unclean, except as it is cleaned artificially. This becomes a continuous menace to the health of the parts. When this has occurred, every effort should be made by artificial

cleaning and the mild stimulation of the interproximal gum tissue to induce a regrowth that will fill the space. This will often be successful, but often it will fail.

Thermal sensitiveness is met with more frequently in the management of cavities in the upper incisors than any other teeth, apparently for the reason that they are most exposed to cold air. Precautions against this should be taken wherever possible. The conditions make the use of oxyphosphate of zinc or other non-conducting material under these fillings more difficult than in other teeth. The cavities, even when deep for the locality, are still so broad compared with their depth, and the requirements for anchorage are so imperative, that there seems to be no room for the oxyphosphate of zinc. In most cases, when it is demanded, the operator may contrive to overcome the technical difficulties, or he may substitute a bit of quill, which is just as effective as a non-conductor, and does not occupy appreciable space. Careful instruction to patients regarding the danger of thermal sensitiveness and the means at their command of avoiding it, is, after all, the most effective protection. Instruction in the use of the quill as a non-conductor will be found in technical procedures in filling teeth.

In bicuspids and molars, the form of the occlusal surface, in its relation to the interproximal space and the embrasures, is occasionally of great importance to the cleanliness of the parts. In the normal occlusion, the arrangement of the teeth is such that the cusps of an upper molar or bicuspid are in position to force the food into and through the embrasures, buccal and lingual, of the lower teeth. The cusps of the lower teeth are in position to perform the same service for the upper; that is, a portion of the occlusal surface of the teeth of the one jaw overhangs the embrasures of the other, and, in every act of chewing, the food is forced to sweep through these embrasures.

This forms the natural method of cleaning them, as has been related in the text in relation to Figures 101, 102, 103. Irregularities of the teeth often prevent this form of cleaning being effectively done. Also the forms of teeth may be such in particular instances that it is not well done. In many cases where a more effective cleaning of an interproximal space by the process of mastication seems desirable, the form of the part of the occlusal surface formed by the filling may be so modified that, in the crushing of food. a greater amount of it will be directed into the embrasure and effect a more thorough cleaning of the marginal lines of a filling. This may usually be done by

cutting away some portion of the marginal ridge and so sloping the surface toward the embrasure that, when the food is crushed upon it, it will tend to slide into and through the embrasure.

A change in the form of the proximal surface may often be made that will improve the cleaning of the parts, especially in broad proximal cavities in the molars and bicuspids. The distal surface of the first molar, particularly when the disto-lingual cusp is large and protrudes to the distal so that the lingual embrasure is much narrowed, will not have its disto-lingual angle well cleaned by the excursions of food, and on this account decay is especially liable to occur along the gingival portion of the lingual margin after the filling is made, if the original form is preserved or reproduced. In this case it is much better to carry the cutting somewhat beyond the disto-lingual angle of the tooth, and, in finishing the filling, reduce the distal protrusion of this cusp and widen the embrasure. If, at the same time, the distal marginal ridge is left low, or the occlusal surface sloped a little toward the embrasure, so as to direct the crush of food into it, the cleaning of the lingual margin of the filling will be so improved as to prevent this tendency to recurrence of decay at this point.

In the bicuspids there are great differences among different individuals in the mesio-distal breadth of the lingual cusps as compared with the buccal. When the lingual cusps are broad in this direction, the lingual embrasures are very narrow, so that the cleaning of the lingual marginal lines of fillings will be very imperfect; these embrasures should be broadened by narrowing the lingual cusps wherever practicable, or by separating the teeth sufficiently to build out a prominent contact point, and the occlusal surface so finished as to direct the excursions of food into and through these embrasures so that they will be continually cleaned by the act of mastication. In making these form changes, every care must be had to slightly increase the mesio-distal breadth of the tooth at the contact point. The observant operator will find many places other than those cited in which to apply the principles which the particular cases given illustrate. Whenever cases of great intensity of susceptibility to decay demand treatment, every means at our command of increasing or facilitating the natural cleaning of the marginal lines of our fillings should be studied for the individual case.

LODGMENTS OF FOOD IN THE INTERPROXIMAL SPACE.

The effect of lodgments of food in the interproximal space has been pointed out in connection with the two groups of illus-

trations, Figures 121-123 and 124-128, inclusive. Good management of cases requires especial watchfulness for such conditions. No case in which lodgment is suspected, or in which complaint is made by a patient, should be allowed to pass without the closest scrutiny and a determination of the facts. Often there will be no complaint by the patient on which to base a special examination, and sometimes the symptoms remain very obscure until much injury has been done. This insidiousness of the conditions is one of its greatest dangers. In many of the cases, however, in the absence of complaint by the patient, the symptoms are plainly marked. The most prominent symptoms are the swelling and redness of the interproximal gum tissue, and an enlargement of its festoons on the buccal or lingual, or both, in some one or more of the interproximal spaces, without apparent reason to be seen in the general conditions of the mouth. This may be so prominent that it will catch the eye of a skilled observer at once, or it may be so slight as to easily escape notice. In many of the cases in which increased redness is not apparent, the gum tissue will have become festooned, i. e., the tissue, instead of rounding smoothly into the interproximal space as is normal in healthy mouths, becomes enlarged and pointed in the embrasure. This may occur as a general condition of the gums in cases of a slight gingivitus from uncleanness, or occasionally. from constitutional causes. The condition passes away readily when the causes which induced it have been removed. This general condition must not be confused with the local condition occurring at isolated points. When patients complain of pain from forcing food into any interproximal space, a careful examination will generally show that the central portion bucco-lingually of the gum septum has been absorbed by the pressure of the retained food, forming a pocket of more or less depth. When the patient has not complained but still the symptoms noted above are found, careful examination will, usually, reveal similar conditions. This will confirm the diagnosis in either case. Then it becomes necessary to determine the cause of the condition and to remedy it. In many cases it will be found to be caused by the roughening of the proximal surfaces by beginning decay and the remedy is in making the appropriate filling, or fillings, in proper form. This should not be delayed because the decay is as yet very slight. Figures 121-123 show conclusively that wide extensions of decay toward the gingival occur from this cause, making a grave complication of the case even before the enamel rods have fallen away in the original

beginning point of decay of the enamel. This is sufficient evidence that delays for any considerable time are dangerous.

In other cases the difficulty may be caused by a cavity that has become larger and possibly partially open to the occlusal surface. In any such, the duty of the operator is too clear to be questioned. The same is true if the cause be found in contacts much flattened by wear, as in Figures 124-128, inclusive. A few cases in which none of these conditions are present may give trouble in the determination of the cause, but generally a close investigation will determine it.

When decay has extended far to the gingival from this cause and is still confined to the enamel, as shown in Figures 121-123, it will not appear in the excavation of the cavity, if firmness of the tissue of the gingival wall to cutting instruments is relied upon as a guide. Often the existence of a pocket between the teeth will lead one to suspect it. The examination must finally be made by the eye in a good light, the cavity being dry. If there is an extension of decay to the gingival because of lodgments of debris, it will appear as a light, chalky line on the cavo-surface angle of the gingival wall. Then, of course, the cutting must be continued until this is removed.

Finally, good management of cases demands that fillings in proximal surfaces be so formed that lodgments of food in the interproximal spaces shall not occur. Otherwise, all of the evils related above will occur after the filling is made and it will be lost by recurring decay at the gingival margin of the filling. This is fully discussed from the technical standpoint in the second volume.

PROPHYLACTIC VALUE OF FORM IN PROXIMAL FILLINGS.

The form given to proximal surface fillings is of the utmost importance in the prevention of recurrence of decay, and in the prevention of the occurrence of disease of the gums and peridental membranes. The points to be attained are: (1) The preservation of the full mesio-distal breadth of the tooth crown; (2) correct form of proximal surface; (3) correct form of interproximal contact; (4) the health of the gum septum. The general rule will be that the original form of the teeth should be reproduced in the filling, but it often happens that the original form is not the best form, and in such cases, when practicable the form should be improved. The most essential features are that the contact point be well rounded so that it will touch the proximating tooth only at a small rounded point, and that this be sufficiently prominent to restore the original tooth form

and therefore restore the full normal breadth of the interproximal space. This requires that the teeth be separated sufficiently to allow the finish to be made without in any degree narrowing the mesio-distal breadth. Indeed, it is better to widen this just a little. Careful measurements show that when the average person has arrived at the age of forty years, he has lost, by wear of the proximal contacts of his teeth, one centimeter in length of the arch measured around the labial and buccal surfaces of the teeth from the mesial cusp of the right third molar to the mesial cusp of the left third molar. Some of this loss should be restored with every proximal surface that it is necessary to fill. When the forms of the teeth have been good, their restoration reinstates the normal conditions, and cleanliness and health are readily maintained.

If, on the other hand, the mesio-distal breadth is not restored, the two teeth will soon be crowded together, narrowing the interproximal space, and the crowding upon the gum septum will cause its partial absorption. It will be shortened and will fail to fill the narrowed interproximal space, affording opportunity for lodgments in a position difficult to clean. The embrasures are also narrowed by reason of the teeth falling together, which prevents the excursions of food through them in mastication, and increases the area of liability, or carries its borders farther toward the angles of the teeth, so as to place the margins of the filling in greater danger of recurrence of decay.

When the proximal contact is not sufficiently prominent to restore the mesio-distal breadth of the tooth, it is necessarily flattened and broadened, and is in that degree less well adapted to maintain the cleanliness of the space. If it is flattened to any considerable degree, it will not only fail to be self-cleaning, but will grasp and hold stringy particles of food. These will be forced upon the gum septum, causing pain in mastication, which will be a grave annoyance. Absorption of the gum septum will occur, forming a pocket that will hold debris, which will decompose and cause recurrence of decay at the gingival margin of the filling, or it will cause disease of the peridental membrane, with final loss of the tooth. It will also endanger the neighboring teeth. The failure to obtain correct forms of interproximal surfaces caused widespread loss of fillings from recurrence of decay at the gingival border, when dentists first began making contour fillings with cohesive gold.

In practice, cases are frequently presented of teeth that have been neglected, in which the contact points have been lost

from caries, and the teeth have crowded together, closing up the normal interproximal space until the necks of the teeth have come close together. If these are filled ever so well, without separation and moving the teeth apart sufficiently to restore their original form and the original breadth of the interproximal space, the proximal contact will necessarily be flat and will continue to hold debris, which will be forced upon the gum and the difficulty will not be improved. The remedy is in the restoration of a normal form by restoring the breadth of the interproximal space and mesio-distal breadth of the teeth with the normal form of the contact point.

Cases will be presented frequently in which numbers of teeth have been filled without making this restoration, and the patient is in continual trouble, often to such a degree that mastication is seriously limited, or serious conditions in the form of recurrence of decay or disease of the peridental membranes are threatened. In these cases the remedy is in the restoration of the normal form as above indicated by separating the teeth and refilling.

Many cases are presented in which the proximal contacts are very broad and flat, and the embrasures narrow and shallow. The teeth are thick at their necks and the proximal surfaces very flat. When cavities have occurred in the proximal surfaces of such teeth, it is best to increase the mesio-distal breadth of the teeth as much as possible and make the proximal contacts more prominent than they originally were. This will increase the breadth of the interproximal space and the depth of the embrasures, contribute to cleanliness, give greater comfort in mastication and reduce the liability to recurrence of decay. In cases in which, from loss of contact, by reason of decay or by improper previous operations involving a considerable number of the teeth in the arch, considerable time should be allowed for the whole restoration. One or two of the spaces should be restored, and, when possible, a month of rest should be given for the general adjustment of the arch to the new conditions. Then one or two more spaces should be widened, and so continue to the finish. In this way a very considerable difference may be made in the arch without special difficulty.

The contact points between the teeth become flattened by wear one upon the other. so that frequently, in middle-aged or elderly people, certain of them become so much flattened that they hold stringy foods between them. Food is forced upon the gum septum in every effort at mastication, causing pain,

absorption of the gum septum and disease of the peridental membrane, and, in many cases, decay of the teeth occurs, beginning near the gingival line. These decays are very difficult to treat. See Figures 124-128, inclusive. Whenever these are noticed, their treatment should be undertaken as described in the second volume.

Cavities of the Fifth Class.

Cavities of the fifth class include those occurring in the buccal and lingual surfaces of the bicuspids and molars — not pit cavities, and in the labial surfaces of the incisors and cuspids. They are, therefore, all smooth-surface cavities. They are infrequent in lingual surfaces. In order of occurrence, these are usually later in life than cavities of the other classes, though in this the greatest variety occurs. Occasionally they occur very early, even appearing in the deciduous teeth, but this is rare. Occasionally they occur in old age. In this case they are often termed "senile decay." In the molars, cavities of this class must be sharply distinguished from pit cavities. These are all smooth surface cavities and occur in the smooth portion of the enamel to the gingival of the pit, generally in the gingival third of the surface close to the gum margin. They are somewhat rare before the age of sixteen or eighteen, and are oftener seen at from eighteen to twenty-five. When they begin very early, they are difficult cavities to treat. They are not only difficult in themselves, but are coincident with cavities of the other classes, marking very intense susceptibility and complicating the whole case at an age when the patient is difficult to control. On these accounts, it is the intention to give the general principles of their management very fully in this place, repeating much of that which has been said before under the head of clinical features.

In the buccal surfaces of the bicuspids, and in the labial surfaces of the incisors, there are no pits and all the cavities are of this class. In all of the teeth, including the molars, these cavities begin close to the gum margin. The distance from the gingival line will depend upon the length of the free margin of the gum. When they occur early, the margin of the gum is long and the beginning is some distance away from the gingival line, leaving a good margin of enamel, provided the cavities have not been neglected until they have become so large that it is undermined by decay of the dentin. Some, in which the decay of the enamel is slow, will be placed in better position by the further protrusion of the tooth, or the shortening of the free gum

margin, and decay will cease before penetration of the enamel has occurred. Such areas will become brown or black with the coming of immunity to the region, and remain as dark spots in the enamel. They should not be disturbed. When they begin late, the free margin of the gum has shortened so that the beginning is very close to the gingival line, which soon becomes involved if neglected. When they occur late in life — at from forty to sixty — they most frequently begin just at the gingival line, and often, where there has been some recession of the gums, they begin in the cementum. In old age they usually begin in the cementum. It follows, therefore, that the position of the area of liability in this class of cavities differs considerably at different ages of the patient, being well removed from the gingival line toward the occlusal in the young, close to the gingival line in the adult, and includes the gingival line in middle life and old age. At all ages, however, the area of liability is limited toward the gingival by the free margin of healthy gum tissue; toward the occlusal by the limit of habitual uncleanliness of the surface, and toward the mesial and distal by the margins of the surface, or the angles of the tooth. In the most highly susceptible persons, the superficial beginning of decay may pass the angles of the tooth and join with the area of liability of the proximal surfaces. This never occurs except in cases of unusual neglect.

The first appearance of decay in the enamel is usually in the form of a narrow strip of whitening and softening close to, and following, the curve of the free border of the gum margin, or just at that point of the surface that is least perfectly cleaned by the friction of mastication. The extent of the area of beginning decay will correspond with the area of uncleanliness of the surface. Occasionally this is quite broad occluso-gingivally, but more generally it is narrow, and not infrequently it is reduced to a mere line less than a millimeter in breadth. Mesio-distally, or along the border of the gum, this line varies much in length, but is rarely less than one-third the breadth of the surface, more often occupies two-thirds the breadth, and occasionally extends from the mesial to the distal angle of the tooth. The first penetration of the enamel is usually central to this area, but not infrequently extended in a line of minute breaks, which unite, as they enlarge, forming an elongated cavity. Unless cavities have gained considerable size before they are seen, there is always a streak of softened enamel running away from the cavity to the mesial and to the distal, in which the decay has not yet reached the dentin.

In the preparation of buccal and labial cavities for filling, good management requires that all of the area of uncleanliness be removed at once, including, of course, the last traces of softened enamel, no matter how sound and perfect the dentin may be beneath. The occlusal line of the cavity margin should be placed so far to the occlusal that it will be kept clean by mastication of food, the gingival line should be placed so that it will be well covered by the gum margin, and the mesial and distal lines should be placed at the most favorable points near the mesial and distal angles of the tooth. The object is the removal of the area of liability to decay for the prevention of its recurrence. Wherever the susceptibility to this class of decay is considerable, nothing less will effect a cure. If in these cases the cavity in the dentin, simply, is excavated and filled ever so well, decay will go on so quickly to the mesial and to the distal of the filling that it will be of no value. Formerly these were regarded as the most uncertain of fillings, because of this speedy recurrence of the decay, but since the principles of extension for prevention, as above detailed, have been used in their treatment, these fillings have become almost as certain of long endurance as fillings in occlusal cavities. The main point in their successful treatment is the careful study of the local conditions, the condition of susceptibility being appreciated, and so cutting the cavity as to meet these conditions. This becomes a matter of judgment in each individual case, and upon this judgment success or failure depends. It is always safer to cut wider than necessary than to fall a little short.

The greatest difficulties are met with when these decays occur in the teeth of young persons. In such cases the teeth are more apt to be hypersensitive and the patient difficult to control, and great patience, persistence and moral courage are required of the operator to enable him to carry the cutting to the proper limit. At the same time, the requirements for extension of the cavities are much greater than in older persons. The susceptibility to decay is greater. More time must elapse before there is relief by the coming of immunity, and for these reasons more is required of the filling. Also the free margin of the gum is long in young persons and becomes shorter as age advances, and if these cavities are not extended well to the gingival, the gingival margin will become uncovered and exposed later, and come to occupy the central area of liability to decay. Under such conditions recurrence of decay along this margin is certain if the susceptibility continues and safe cleanliness is not maintained

by the sufficient use of the brush. This can be done, however, and recurrence of decay prevented if the patient is sufficiently careful in the cleaning.

When these cavities occur in numbers in the teeth of young girls or young married women complicated with many proximal decays that interfere with chewing food, and are neglected, the conditions become the worst that are met with in dental practice. These seem not so frequent now as they were thirty or forty years ago for the reason, apparently, that there is not the same neglect of them, but occasionally such cases will be presented. On account of several exposed pulps in occlusal and proximal cavities, the patient becomes unable to chew food, and practically ceases to use the teeth. What food she takes is of the softest variety, often mostly starchy foods, cleaning by mastication fails, artificial cleaning is entirely neglected, cavities of decay are filled with fermentable material, hyperesthesia is greatly increased, and gingival third decays become general. In this condition the patient is harassed day and night with pain, becomes anemic and some intercurrent affection is liable to end life, when under normal oral conditions, recovery would have been easy and sure. Early in my practice a number of these cases occurring together with this result, aroused me more than any other thing that has ever engaged my attention. For some years afterward I extracted all the teeth and made artificial teeth, sometimes in persons not more than sixteen to eighteen years old. As years went on, I found these persons again in very bad condition on account of the great shrinkage of the alveolar processes. They were again placed in a condition in which they could not chew food with any degree of satisfaction or comfort. The result has been a very close clinical study of these conditions and of the treatment possible in these neglected cases in young people.

The first thing to do is to relieve pain, and on account of the extreme sensitiveness of the persons, the most difficult thing is to gain that control of them that will give opportunity for the necessary manipulation. Confidence must be obtained slowly. Artificial cleaning must be instituted, and gradually each sensitive point that interferes with it, eliminated. Exposed pulps must be removed and the cavities filled temporarily. No permanent fillings whatever should be attempted. All buccal or labial cavities in which decay is burrowing in the dentin, should be fully opened by clipping away all overhanging enamel, and left as wide open as possible in order to admit free washing, both in artificial cleaning and by fresh clean saliva. The softened mate-

rial in these should be removed by piecemeal, as it can be done without much pain, and the washing continued with an abundance of tepid water used with the brush after each meal and before retiring at night. With the buccal and labial cavities the whole effort for some time should be directed to the relief of acidity by washings, and the strictest uncovering of all decayed areas, so that the acid being formed in the tissues may be dissolved and removed. But no alkalies should be used; these have continually done harm.

In this way the sensitiveness in the teeth will be rapidly diminished. By careful removal of all hindrances to mastication and encouragement in the use of the teeth, the chewing of food may again become established. When this has been accomplished the operator may leisurely make the permanent fillings required.

This is an illustration of the principles of management that should be followed in many cases of much less gravity than those related above. When this has been carefully done, and good conditions have been obtained for making the permanent fillings, and habits of artificial cleaning have become well established, it is often surprising how quickly complete immunity to caries will occur. But the dentist must not hurry the permanent fillings. For this he must wait until the weakened peridental membranes have regained their strength and tone. No man is able to do his best work in filling teeth over tender peridental membranes. In following these cases with the gnathodynamometer, patients have increased the crushing power with their teeth from twenty-five or thirty pounds to one hundred and sixty or one hundred and seventy pounds, within a few months. With this recovery of normal conditions, any foods may be masticated with pleasure, and the very best of operating may be done.

When these cavities occur as late as eighteen, or later, and are treated promptly, they are not difficult to treat successfully. When good judgment is used and the technical procedures well carried out, good results are very certain and satisfactory. The same may be said of similar cavities occurring in middle life. Those beginning in the cementum in old age (senile decays) are often very annoying, and present much difficulty. The softening often includes a wide area that is so situated as to be very difficult to keep dry. Safe cavity walls are difficult to obtain, and pulp exposure in the canals of the roots, particularly of the molars, is very liable to complicate the cases. Fortunately, these cases are not frequent, but when they do occur, they require a

special study of the local conditions and the very careful application of procedures to meet them.

Cavities of this class are, in the aggregate, much less frequent than cavities of the other classes. In practice the author has found them very annoying from the fact that they have so often occurred after the case seemed fully under control. This has been especially true in women. Young girls quite susceptible to caries have grown up to maturity, other classes of decay having been kept well under control. They have married, and, perhaps, in their first or second pregnancy, a half dozen buccal cavities suddenly appear and urgently require treatment at a time that is anything but opportune, and are therefore especially liable to be neglected. The circumstances make them very difficult to handle.

Prophylactic measures against this class of cavities can be rendered more effective than in any other. The surfaces are so exposed to the brush that they can be perfectly cleaned most easily. If patients, at the first signs of the coming of this class of decay, can be induced to use a brush effectively four times a day, after meals and before retiring at night, regularly, for a few years, they will escape with only the cavities already begun. To be effective, however, the brushing must be done thoroughly and regularly. Only the brush with water is needed.

CARIES IN CASES OF RECESSION OF THE GUMS.

ILLUSTRATIONS: FIGURES 168-171.

Caries occurring in the cementum in cases of recession of the gums on the labial surfaces of one, two or more teeth in mouths otherwise healthy, is not very uncommon. They are always unsatisfactory cases with which to deal. It appears quite certain that the recession of the gum gives the opportunity for the caries, and as the recession of the gum is often progressive, so is the area involved in caries enlarged. Many cases of recession of the gum occur without caries that, to all appearance, are of precisely similar nature. This recession of gum is a very singular phenomenon. Often there seems to be no pathological condition present and thus far very little has been accomplished in the endeavor to limit it, much less to cure it and obtain a regrowth of the lost tissue.

But in this place we are interested chiefly in the management of caries that is liable to begin in the cementum uncovered by the recession of the gum. In many instances this is a broad,

flat decay occupying the surface of cementum exposed, sometimes encroaching upon the gingival portion of the enamel, and, in other cases, sharply limited by the gingival line, as shown in Figure 169. Often the progress is slow. In a very considerable proportion of these cases presenting for treatment, the dentist has the opportunity of treating them before much penetration has occurred, though in others the penetration of the dentin is rapid, forming a deep and dangerous cavity. In this latter case, the only alternative is a mechanical repair by some kind of filling. The choice of this will depend much upon conditions of exposure to view. If it be the upper incisors or cuspids and the lips are very mobile so that the defect is brought prominently into view in the ordinary movements in conversation and laughing, a porcelain inlay would seem to be demanded. This may be made gum color and conceal the recession of gum. If, however, the conditions are such that the defect does not come into view, gold may be used.

Fillings of any kind in this position have been unsatisfactory for the reason that in a considerable proportion of cases the recession of the gum continues to progress, uncovering more cementum and decay again occurs in the part newly uncovered. The filling fails to protect against recurrence of the decay and must be repeated at intervals so long as the recession continues. The filling, whether it be gold or porcelain, does successfully limit the penetration, however, and in that degree is successful. When depth of penetration demands it, filling is the best treatment and the only treatment now known that promises long continued usefulness of the tooth.

On the other hand, those cases that are seen early, before much penetration of caries has occurred, may be treated with silver nitrate and penetration of decay prevented for many years by occasional repetition of the treatment. From the esthetic point of view, this treatment is more unsightly than the gold filling, for the surface decayed becomes jet black. Therefore, its use is limited to those conditions and positions in which this feature is not a very serious objection. In applying this treatment, the rubber dam is placed and the Hatch clamp applied, as shown in Figure 168, so as to give perfect command of the situation. Then the decayed area is cleaned and dried but is not excavated in any degree. Instead, the decayed area is to be filled as deeply as possible with the salts of silver nitrate precipitated by light. It is well to dry the softened area as deeply as possible with the warm air blast. Make a saturated solution of silver nitrate by

crushing a small crystal on a glass slab and adding a single drop of water. Apply this to the area of decay with a thin end of an orangewood stick and saturate the entire area thoroughly. If possible, place the patient in the direct rays of the sun for ten or twenty minutes. In that time an intense black color should be obtained, such as is shown in Figures 169, 170, 171, which were photographed directly from the mouth after this treatment and have had no retouching. If direct sunlight can not be obtained, use the best daylight obtainable and continue the exposure for an hour or more. Many of the cases treated in this way do very well indeed, and it is very easy to follow up a further recession of gum by a repetition of the treatment. It must be distinctly understood that the silver nitrate without the precipitation by light is valueless. It is dissolved out and disappears. It is only the insoluble black precipitate that is effective and the decayed tissue should be filled with it completely and to the greatest depth possible.

Esthetic Considerations.

There would seem to have been sufficient consideration elsewhere of questions of esthetics in the treatment of caries of the teeth without a separate mention under that head. Yet there are some points not touched upon, or perhaps that have not been made sufficiently clear.

The point that gives offense most often in this regard in the treatment of caries, is making gold fillings that are so large as to overlap onto the labial surfaces of the incisor teeth. When this occurs, it is usually made necessary by the burrowing of decay, and the injury to the appearance of the teeth can not be remedied by the ordinary methods of operating. Porcelain inlays may be used in these cases, but their use in young people, in whose teeth the carious process is still active, is not, as yet, to be trusted as sufficiently permanent under these conditions. Therefore, we are limited to making the best appearance possible under the conditions. This *best appearance* is best subserved by making the necessary show of gold in the most perfect tooth form possible. A mass of gold appearing in an incisor that has not the form of the natural surface of the tooth is inexcusable. Such a presentation adds the insult of bad taste in operating to the injury of the loss of the part of the tooth.

On the other hand, if the building of the filling to the form of the tooth has been artistically done in all of its details, there

FIG. 168.

FIG. 168. The rubber dam and the Hatch clamp photographed as adjusted in a case of caries of the labial surface of the right lower cuspid preparatory to treatment.

Fig. 169.

Fig. 169. A case of recession of gum with superficial caries of the uncovered area of cementum after treatment with silver nitrate. Photographed directly from the mouth.

Fig. 170.

Fig. 170. Case of recession of gum and superficial caries of the uncovered area of cementum after treatment with silver nitrate. . Photographed directly from the mouth.

Fig. 171.

Fig. 171. Case of recession of gum and treatment with silver nitrate. Photographed directly from the mouth.

will be a beauty in the expression of the necessary repair which does much to amend the injury.

In many of these cases much can be done by a careful limitation of the cutting away of undermined enamel on the labial surfaces of the incisors and cuspids. Esthetic considerations will often justify some considerable risk of future fracture of weakened enamel that would not be justifiable in any other position. But, when the enamel is so thin and so transparent that the yellow color of gold will show through it, the result will be worse than to cut it boldly away and make a well-executed restoration.

One of the constant errors in filling badly decayed incisor teeth is the failure to restore the full mesio-distal breadth of the teeth filled. There is no other one thing that mars the beauty of a face more than building a gold filling in one central incisor that has lost its contact from decay and dropped against its neighbor, without spreading the teeth apart so as to restore the full mesio-distal breadth and the perfect tooth form. Such a restoration made with a porcelain inlay of perfect shade and adaptation otherwise, would still be a serious blemish. A perfect tooth form is more important to the expression of the general features than perfect color. Hence, a large gold filling of fine outline and finished form will give a far better esthetic effect than the finest inlay of imperfect form. With the same care, however, and the same tasteful tact in the restoration of form, the inlay may be made as perfect in this respect as the gold. The point in either case is the attainment of perfect contour and finish. A failure in this will remain a failure, no matter what the material used or its otherwise perfect adaptation.

In the use of gold in the front teeth, the particular direction of the reflection of light from the filling is of much esthetic importance. Many proximal fillings are made with the labial margin so placed as to show quite plainly and yet do not come far enough to the labial to reflect light to the observer, and for that reason appear more as a dark cavity than as a filling. When the extent of decay makes it necessary to cut so far as this, these will always be better from the esthetic standpoint if cut a little farther toward the labial, or a trifle over onto the labial surface, so that their true character will be plainly apparent. That is, the appearance of a large, well-formed gold filling is much better than a small filling that gives the appearance of a dark cavity. The same rule as to perfect form, comparative size, and position as to reflection of light, applies in the restoration of lost parts of all teeth that come into view, no matter where they are situated

or what material may be used in the restoration. Hence it applies to artificial crowns and to artificial teeth on plates as well as to the restoration of parts of crowns in filling operations.

The marring of the beauty of the form of the teeth by wear is of frequent occurrence in middle age or later, and occasionally in younger persons. In these cases, imperfect occlusion has caused the incisal edges of the front teeth to be shortened irregularly. For instance, the mesial angles of the central incisors may have worn much more than the distal angles, giving the teeth a particularly unsightly appearance. Generally, this appearance may be much improved by so grinding the teeth, that to appearance, the wear will be regular. This may often be done to advantage even when it is necessary to shorten several other teeth in order to regain a neat and pleasant expression of the mouth. Many other forms of irregular wear will be presented in a general practice, in which good taste will prompt a similar correction. Any such work must be directed by good taste and judgment to obtain good esthetic effects. The conditions requiring this kind of interference vary so greatly that nothing more than this very general statement can be given.

MANAGEMENT OF CHILDREN'S TEETH.

ILLUSTRATIONS: FIGURES 172-186.

The conditions calling for differences in the treatment of caries in children's teeth and the management of cases in them, in comparison with adults, are due to childhood purely. Caries in children's teeth is not different from caries in the teeth of adults. An inflamed tooth pulp or an alveolar abscess is the same in its nature in the deciduous tooth of the child as in the permanent tooth of the adult. So far as the tissues of the teeth are concerned, we may make fillings in children's teeth just the same as we make fillings in the adult's teeth. The tissues of the teeth are hard enough; they are strong enough. The differences we must make in operating do not lie in the tissues of the teeth, but are differences due to childhood. We are handling immature persons, whose nervous systems, power of reasoning and of self-control are not yet developed, and we have all of the difficulties that belong to this period of life.

The child is a bundle of impulses, each of which is ready to break into action without notice or restraint. Much too frequently the dentist's first meeting with the child is when it has been wrought up by pain until its nerve endings are all on the alert ready to take fright at the least suggestion of further suffering.

Children are quick to discover a failure to perform a promised service, and if that failure has resulted in pain to them in the attempted operation, or if the suffering, the relief of which was sought, continues, the child-thought is that it has been injured or deceived. They are not much disposed to excuse an operator for difficulties their own actions, or their resistance, have imposed. Their resentment is quick and sharp, and usually without reserve or concealment. On the other hand, they are just as quick to recognize a success. A child who has been tortured by pain and has rebelled and fought against a painful operation for its relief, will, after finding the promised relief and comfort, have a warm smile of confidence for the person who conferred the benefit and readily forget the pain inflicted. Such is the nature of the child. Children act from impulse rather than by processes of reasoning. Touch them right and they are easy of control; when touched wrong, they flash like powder. The important questions in dealing with the diseases of children's teeth that differ from dealing

with similar conditions in adults, is in obtaining that control of the child nature that will give opportunity to do for them that which is best; or to continue expedients that will succeed temporarily until increasing age and greater self-control will give better opportunity.

But this should be said: Never break down the courage of a child by any operation; never break down the nervous system of a child; never give a child a nervous shock that it will recover from tardily; better delay an operation, better do almost anything than do this. It is true that in some cases demanding the extraction of a tooth, we must perform the operation, cost what it will; we must relieve the patient of suffering; but children bear a shock of this kind quite well. If an operation that is very severe is over in a few moments, giving the child the opportunity to recover at once, the child usually will recover without difficulty. Tedious, prolonged operations, those that come day after day, break down a child's nervous system and destroy the child's courage. The child forgets a severe hurt quickly, but the nervous shock that comes from continuous and repeated operations is that which breaks down the child most. There is another thought that it is well for everyone to remember — to succeed with a child is of the utmost importance, if you wish to retain control of the child. To fail of success, is to make an enemy of the child. Therefore, the careful planning of operations for them is of special importance. Children do not forget these things readily; they grow up with an impression of hatred toward this or that person who has undertaken to make operations for them and has failed. On the other hand, if you succeed and gain the confidence of the child, it will grow up your friend and will make other friends for you. These are very important considerations in the handling of children.

In the handling of children the psychic influences are of importance. Some persons control children easily; children take to them, while they seem to shun others; particularly when it comes to operations that are painful, children fail to give them their confidence. Often persons who are skillful operators and able to command a large practice, can not operate well for children; children do not like them for some reason. Others seem particularly fitted for the handling of children in their distress; they control children easily. There is something in the approach that gains the confidence of the child. This can be cultivated in a large degree. Generally those persons who have a great love for children control them well. But this is not the universal rule.

The vagaries of the minds of children are very difficult to understand. Often they will give their confidence to a stranger when they will not give their confidence, so far as painful operations are concerned, to persons whom they know well. One will often do well, on finding that he has failed in gaining the confidence of a child, to recommend it to someone else, or have someone else see it with him. Possibly he may gain the little fellow's confidence in that way and retain it afterward. This will often make a strong favorable impression on a child and it is of great importance in the management of a practice. We are too liable to neglect the little children; feel that operations for them are not of much consequence. But children make men, and their friendship tells in after-practice. One will often have to do that for children that will not seem to pay in dollars and cents; often it is necessary to spend time with them in which little or nothing is done; time for which one will not feel like making a proper charge. In many cases this is necessary. Often when a child is first brought to the dentist he should only temporize; not try to do this or that operation which seems necessary at the time, but do something to the mouth or to the teeth, something that will lead the child to suppose that an operation has been successfully begun; not something to deceive, but something to gain the confidence of the child; one should never deceive a child. If it is necessary to hurt a child, say so. Usually, with children, a deception is fatal to after-success. A dentist should not allow parents to deceive children in his office. Often the greatest difficulty in the management of children is the management of the parents. Parents should not deceive their children with regard to these operations. To tell a child it will not be hurt, and then inflict severe pain, is doing that child a wrong; it is lessening that child's confidence in humanity; and children ought to grow up with confidence in the integrity and honesty of those about them.

Relation of Growth and Shedding of the Deciduous Teeth to Their Treatment.

While the main difficulties in the management of children's teeth are in the directions indicated above, there are matters pertaining to the progress of development of the deciduous teeth, the absorption of their roots in the process of shedding, their replacement by the permanent teeth and the development of the roots of these, that must have careful consideration at every step of operations upon the teeth of children. Considered from this

standpoint, we should regard all persons under fourteen or fifteen years old as children; for the development of the permanent teeth, exclusive of the third molars, which we need not consider, is not completed until about that time.

The deciduous teeth of one side of the upper jaw are represented in outline considerably enlarged in Figures 172, 173. In the first of these, the growth of the crowns and the roots of the teeth is represented by figures placed upon the individual teeth. In the second, the absorption of the roots of the deciduous teeth is represented in a similar way. The two, taken together, give a brief synopsis of the changes which take place, together with the average time in years occupied. The calcification of the deciduous teeth, according to this chart, Figure 172, begins in the central incisor at about the seventeenth week of uterine life. Reading from left to right, the position of the 0 on the various teeth represents the average calcification at birth, the figure 1 represents the growth of the roots at one year, the figure 2 the growth at two years, and the figure 3 at three years, when the growth of all of the roots of this set of teeth are complete. It must be understood that this is a representation of averages from which there are wide variations. Also, that it has little to do with the time of cutting, erupting or presentation of the teeth through the gums. The time of this is probably more variable than the process of calcification. Yet, careful study of cases shows that there is a fair relation between the calcification and the cutting of both the deciduous and permanent teeth that is of much value in the management of cases when the history can be obtained. While it does not invariably follow, it is so with sufficient frequency that we may reasonably expect that if the teeth of a child have been very late in erupting, the completion of the calcification (the growth) of the roots will also be later than the average time. This history is often of great value.

Premature eruptions of teeth. Occasionally cases of premature eruption of teeth have been noted, i. e., cases in which the crowns have protruded through the gums before sufficient root has formed to serve as support to the crown, and as a consequence the crown has been displaced. Within the observation of the author, this has occurred only with the incisors. In one the central incisors were found erupted at birth. Other cases have been noted in which the teeth were erupted before there was sufficient growth of dentin to form sufficient root to maintain them in position. These latter have in each case been a single central incisor erupted soon after birth and much in advance of the other

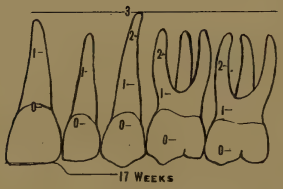

FIG. 172.

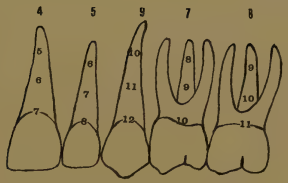

FIG. 173.

FIG. 172. Diagram of the deciduous teeth, considerably enlarged, representing the progress of their calcification. 0, placed upon the individual teeth represents the progress of calcification at birth. The figures 1, 2 and 3 represent, in years, the progress of the calcification of each tooth. The intention is to represent averages. It must be understood that considerable variations will be found.

FIG. 173. Diagram of the deciduous teeth considerably enlarged, representing the absorption of the roots. The figure placed over each tooth represents, in years, the average time of the beginning of the absorption of its roots. The figures placed upon the roots of the teeth represent, in years, the progress of the absorption of the roots of the several teeth. Considerable variation from the general average, and also in the order of progress, must be expected. Not infrequently the absorption of the root of the second molar is completed before the completion of the first.

teeth. These are supposed to have been due to accidental malpositions of the developing teeth.

We may fill the roots of deciduous teeth after removing the pulps that have become exposed from caries, or other cause, the same as we may fill the roots of permanent teeth. But it would be manifestly wrong to place arsenic in such a tooth to destroy a pulp or to undertake to remove a dead pulp, treat and fill roots in these teeth before the roots have completed their growth and the pulp canals have been narrowed to minute openings. Such a condition necessarily defeats the success of the procedure. Happily, we are seldom presented with cases seeming to call for such an operation at so early an age, but, occasionally, these do occur. Then, if the age is close to the time of the completion of the roots, a history of the age at which the deciduous teeth were erupted becomes of especial importance in the prognosis, and should often determine whether or not such an operation should be undertaken.

ABSORPTION OF THE ROOTS OF THE DECIDUOUS TEETH.

The next difficulty encountered is the absorption of the roots of the deciduous teeth preparatory to the shedding process. This is shown in brief in Figure 173. In this, the average date, in years, in the life of the child, of the beginning of the absorption is placed over each tooth. The progress of absorption, in years, is represented in figures placed on the root of each tooth at the point to which absorption has progressed, which may be read for each individual tooth at a glance. These figures represent averages from which there are wide variations. Of late, certain writers have used the phrase "decalcification of the roots of the deciduous teeth," to which there is serious objection. We should use either the word absorption, or resorption — not decalcification. If we place a tooth in a weak solution of an acid, it will be decalcified — i. e., the calcium salts, the substance which gives the tooth its hardness, will be dissolved out, leaving the body of the tooth, the basic animal substance, remaining. In this, the normal physical and histological form of the dentin is preserved in its completeness. In caries of the teeth the dentin is first decalcified by an acid, leaving a softened mass which is afterward decomposed, forming a cavity. Decalcification means something entirely different from what we mean by the word absorption, as used to represent the physiological removal of the roots of deciduous teeth, or the removal of bone, or of catgut ligatures used in

surgery, etc. In the absorption of the roots of the teeth, or any of these substances, the whole of the tissue is removed complete without a perceptible softening in advance. The whole process is something entirely different from what we know as decalcification.

Absorption of the root of the central incisor begins, practically, when the child is four years old and is ended at seven. The lateral incisor begins to be absorbed at five years and is ended at eight. The absorption of the root of the first deciduous molar is begun at seven and completed at ten years. The second molar has begun to be absorbed at eight and is completed at eleven. The absorption of the cuspid root begins at about nine years and is completed at twelve. In the formulation of this statement, it has been the endeavor to put it in a form that will be easily remembered. (1) In the absorption of the roots of the deciduous teeth the incisors begin, the central at four, the lateral, five; (2) skip a tooth and a number and the molars begin to be absorbed, the first at seven, the second at eight; (3) skip back to the cuspid which begins to be absorbed at nine years.

There is a difference in time in the absorption of roots of teeth between different individuals. Some will be a year or so early or as much late. Also, the time between the individual teeth of the person may be considerable. Perhaps this four and five years for the central and lateral is not quite the average; four and four and a half would be more nearly the average; but this is a figure that is easily remembered and is placed in that way, as being the closest proximation in whole numbers. Occasionally the lateral incisors fall away before the centrals, but that is rare. Often they fall away about the same time, or very close together; not six months between. Often again, there will be two years between. With the molars it is the same way. Often the second bicuspid will be in place before the first bicuspid, the molars having fallen away in this order. All of these differences may be found. It does not run absolutely as represented in the illustration, but this represents a fair approximation to the average.

When the absorption of the root of a tooth has proceeded some little distance, it would be improper to place arsenic in that tooth for the purpose of destroying the pulp. While the root is complete, arsenic may be used for destroying pulps in the deciduous just the same as in the permanent teeth, but one must have a care as to the time at which arsenic is used. Furthermore, if the root of a tooth is absorbed half way, a root filling could not

be made successfully if the pulp was destroyed and removed. The root canal would, in most cases, have a wide open end that would interfere with this operation. One must be on guard continually as to that. One must have in mind a clear conception of the conditions in the case in the placing of arsenic or in attempting to fill roots of temporary teeth. We may fill the roots of temporary teeth before the absorptive process begins, just the same as the roots in permanent teeth. The absorptive process will go on at the proper time; the root filling will stand up in the tissues, produce, apparently, no irritation, and the absorption will go on just the same as it will in a tooth with a living pulp. These little molars, the roots of which have been filled in this way, come away with the three legs of root filling — gutta-percha or gold, standing up in the tissue, seeming to have produced no irritation whatever.

ACCIDENTS DURING ABSORPTION OF ROOTS OF THE DECIDUOUS TEETH.

A number of what we may call accidents, occur during this absorption of the roots of temporary teeth. First, if there is an alveolar abscess at the root of a temporary tooth and that abscess is continuing in a chronic form, the rule is that absorption of the root will fail. The death of the pulp of the tooth does not interfere with the absorptive process. The question is simply as to the condition of the tissues about the end of the root. The absorption of these roots is a physiological process, and, in order for it to progress properly, the tissues about the root, the peridental membrane, must be in a physiological condition. If disease is going on there, such as we have in alveolar abscess, the absorptive process will be defeated and different kinds of trouble come up on account of it. Often a tooth is bodily pushed out of the way, the other tooth taking its place, seemingly, by physical force. In other cases, the permanent tooth is deflected from its proper position. The apical end of the root of a central incisor is occasionally pushed labially, while its neck is held nearly in normal position. Less frequently the same thing may happen to a lateral incisor or a cuspid, but the forms of the teeth replacing these are such that they are more liable to slip to one side and be deflected from their normal positions. The broad cutting edge of the central incisor is that which most frequently pushes the root of the deciduous tooth labially, causing the end of the root to protrude through the gum and sometimes into the lip of the child. These cases are not very frequent, and yet they are sufficiently frequent that we should recognize them when they

present. In case of alveolar abscess, the bone about the end of the root will be absorbed, leaving an opening in which there is only soft tissue. The crown of the permanent tooth comes down, moving forward and downward, and strikes the lingual side of the root of the temporary tooth and begins to push it away, as shown in Figures 174, 175, 176. A pathological condition here prevents the absorption of the root; pus is lying around it instead of normal tissue. The result is that the apical end of the root of the deciduous tooth is gradually pushed over to the labial, and the permanent tooth following up, the end of the root of the deciduous tooth is finally tipped out through the gums, under the lip, as illustrated in Figure 175, and, occasionally, cuts into the lip, as shown in Figure 176. Whenever the examination of a child near the age at which the deciduous incisors are shed, reveals a sore point under the lip and some bony substance appearing in the tissues, it should at once be supposed to be the apex of the root of the deciduous incisor, and, placing an instrument upon that and a finger upon the stump of the incisor, and moving it a little, it will be found that they move together, which will confirm the diagnosis. Then, of course, the remedy is to extract the root. It will generally be found that the permanent tooth is pushing the root out of its way. This will be met in practice quite often if one has many children to deal with. In the author's practice some years ago, a slight little girl was presented in whom a sore under the lip from this cause had been neglected until the lip had been cut through and the apex of the root was found in the "running sore" on the skin under the nostril. At the time, the little girl was very thin in flesh, anemic, and had a temperature of 101 degrees. Yet, the sore seemed in a chronic condition without any extended inflammation or swelling. It was reported to me that a physician had been looking after the case for some weeks, evidently without discovering the cause of the difficulty with the lip.

In the absorption of the roots of the deciduous molars, a difficulty is found that is somewhat different. Often the crown of the bicuspid will come between these wide-spreading roots, the roots will be absorbed only near their junction with the crown, and the ends of the roots will be left unabsorbed. These will be found sticking in the alveolar process or gums after the bicuspid has taken its place; sometimes abscesses occur in consequence of this, or occasionally considerable soreness without abscess. Occasionally the unabsorbed portion of the root will remain between the bicuspid and the proximating tooth, expand-

FIG. 174.

FIG. 175.

FIG. 176.

FIGS. 174-176. Diagrammatic representation of a condition which occasionally occurs, when, because of pathological conditions about the apex of the root of a deciduous incisor, absorption of the root fails. Figure 174. The permanent incisor moves downward and forward to assume its position in the arch and strikes the lingual surface of the root of the deciduous tooth near its apex. Figure 175. In the continued movement of the permanent incisor the apex of the root of the deciduous tooth is tipped to the labial and pushed through the gum tissues under the lip. When this is allowed to continue, a condition shown in Figure 176 is liable to occur, in which the apex of the root of the deciduous tooth gradually works its way into the lip itself, resulting in suppuration.

ing the arch and making room for itself. These are usually easily removed if the conditions are recognized. They produce very much less trouble than the roots of incisors. Recently a student brought me a lower first and a lower second bicuspid, which he had just extracted, to ask an explanation regarding a singular growth on the proximal side of the apex of the root of each one of the teeth. Upon examination, I found each of these to be the apical half almost entire of the roots of a deciduous molar, or possibly of the distal root of each deciduous molar that had remained in the jaw and had become attached in this way. One of them was slightly movable, and therefore was attached only by the fibers of the peridental membrane, though the attachment was very firm. The other was immovable and was evidently attached by cementum. No history of any difficulty from these retained bits of roots was discoverable. Occasionally the root of a cuspid will be found — a long root — being thrown out under the lip in the same way as the incisors. This root is occasionally so long that its end will be too high to pass out under the lip and the labial side of it will appear in the opening.

Occasionally an abscess will occur at the end of the root of a temporary molar before the enamel of the crown of the bicuspid has been completed, and, in that case, the pus may break into the enamel organ and destroy it, or a part of it, so that the enamel of the crown of the bicuspid will never be completed. Then it will come through as an imperfectly enameled tooth. I have observed a number of these cases, one in my own family, where an abscess occurred very early at the root of a temporary molar, in which there was a good deal of swelling and a good deal of pus. I suspected at the time that there would be injury to the bicuspid, and when the bicuspid presented the enamel was imperfectly formed, not having been completed. This has occurred a number of times under my personal observation. Sometimes these injuries closely resemble atrophy in appearance, but are readily distinguished from that class of injury by being confined to one or two teeth. But it is only occasionally that we get injury from alveolar abscess that has occurred quite early at the root of a temporary tooth.

Not very infrequently the failure of absorption of an abscessed temporary molar will hold back and delay the eruption of a bicuspid; and it is often difficult to determine the cause of this delay satisfactorily without an X-ray picture. This, however, will show the condition clearly enough to complete the diagnosis. These cases illustrate the peculiar value of keeping

accurate records of cases. A severe alveolar abscess may occur early at the root of a deciduous molar, be relieved by discharge of the pus, or the removal of the offending tooth, and be forgotten. When the bicuspid takes its place with imperfect enamel, no one knows what has occurred. If there is a record of the prior condition and the treatment, the two incidents become properly connected as cause and effect. A number of cases have occurred in the author's practice in which necrosis, as a result of these abscesses, has brought away the permanent tooth with that portion of bone immediately surrounding it. These things lead one to believe that the sufferings of children with these conditions are not sufficiently appreciated. It is certain that the little ones are much too often neglected.

The absorptive process seems to be very fickle in its beginning and in its progress, and there are many cases of variation from the normal. In some of these, the absorptive process seems to be hurried and it will be completed before the normal time so that a temporary tooth will drop away before the permanent tooth has come forward, and the child may be without a tooth for a year or two; whereas, in the normal process, when the little tooth drops away, the permanent tooth should present at once. These cases are not so frequent, however, as delayed absorption. Delayed absorption of roots occurs quite often, so that the coming tooth will be deflected from its position. If the absorption of a root of a lateral incisor or cuspid is delayed, the coming tooth will generally strike its lingual surface and be deflected to the lingual. Deflections to the labial are more likely to occur from other causes, but deflections to the mesial or distal, the tooth making room in the arch for both itself and the retained deciduous tooth, are occasionally seen. In case of the bicuspids, the crowns are normally between the spreading roots of the deciduous molars, and in case the absorption is delayed, generally the coming bicuspid is simply held back. In the upper jaw it may escape from between the spreading buccal roots and be deflected to the buccal, so that the tooth will come out to the buccal of its normal position in the arch. In the lower jaw they may be deflected either to the buccal or to the lingual, but they are more generally simply delayed, held back by the lack of absorption of the roots. Indeed, the absorption of the roots of the temporary teeth does not seem to be especially stimulated by the coming of the permanent teeth, for they are often absorbed when there is no permanent tooth to come. When that happens, the absorption occurs in accord with a process of nature, and

this process is varied somewhat, as I have stated. In the case where a permanent tooth fails to develop, which occurs occasionally with the lateral incisors, the absorptive process will generally go on and the little tooth drop away, notwithstanding the fact that there is no permanent tooth to take its place. The cuspid tooth, on the other hand, generally remains if there is no permanent tooth coming forward to take its place. If the cuspid happens to be deflected from its position from some other cause, or becomes impacted within the bone by taking a wrong direction, the deciduous cuspid often remains in its place, the absorption only partially removing the root, and may be found in its place on up to middle life, and in a few cases it may be seen continuing in its position and doing service until old age.

These retained deciduous cuspid teeth require somewhat careful handling. It is often difficult for us to know whether the permanent tooth is likely to come forward later or not. The author has seen them come forward as late as twenty, and in one case in which the person was twenty-five years old, but generally, if they do not come forward somewhere near their normal time, we need not expect them. Often much light may be thrown on this by an X-ray picture, which will show the position of the permanent cuspid. If it is not present that fact may be determined. It is often important that we retain these deciduous cuspids, not only for the appearance, but for the real service that they will do, and as they are liable to decay the same as other teeth, they require filling.

In handling these teeth, any considerable disturbance is likely to hasten the absorptive process and cause the tooth to loosen and fall away, or at least it has been observed in a number of cases where these deciduous cuspids, that seemed quite firm in their position, have fallen away soon after a filling was made. This observation has occurred so often as to suggest strongly that a considerable disturbance of the peridental membrane by much malleting is very liable to start up this absorptive process afresh and cause the loss of the tooth. Therefore, when it is necessary to make fillings, these teeth should be handled very cautiously.

Occasionally we find temporary molars remaining in position, and, in a few instances, a bicuspid is seen deflected mesially or distally and takes its place beside the temporary molar; but, generally, if they are deflected at all, they will be deflected to the buccal in the upper jaw or to either the buccal or lingual in the lower. These teeth do not often remain so late in life as

the cuspids, yet I remember one case in which the patient had one deciduous molar still remaining when he died, at about seventy-two. This little tooth had done service all these years, and, of course, where there is a possibility that a deciduous tooth will do this kind of service, it is important that it have the best treatment we can give it.

Latterly, the X-ray has come to be of great value to us. A picture will determine the position of impacted teeth, and in this way information is gained that will be of great value to us in determining whether or not a deciduous tooth should be retained. Generally, if an X-ray shows the permanent tooth in proper position, and apparently held back, the proper treatment will be the extraction of the temporary tooth, with the expectation that the permanent tooth will come forward; generally it will. Heretofore we have not had the opportunity to make this observation. If the permanent tooth was in its normal position, it was very difficult to tell whether it was there at all or not by any examination we could make, previous to the discovery of the X-ray. If it is deflected somewhat to one side or the other, we will find an enlargement that will enable us to detect its presence. Therefore, it is advised, where it becomes important as to the treatment of a retained deciduous tooth, that an X-ray be made in order to understand better the position of the permanent tooth.

A somewhat singular phenomenon occurs occasionally with deciduous teeth that have been retained longer than the usual time of shedding. This is most often seen in the molars. The general rule is that, when these teeth are not shed at the usual time, they are carried upward (toward their occluding teeth) by the growth of the bones, and remain in occlusion. Sometimes, however, this seems to have failed and the deciduous molar, or the two of them, retain their position in the bone, and the growth of the jaws and the movement of the permanent teeth carry the occlusion away from them. These teeth are then often almost overgrown by the gums. I have models of a case in which all of the deciduous molars were retained in this way in a boy almost fifteen years old. The occlusal surfaces lacked eight and one-half millimeters (one-third of an inch) of coming into occlusion, when the permanent teeth were closed together.

In the case just cited, X-ray pictures were made which showed the bicuspids in place between the roots of the deciduous molars. These teeth were then removed. Only a little absorption had occurred in the crotch formed by the spreading roots,

and the crowns of the bicuspids were found uncovered in the wound. Generally such teeth should be removed at once if the X-ray shows the succedaneous teeth in proper position.

Occasionally these cases, as the one just cited, give an object lesson in the movements of the teeth that are made concurrent with and forming a part of the movements in the lengthening of the face, which occurs in the change from the child to the adult.

Treatment of Caries of the Deciduous Teeth.

This is one of the most difficult subjects in dentistry. Not that caries in these teeth is in any wise different from caries of the permanent teeth, but the conditions under which we must treat caries of the deciduous teeth are very different from the conditions under which we treat caries in the teeth of adults. We have the child to deal with, and occasionally the little child, for we may find caries beginning in their teeth as early as two years old, and occasionally earlier. When it occurs so early, we may feel certain that caries is going to be very severe and that it will destroy the teeth quickly unless some remedy that is effectual is used. And the question is, how are we to apply our remedy to the teeth of the baby? None of us like to hurt a child; none of us like to perform such an operation as seems to be required by force against its struggles and its cries. Just there is the difficulty, and it is practically the only difficulty, so far as making fillings is concerned. We may make fillings in these teeth just as well as in the adult teeth; there is nothing in the condition of the tissues of the teeth that will hinder making these fillings, and if the extensions are made sufficient to protect the area of liability to decay, fillings will stand well. True, none of us have observed so many fillings for these little folks as for grown-up people, but enough of them have been observed for us to feel sure of this statement from the clinical standpoint. This is strongly supported from physical examination of the teeth. The technical procedures in making fillings in these teeth would be the same as in making like fillings in the teeth of adults and will not be discussed here. Where we find conditions in which we can make fillings, we should not hesitate to make them.

The general rule is that we can not make metallic fillings for these little folk; we will have to resort to other methods. In many cases we can not reasonably make the proper excavation. These teeth are as painful as the teeth of older people,

and our sympathy for the child will prevent us from doing that which seems necessary to be done. We must temporize in our treatment. How can we temporize to advantage, becomes the question. Can we make successful use of prophylaxis by artificial cleaning of the areas of liability to caries and in this way prevent caries? In highly susceptible families, this would have to be begun very early to be successful. While the teeth should be kept generally clean, the more especial attention should be confined to the areas of liability. These are occasionally found with beginning decay of the enamel within a few months after they come through the gums. Is it possible to handle these bad cases in this cleaning process? Those who are especially interested in the development of this method of combating caries will do well to try handling the little ones in very susceptible families.

TREATMENT OF DECAYS OF THE DECIDUOUS INCISORS AND CUSPIDS.

In consideration of other methods, there are certain conditions peculiar to the child that are important for us to consider. We may say that by the end of the third year (speaking of the deciduous incisors and cuspids particularly), the growth of the jaws and the development of the permanent teeth in the region of the roots of the deciduous incisors have begun to carry these little teeth slightly apart; at least, the effect of the growth will prevent these teeth from dropping together if the contacts are cut away at this age. And, as the child grows older, the tendency is for these teeth to stand apart. This we can take advantage of in the treatment and do that which we can not do with the permanent teeth. We can cut them apart freely, make spaces between them, and these spaces will be self-cleaning and remain permanent; that is, after the child is about three years old. The teeth will then be in contact as shown somewhat enlarged in Figures 177, 178. One of the best methods of treatment for decays of slight depth that have started in the proximal surfaces of the incisors or the mesial surfaces of the cuspids — such as are shown in Figures 179, 180, is to file them out, or file them partly out. With a small chisel or an 8-3-6 hoe excavator, chip away the undermined enamel. Make the cavity as broad as possible in that way so as to reduce the amount of filing. Then with a thin jeweler's file, cut them flat from labial to lingual. Do not cut the full depth of the decay in the dentin, but only the depth of the enamel. That can be filed away without arousing sensitiveness, and, when necessary, may be done a little at

Fig. 177.

Fig. 178.

Figs. 177, 178. The deciduous incisors considerably enlarged. Figure 177 gives the labial view and Figure 178 the lingual view.

Fig. 179.

Fig. 180.

Figs. 179, 180. Caries of the deciduous incisors of such moderate degree as to permit of treatment by cutting, followed by the use of silver nitrate. Figure 179 is the labial view and Figure 180 the lingual view.

Fig. 181.

Fig. 182.

Figs. 181, 182. The same as Figures 179, 180 after filing away some of the proximal surfaces and treatment of the areas of decay with silver nitrate. Figure 181, labial view. Figure 182, lingual view.

a time on different days. Leave the decayed material in the dentin where it is. Do not disturb it or attempt to remove it. The removal of this is particularly painful to the child. Cut away the angle of the tooth and follow straight toward the gingival, leaving the surface flat, being careful to incline the file so as to cut most from the lingual surface, making a V-shaped opening as shown in Figures 181, 182. In making these cuts, it is best to note carefully the position of the gum septum, and, if possible, avoid cutting so far that the gum tissue will overlap the cut surface; for this will often make a little pocket in which it will be difficult to prevent decay starting afresh. The little fellows, unless there is something that hurts to prevent them, are good feeders and will bite through foodstuffs enough to keep these spaces pretty well cleaned and it is now easy to supplement the natural by artificial cleaning. When these have been cut in this way and finished with polishing tape or the disk, if some decay is left or some dentin is exposed, it should be treated with silver nitrate. To do this, first lay a crystal of silver nitrate on a glass slab and crush it. Have some water and an orangewood stick cut to a point ready (an ordinary wooden toothpick with a flat end may be used). Put a single small drop of water on the crushed crystal and make as nearly a saturated solution as possible. Slip the rubber dam over the teeth, hold it with the fingers of the left hand, dry the cut surfaces and apply this solution to the cut surface and the decay in the dentin until it is well saturated. Now, if it is possible to place the cut surfaces directly in the sunlight for ten minutes, do so. The mirror can be used to reflect the sun's rays directly onto the cut surface. If the direct rays of the sun can not be had, use the brightest light available, and, if possible, continue it longer. If time enough can not be given at a first trial to obtain a full black color of the carious dentin, try again at another sitting and another until it is obtained. Generally, after one or two sittings, the child will learn just what is wanted and plenty of time can be given. Each carious area, such as shown in the illustrations, should be treated in the same way.

The object in this treatment is to fill the part of the dentin softened by decay with the insoluble salt of silver that has been precipitated by light, and incidentally to destroy the organisms in it. That portion of silver nitrate, which has not been precipitated by light, dissolves out within a short time and is gone; it is of no value. It is useless to endeavor to treat such

decays with silver nitrate without this exposure to light. But when the full black color is obtained, decay is generally effectually stopped. To do this requires such control of the child as will enable one to use the file a little at a time and succeed in shaping the surfaces and in polishing them. This may be done with a thin stone in the engine and finished with disks. In this work the child need not be troubled with the rubber dam or any close confinement. But in applying silver nitrate, the rubber dam should be used. Applications made without it will generally be useless. One should make no attempt to tie on the rubber dam. Indeed, nothing should be done that is likely to cause pain. When this has been held in position for ten minutes, or longer, if the child is not too restless, throw a stream of water on it to wash away superfluous silver nitrate and end the sitting for the day. When it is apparent that the first application is ineffective, make another after one or two days. Repeat this as often as may be necessary. All exposed dentin and the decay should assume a full black color. Sound enamel will not be stained. Any silver nitrate precipitated on the surface of the enamel will disappear within a few days.

Generally decay is effectually stopped by this treatment if the teeth and cut surfaces are kept fairly well cleaned. The cleaning may be done by the mother or the nurse after proper instruction. The dentist, however, should see these cases frequently to know that the cleaning is well done. He may find it necessary to repeat the treatment with silver nitrate occasionally. Sometimes we find caries of the enamel beginning in the gingival thirds of the labial surfaces. If these can be discovered before the enamel rods have fallen out, they may be cleaned, using caution not to break away the frail enamel, and treated with silver nitrate without further preparation. Then the cleaning with the brush should be effective.

Either this incipient decay of the enamel or the deeper decays of the proximal surfaces will be stopped, provided the surface is such that it can be kept fairly clean. In this treatment one will escape most of the painful part of the operation in the treatment of these cases, for the little filing that is to be done will generally not be very painful. This is applicable to the proximal surfaces of incisors and cuspids and to labial cavities. The labial cavities, from which enamel rods have fallen, can not be cut away very completely, but we can break away the enamel and trim it carefully so as to make these depressions as smooth as possible and then treat them in the same

way, and, by proper instructions to parents, they may be kept clean by brushing, and the teeth, although mutilated and out of shape, will be useful to the time of their shedding. All cases treated in this way should be carefully watched, and if any sign of the recurrence of decay is noted, the silver nitrate should again be applied.

A word of caution should be said about the use of silver nitrate, and it is an important one. It must not be used if the decay has approached near the pulp of the tooth. There is nothing else that will cause so severe a toothache as silver nitrate used over a pulp that is nearly exposed by decay. Personally, I have had a few very memorable experiences with it. The pain was so severe and so uncontrollable that I felt compelled to sacrifice important teeth. One may use silver nitrate with perfect freedom wherever there is a good coating of sound dentin over the pulp, but we must not risk affecting the pulp. Of course, up to a certain age we have the recourse of destroying the pulp and removing it, but after the beginning of the absorption of the roots that recourse is lost to us. Treatment with silver nitrate should be confined strictly to shallow cavities. It is not well suited to deep cavities in which there will be accumulation. Its success depends much upon strict cleanliness and free washings by the fluids of the mouth and by foodstuffs after the treatment. Other plans of treatment must be employed for deeper cavities. The application of the silver nitrate seems to be of much benefit also in beginning caries of enamel. When it has been precipitated freely among the loosened ends of the enamel rods, decay does not rebegin so readily and such vigorous cleaning is not necessary to hold it in check.

A word as to the handling of children in this class of cases. A dental school clinic is not a suitable place to handle little children. We are practically debarred by the conditions from teaching this clinically in schools. If I am to handle children, I want to know the parents; I want to know that they are depending on me to manage the teeth of their children and that I will have their assistance and sympathy in this management. I will not undertake, further than for present relief, the handling of children of strangers, and I would not advise anyone to try to do it. Remember that in undertaking to treat decay of these teeth, it is a thing that one must begin to-day and follow it up from week to week and from year to year, until the shedding time of these teeth, and one should have that particularly in view and have the parents particularly impressed with this necessity.

Of course, we can not expect much assistance from the child, as the rule. Yet, many of them become enthusiastic and do their part most bravely. Furthermore, the prophylactic work with the tooth brush must be done by the parent or the nurse, and this should be insisted upon, and when we have made a silver nitrate treatment we must expect to have the child brought to us and examine these teeth from time to time and see that decay has not again started and is making inroads. We may, if decay is again starting up in some part of a surface that has been treated in this way, treat it again and stop it again, and again, if necessary.

There are some objections to this method of treatment. The first objection is that it makes the cut surfaces of the teeth very black, and often this will show through the enamel and give it a very bad appearance. This adds to the disfigurement caused by the necessary cutting. For this reason, it is a very objectionable practice from the esthetic standpoint, and yet, with all of its objections, it is often the best we can do. Parents will object to the discoloration of the teeth in many cases; yet, if the child is very sensitive, we can scarcely do better than to use this method. The teeth can be made to look very much better by other methods of treatment, however, methods that will be more painful to the child.

WE MAY EXCAVATE THE CAVITIES AND FILL WITH CEMENT, HILL'S STOPPING, OR BASE PLATE GUTTA-PERCHA. Where we can succeed in making the necessary excavation, this should be preferred, but to fill with these materials at all successfully, we must excavate the cavities quite thoroughly. In filling these little teeth with cement, I should not insist upon extensions of the cavity — extensions for prevention — but should simply remove the decay, cutting away the overhanging margins of enamel and making the filling without any considerable effort at extension. Unfortunately, the cements are not reliable and in many cases they will wash out from these little teeth very quickly; in some other cases again, they seem to stand quite well. Sometimes cement fillings, put in early, stand until the teeth are shed. But whenever fillings of this class are used, the child should be seen frequently and the fillings renewed if they waste away, or are found to be very leaky from shrinkage. Extensions of decay beside the filling will also require treatment. We need to watch these teeth much closer than we watch the teeth of older persons, for changes occur rapidly; the predisposition to decay is often very severe, so that the

teeth decay very quickly indeed, and, unless we keep a very close watch of them, we will find that they have decayed badly in the interim. In this connection, it is especially unfortunate that our cements are so unreliable. A cement that we may use this week and find afterward that it is doing good service, may not be good next month. These changes that occur in the cements are very vexatious. No means has yet been devised by which they can be prevented, but very earnest search is being made. Of course, wherever we can, a gold filling is the right thing to make, but the cases where we can make gold fillings successfully in the teeth of little children are very few. It should be undertaken only when we have the most positive assurance that a really good filling can be made. Also, we must be especially careful to preserve the courage of the children.

THE TREATMENT OF DECAYS IN THE OCCLUSAL SURFACES OF DECIDUOUS MOLAR TEETH.

In these we should not care particularly for the color, and we may use any of the filling materials without the color objection that pertains in the incisors. If we obtain control of the child before the decays are large, we may break away the enamel from about the cavity, open it as widely as possible, and then use silver nitrate, not, in this case, entirely for the purpose of stopping decay, but for the purpose of relieving the sensitiveness. For this purpose it should be used in almost precisely the same manner that we would for the stopping of the carious process in shallow cavities. After the action of the silver nitrate for a week or ten days, having applied it two or three times, we will generally find that the sensitiveness has been relieved, and then we may cut out the decay and make a filling. In the meantime, especial care should be taken in washing the cavities clean after eating and keeping them so that they will be washed freely with the fluids of the mouth. The difficulty with these decays in the occlusal surfaces is that, unless we can open them very wide, they will fill up with food which will ferment and the decay will again progress, notwithstanding the treatment with silver nitrate. Therefore, this treatment should be mainly for the purpose of obtunding the sensitiveness in order that we may excavate and make a filling. In this, we are running the risk of considerable discoloration of the dentin that will show through the enamel. We will not always succeed well with this process; sometimes the sensitiveness will remain and hinder us from making a sufficient excavation, but the case will be the

better for the use of the silver nitrate in the limiting of the decay that will occur, even if we do not entirely succeed. We may repeat this again and again, if the cavity is not so large as to encroach too near the pulp of the tooth. When these have been excavated, they may be filled readily with amalgam, or with gold in some cases. When a case can be handled sufficiently well to fill with gold, one should not use silver nitrate and have the tooth blackened about the margins of the filling, but should excavate and fill the cavity just the same as for an adult. There is no difference whatever in the operation except that we have the child to deal with. Taking it all in all, amalgam seems to be the best material for filling this class of cavities, though oxyphosphate of copper cement is often doing excellent service.

TREATMENT OF DECAYS IN THE PROXIMAL SURFACES OF DECIDUOUS MOLAR TEETH.

These are difficult in the extreme to handle. The deciduous molars are larger than the bicuspids which come in their place, and they are in many cases considerably crowded when the permanent incisor teeth come through. The deciduous cuspid tooth is also smaller than the tooth which will replace it. If we cut the proximal surfaces of the deciduous molars, they usually fall together very quickly, consequently we are, in a measure, debarred from that method of handling proximal cavities in them; and yet not entirely, for, if we can treat these cavities when they are small, we may, by a different method, cut them out without separating the teeth so far as to be in trouble from their dropping together. Generally we will find these decays beginning pretty close to the occlusal portion of the surface, or near the marginal ridge, and the form of the crown is such that if we slope the cut well to the linguo-gingival, i. e., slope our cutting toward the gingival on the lingual, we may cut away considerably without entirely destroying the contact of these teeth, or, if we destroy the contact, leave enough of enamel upon the proximal surface toward the buccal so that it will come against the enamel of the next tooth, making a new contact that will be good and sufficient. The occlusal surfaces of the deciduous teeth are represented somewhat enlarged in Figure 183. In Figure 184 they are represented as the proximal surfaces should be cut in this treatment. Generally decay has occurred in the bucco-lingual center of the occlusal third of the mesial surface. We may make a cut in this way, sloping linguo-gingivally, and leave a portion near the buccal angle of the surface to make a new contact. They

Fig. 183.

Fig. 184.

Fig. 185.

Fig. 186.

Fig. 183. The deciduous teeth of the left side of the upper jaw, showing no caries.

Fig. 184. The same as Figure 183 after treatment of caries by cutting out broadly to the lingual for the partial removal of carious areas in the proximal surfaces and treatment with silver nitrate. Note particularly the contacts left to the buccal of the separation.

Fig. 185. The deciduous teeth and the permanent first molar of the right side of the upper jaw.

Fig. 186. The same as Figure 185 after treatment of caries by cutting a V-shaped opening to the lingual for the removal, in part, of proximal decay and treatment with silver nitrate. This illustration includes the treatment of the distal surface of the second deciduous molar. Incidentally this frees the broad mesial surface of the permanent first molar from a broad area of near approach to the second deciduous molar.

will not drop together sufficiently to let the cut surface make a contact. The danger in cutting away the proximal surfaces of the permanent teeth is that the flat cut surfaces are liable to come together, by the twisting of the teeth in their sockets, and make a flat contact that holds food and debris which will very certainly cause decay. If we can cut the deciduous teeth as Dr. Robert Arthur recommended for the permanent teeth (which, by the way, has gone entirely out of use now because the teeth would drop together and make flat contacts), we can hold the deciduous teeth in position and keep the surfaces in a form that will be self-cleaning until the normal time of shedding. One should be especially careful to make cuts of such form that food going into them will slide toward the lingual and pass out in that direction, and in this way keep the cut surfaces continually clean. If we cut these boldly apart, cutting away the entire proximal surfaces, the teeth will usually not come together entirely because of the wide spreading of the roots. In cases in which I have done this, difficulty is experienced from the fact that there is a broad gum septum exposed, and in the act of mastication, food is forced upon it and it becomes so painful that the child will almost refuse to chew meats or any food that requires considerable mastication, and the teeth become almost useless if cut sufficiently to keep them apart, i. e., if the whole proximal surfaces are cut away so there will be no contact. We must always be on our guard about cutting too far, and this treatment should be used only in cases in which cavities are neither large nor deep. We may use silver nitrate in these cases and not cut out the entire decayed area, just the same as in the incisor teeth.

It will often become necessary to treat the distal surface of the second deciduous molar after the first permanent molar has taken its place, as represented in Figure 185. In that case, the distal surface of the temporary tooth may be cut as shown in Figure 186, but in no case should the mesial surface of the permanent molar be cut in this way. If that tooth has a decay, every step in its treatment should be to the end of placing finally a filling in perfect form. Temporary expedients may be necessary to gain the conditions for a successful operation, but when these conditions can be had, the filling should be made.

Filling these proximal cavities is a difficult proceeding on account of the sensitiveness and on account of the difficulties of position. The teeth are generally strongly bell crowned; the gums usually come up into the interproximal spaces very near to the contact, even though we find some decay; it is only after

decay has progressed for a considerable time and food has lodged, that the gums are out of the way. One of the difficulties of the treatment by cutting is that we will come upon the gums.

Another difficulty is the proximity of the pulp of the tooth. The pulps in the deciduous molars are large and we are liable to encroach upon the pulp too closely if the cavities are too large to cut out in the way mentioned. Of course, where we can control the child to prepare these cavities and make fillings, even though we can not make much extension, it is still the better method to make fillings rather than cut away the surfaces, and for this purpose I should say that there is nothing better than a good amalgam filling, if well put in and polished properly afterward. This matter of care in putting in these fillings, however, is just as important as it is in the teeth of adults. We should not neglect any detail because we are handling a child, for, with them, decay is so much more rapid that any little neglect of this kind will tell more quickly than it will in the teeth of adults. The polish should be well made. If we can handle a child to put in the filling, we can at a subsequent sitting obtain a good polish and then the filling will be serviceable.

Thus far it has been presupposed that the children are brought to the dentist sufficiently often that he may be able to follow up the treatment. Not only this, but it is supposed that children have been brought to the dentist early enough so that he has been able to handle these decays before they are large; and, where this is done, one ought to succeed in the treatment of these teeth. But the difficulty that confronts one in practice is that parents too often bring their children after decay has progressed so far that toothache has already occurred. Parents do not realize that decay is going so far; they may notice that there are decayed spots in the teeth and be anxious about them, but at the same time, are likely to put off all effort at treatment until the child has a sleepless night with toothache. The child is already tortured with pain; anything one may do will hurt the child inordinately and one has the worst possible condition to begin with. In this case we are reduced to the alternative of temporizing or immediate extraction. The first effort will be to relieve pain, and for the present nothing else should be done. If possible, the child should be made comfortable, and the treatment continued at a subsequent sitting, after the child has slept and recovered its composure. If the pulp is exposed, which will generally be the case when the excavation is made, you may destroy it, remove it and fill the roots, and in this way succeed,

provided the absorption of the roots has not begun. That must be looked into carefully, but if the child is brought at an age when the absorption of the roots has begun, there is practically no alternative but to extract the tooth or cut away the pulp by the use of cocaine and fill the remaining portion of the canal, running the risk of alveolar abscess. It is generally best to extract the tooth as the alternative, notwithstanding the injury that is liable to result. We are presented with conditions in which we are unable to do anything else, and we should not try to do the impossible. Wherever the age of the child will allow, carefully destroy these pulps and fill the roots, and in this way preserve the teeth. That operation has been done sufficiently to fully test its merits, and we know that it is as successful as it is with the teeth of the adult, provided we use sufficient caution as to the time at which it is done.

It should be remembered always that success in the treatment of these teeth depends on the same care as the treatment of the teeth of the adult. The fact that they are to serve only for a short time is fully counterbalanced by the other fact that the tendency to caries is much greater in the child; so that because of any little neglect in operating, decay will recur more rapidly and the fillings will be more quickly undermined and destroyed. For this reason, careful attention should be given to every detail of the operations upon them.

THE CHILDHOOD PERIOD OF THE PERMANENT TEETH.

ILLUSTRATION: FIGURE 187.

The childhood period of the permanent teeth comprises the time from their first appearance through the gums until the growth of their roots has been completed, exclusive of the third molars. This includes the time from about the sixth to the fifteenth or sixteenth year. During all of this time there will constantly be some permanent teeth present in the mouth that can not be treated as temporary teeth, nor as we might treat the teeth of an adult under certain conditions brought about by causes that may be presented. The roots of the permanent teeth are not completed until some time after they have taken their places in the arch. During this time of growth they are liable to rapidly progressive caries, the pulps are much larger than in adult life and are therefore especially liable to become exposed by caries or in the preparation of cavities. In the event of exposure we are debarred from removal of the pulp and making a root filling in the tooth affected, up to the particular time of the completion of the growth of the root and the narrowing of its apical foramen to a very small opening. Therefore, we will often be presented with conditions in which exposure of the pulp of the tooth by caries means the loss of the tooth no matter how important it may be to the future of the child. The period, therefore, includes the consideration of the growth of the roots of the permanent teeth and the treatment of caries to which they are liable. It will be noticed that the childhood period of the deciduous teeth overlaps considerably the childhood period of the permanent teeth. But these should always be held distinctly separate in the consideration and treatment of caries, even though the cases in each field may occur simultaneously.

Growth of the Roots of the Permanent Teeth.

Passing to the consideration of the growth of the roots of the permanent teeth, we will yet consider the patient a child, although he or she may have the adult teeth.

The time of the eruption of the permanent teeth is, normally, the same as the shedding of the deciduous teeth, but it is specially given in the figures placed below each tooth in Figure 187.

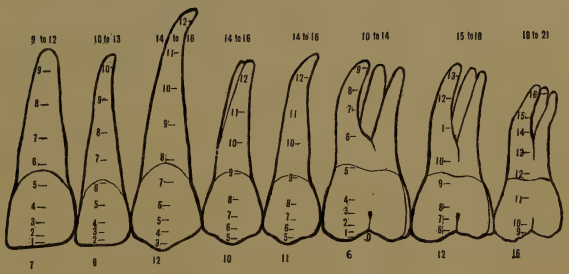

FIG. 187.

FIG. 187. A diagrammatic representation of the progress of the calcification of the permanent teeth. The teeth of the left side of the upper jaw are represented in outline. Below each tooth a figure is placed which represents the average year of the eruption of that tooth. Upon each tooth figures are placed at intervals representing the date, in years, of the progress of its calcification to that time. The relation of the progress of calcification between the different teeth, or the contemporaneous calcification lines, may be found by following any individual figure from tooth to tooth. The figure 7, for instance, is on the junction of the middle and gingival thirds of the root of the central incisor and, reading from left to right, it gradually drops down to a little below midlength of the crown of the second bicuspid; it then jumps to about half length of the root of the first molar; then back to the junction of the occlusal and middle thirds of the crown of the second molar. It does not appear at all on the third molar. Any other year may be followed in the same way. The first of the two figures placed above each tooth represents a date at which the apex of the root of that tooth has frequently been found sufficiently narrowed to permit of root filling. The second figure represents the date at which the apex of the root is still occasionally found too widely open for root filling. Even wider variations will sometimes be found. It must be remembered that in such a diagrammatic representation, only an approximation to a general average can be expected. Tolerably wide variations from this average will occur.

The incisors, cuspids and bicuspids are often called the succedaneous teeth, because they take the place of the deciduous incisors, cuspids and molars. The roots of the teeth are not complete when the crowns first present through the gum; they are only partially grown. That is a general rule to which there are some exceptions. The exceptions are almost wholly with teeth that have been delayed in erupting from the causes which have been mentioned. Generally the root of the tooth will be completed somewhere near its normal time, even though the eruption of the tooth may be delayed. There are exceptions, however, to this rule. Sometimes a permanent tooth is delayed in its formation, so that the delay is actually caused by the later development of the tooth. This seems to occur to the lateral incisors oftener than to other teeth. It is not very uncommon to find these one or two years late. Occasionally, but much less frequently, a bicuspid, or some other tooth, is late in its development. Excellent and very reliable studies of this may be made when one has learned to read the signs correctly, in cases of atrophy. The atrophy marks in the enamel occur on the particular part of each tooth that was being developed at the same time. The irregularities in the position of these lines show clearly what teeth, if any, have been late in the development of their crowns. Occasionally a bicuspid is found to have begun the formation of its crown abnormally early and receives the atrophy mark with the incisors, which is contrary to the rule. It is not very uncommon to find the marks on the lateral incisors, showing that they have been late in their calcification. Occasionally, also, when we find an atrophy mark near the incisal edge of incisors and look to the first molars, we find the atrophy mark at half length of the crown, showing that these teeth had begun their calcification at an earlier date than normal, etc. This is a condition that is difficult to diagnose, but occasionally we are surprised to find the root of a tooth not fully developed at a much later time than the normal.

The first molar is the slowest tooth in its development with which we have to deal. The calcification of this tooth has usually begun at birth. I have made examinations in many cases of still-berth at term, and in but few have I found a failure of the beginning of calcification of this tooth. Yet, the tooth does not erupt until the child is six years old, or during the sixth year; the child is generally nearer six and a half years old; occasionally we will see them presenting a little before the sixth year, but the average is somewhat later than the six-

year-old point. Somewhat rarely, much wider variations from the average time is seen. In one case I saw the first permanent molars through the gums and in occlusion at four years old. Again, two little girls just five years old, cousins, had the first molars in full occlusion. Delay to seven and a half and even eight years has been known, but such delays are rare. The roots of these teeth are rarely completed before the tenth or twelfth year, giving four or five years after the eruption of the crown for the development of the root, and, in many instances, the length of the root is not complete until six years after eruption. If we extract these teeth before the eleventh or twelfth year we will generally find that the apical foramina have not been closed down to a small opening. The important point is the relation of this closure of the apical foramen to the destruction and removal of the pulp and the filling of the roots. The chart, Figure 187, represents the contemporaneous calcification lines in figures placed upon each tooth, a figure for each year during its development, representing the progress of its calcification. By following any given figure from tooth to tooth, the particular part of the root developed at the year represented will be found. When information is desired regarding any particular tooth, the figures placed upon it give the growth for each year. The figures placed above the roots of the teeth give the earliest date in the age of the child at which the apical foramen of the roots have frequently been found sufficiently narrowed to permit of root filling and the latest date at which they have still been frequently found not sufficiently narrowed. In this the occasional cases of abnormally early teeth and abnormally late teeth are not included.

In considering the lengthening of the roots of the teeth, we must give about another year after the root has attained properly its length for the reduction of the size of the apical foramen. The length of the root of the first molar, coming through at six years, is sufficiently complete at from ten to twelve years; that is, from four to six years after its eruption. The central incisors, erupting at six or seven, will have the foramen sufficiently closed at about nine to twelve years; three to five years after eruption. With all of the other teeth, we may allow three to four years after eruption. The lateral comes through at eight, will be completed from eleven to twelve; the first bicuspid comes through at ten and will be completed at from thirteen to fourteen; the second bicuspid at very nearly the same time. The cuspid will be complete at about fifteen to

sixteen, coming through at twelve. I have never seen a cuspid that was not complete at sixteen, yet I know of several cases where they were decidedly incomplete at fifteen, and they are generally incomplete at fourteen. We occasionally have conditions calling for the destruction of the pulp in the second molar before the roots have been completed. I have had a number of cases in which I destroyed the pulp of this tooth too early, removed the pulp and found broad, open apical foramina that defeated root filling. We can not calculate certainly that this tooth will be completed before the person is fifteen to eighteen years old.

In cases of delayed eruption, we should always be on our guard as to the removal of pulps. A patient may present with a tooth in position, and without gaining a history of the tooth, we may not know that it has been delayed in eruption and be unable to make a root filling because of the lack of development of the root. One case came to me a number of years ago, where a friend of mine got into difficulty, and got me into difficulty, too, with a patient of mine who happened to be visiting him. He found an exposed pulp in a bicuspid, or one that was so nearly exposed that he destroyed it. He returned the patient to me, stating in a note that he had gotten into trouble with the tooth — an abscess had formed that would not heal. I found he had lost a pledget of cotton through a broad, open root canal. I cut through the tissues and removed the cotton. I cut off considerable of the root and filled it with gutta-percha, but the tooth was lost some six months afterward. Possibly, if the circumstances had been known, that tooth might have been tided along for a year or so without destroying the pulp, giving opportunity for the apical foramen to be narrowed down. We should be as careful as possible not to destroy pulps before the roots are completed.

It is deplorable to have a patient present with an exposed pulp in an important tooth, the root of which we know to be only partially developed, making it impossible to remove the pulp and make a serviceable root filling. My advice is not to undertake to do impossible things. In cases in which there is a possibility of the root being sufficiently developed, the effort should be made to treat it, but the patient or the parents should know what may be expected, that it will probably be necessary to extract the tooth.

Intercusping of the First Permanent Molars.

At the risk of going somewhat beyond the field intended in this book, I must call attention to what I will designate as the proper intercusping of the first permanent molars when they first come into occlusion. The teeth are formed so that the teeth of the lower jaw will intercusp with the teeth of the upper jaw in a certain way, which is very clearly shown in the photograph, Figure 101, of this volume. Also the forms of the teeth are such that if they miss the exact position in which they should occlude a little way only, as they come into occlusion, the tendency is to slide on the slopes of the cusps in such a way as to bring them to the exact relative positions designed — a most beautiful provision of nature for correcting slight deviations that should be closely studied until its meaning is clearly understood. When, however, the teeth are so much out of normal relation at the time that the teeth first make contact in coming into occlusion that the points of the cusps overstep each other ever so little, the wrong slopes become the moving force directing them into an increased abnormality of position. That is to say, if the mesio-buccal cusp of the upper first molar should strike the point of the mesio-buccal cusp of the lower first molar in such a way that its distal slope instead of its mesial slope slides on that cusp, the upper molar will be pushed to the mesial instead of the distal and the abnormality will be increased instead of being corrected. In that case, the upper first molar will be one full cusp width too far forward in its relation to the lower first molar. This error will then be forced upon the other teeth, crowding the front part of the upper arch so that there will be either protrusion of the upper front teeth or irregularity among the bicuspids or cuspids as a result. On the other hand, the case may be reversed. In the relation of these teeth to each other as they approach in coming into occlusion, the lower first molar may be quite a little forward of its normal relation to the upper, but so long as the point of the mesial cusp of the upper strikes ever so little to the mesial of the point of the disto-buccal cusp of the lower first molar, the sliding on the slopes of the cusps will correct the malposition. If, however, the position of the point of the mesio-buccal cusp of the upper first molar should be ever so little to the distal of the point of the disto-buccal cusp of the lower first molar, the sliding will increase the malposition instead of correcting it. The result will be an irregularity or a protrusion of the lower teeth. In this the buccal

cusps only have been mentioned because these only are shown in the available illustration. The lingual cusps, particularly of the upper molars, play an important part on the same principle mentioned for the buccal cusps. This error when these teeth come into occlusion is the basis of more irregularities of the teeth than any other one thing. The opportunity for this, however, is usually found in caries of deciduous molars by which they have been lost, lost their crowns, or some part of their mesio-distal breadth, which allows one or the other of the first molars to stray too far from its normal position in coming into occlusion with its fellow. Dentists having families of children under their care should discover this particular error in its inception and contrive means for its correction at that time and prevent the impending irregularity.

Special Functions of the First Permanent Molars.

The first molars have special functions to perform. They seem to have been so placed and timed in their coming into position for these special purposes. They come into position, occluding with each other, just before the shedding of the deciduous teeth begins. Normally, the shedding process begins almost immediately they come into full occlusion. The front part of the arch is soon broken by the shedding of the deciduous teeth and these four teeth stand in occlusion, propping the jaws in the position they should occupy during the shedding of the deciduous teeth and during the reformation of the arch. They hold the jaws firmly in the position they should occupy during the growth and development of the face. In the examination of a considerable number of cases, it is found that, with the effect of disease and the irregularities that occur in the absorption of the roots of the deciduous teeth and their replacement by the permanent teeth, the support of the jaws is many times almost completely lost but for the presence of the first molars. They do much more than this. Accompanying the shedding process there is a rapid growth of the bones of the jaws and face, making for the changes of the features from the form in the child and the modeling of the features of the adult. Particularly the space from the lower orbital ridge to the crest of the alveolar process between the teeth is increasing, the depth of the lower jaw from the crest of the alveolar process to its lower border is increasing. Together these are lengthening the face from above downward. At the same time the whole front of the face is being carried forward, increasing the distance from

the ear to the front of the mouth, modeling out that prominence of the features that makes a large part of the difference in the cast of the countenance between the child and the adult. It may be said that the deciduous molars act to support the occlusion in the early part of the shedding period, but this is readily shown to be only in part by the many cases in which the bite is raised off from these teeth in the progress of growth of the first molars. The models referred to previously, of the mouth of a boy almost fifteen years old, whose deciduous molars had not been shed and had not been lifted by the growth of the alveolar processes, illustrates such a condition. The upper incisors and cuspids overlap the lower in position to slide freely upon each other and could be no support to the occlusion. The jaws are held firmly in position by the four powerful first molars. These, in their usual movement in the lengthening of the face, which is clearly one of their normal functions, have caused the stationary deciduous molars to be carried apart about one-third of an inch between their occlusal surfaces. This abnormal case shows plainly the function of the first molars, not alone in holding the jaws in their proper relative positions while the occlusion is broken up in the shedding process, but that they also, by their movement in harmony with the general growth of the face, carry the jaws farther apart and in this way assist in the formation of the features by lengthening the face.

When these teeth are lost early by decay, which occurs much too often, there is apt to be much distortion of the features resulting. This is sufficiently apparent from careful clinical observation, as has been noted by many men. From all of these sources of information it seems certain that in the general growth that is going on no part is taken by the deciduous molars after the normal time of the beginning of the absorption of their roots. In most cases they may be carried forward passively with the expansion, or lengthening of the bite, but in many it seems clearly demonstrable that their continued presence later becomes a positive hindrance to development. In these cases at least the normal development would not occur if the first molars had been lost. No measurements have yet been made by which the particular directions of distortion and the amounts have been determined. Apparatus for this work has been constructed, but at the time of writing not enough work has been done to give sufficient basis for exact statements. When this work has been done, it will probably furnish more exact information, and, in view of this, a lengthy discussion of this problem seems unwise.

Further consideration in a general way will be given to the evils resulting from the early loss of the first molars in connection with the consideration of caries of these teeth.

Caries of Permanent Teeth During the Childhood Period.

The first molars and the incisors are particularly liable to caries during the childhood period. The first molars suffer much the oftenest. The fact that these teeth take their places very quietly to the distal of the deciduous molars without the dropping away of any of the deciduous teeth to announce their coming, serves to conceal their eruption. Parents generally do not know of the presence of these teeth, or do not realize that they are permanent teeth. They are, therefore, more frequently neglected than any other teeth.

First permanent molars. The lower first molars are usually the first of the permanent teeth to be attacked by caries. The decay is almost always in the central pit of the occlusal surface, but occasionally in the buccal pit also. Cavities in a similar position in the upper first molars begin soon afterward. This is so common and the effects of this early beginning of decay in these teeth are so grave, that it requires special consideration. These teeth are the first of the permanent teeth erupted and are usually through the gums by the middle of the sixth year of the child's life. In this, however, there are pretty wide variations which have been noted. They are often deeply decayed by the eighth year and generally require fillings by that time in families in whom there is considerable susceptibility to caries. There are no other teeth that are so often lost from inattention at the proper time as these. There are no other teeth easier to protect by proper attention correctly timed. The early loss of the first molars is from occlusal decays in about ninety-five per cent of cases, and these are the easiest cavities to manage when taken in time. They are also the most important of the molar teeth. They are the largest, strongest and most effective in mastication. For several reasons, which have been given above, their loss causes more derangement of the masticatory apparatus and of facial expression than any other, not even excepting the incisors, for these have not so prominent a function in the general development. If these latter are lost early or late, the loss is replaced artificially. The form of the face and the expression, which would otherwise be marred by shrinkage to fill the space, is prevented; and mastication is not seriously deranged. How-

ever, when the first molars are lost, the damage is practically irreparable. The occlusion of the remaining teeth is necessarily deranged by the falling backward of the bicuspids and the movement forward of the remaining molars. When they are removed as early as the ninth or tenth year, the space of the first molars will be closed by these movements of the teeth and the occlusion will be better than if lost later, but the normal prominence of the front teeth and lips will be wanting, which is a permanent injury to the expression of the face. The occlusion will be imperfect at best; in many cases it will be very defective, for often the molar teeth assume such an inclination to the mesial that the occlusal surfaces do not meet fairly together but strike only upon the distal cusps, rendering mastication imperfect. If one only is lost, the incisor teeth are generally crowded to that side in the filling of the lost space, moving away from the median line and seriously deranging the expression of the mouth. When two are lost on the same side, the teeth occupying the front of the mouth generally will be thrown to that side. Both theoretically and practically, it seems best, when one must be lost, to extract all four to obtain greater regularity of the features. Few operators, however, have the moral courage to sacrifice two or three good teeth for a possible gain in occlusion and expression in the somewhat remote future.

The time at which first molars are lost is important. They are the first of the permanent teeth. They are placed to the distal of the deciduous set. When they have taken their places and the upper and lower teeth have occluded with each other, the shedding of the deciduous teeth begins. The first molars hold the jaws in position and preserve the symmetry of the face while the deciduous teeth are being shed and replaced by the permanent ones. The second molars are not erupted until the twelfth year, and by this time the shedding and replacement of the teeth have been nearly completed; therefore, in case these teeth are lost before the deciduous teeth are replaced by the permanent ones, the face is apt to be shortened because of the lack of support for the lower jaw, the normal movement of the front of the mouth forward is diminished and derangements in the occlusion occur. All of these considerations demand that these teeth be protected; yet children are brought to us continually with their teeth decayed beyond all hope of repair, and they must be removed as the lesser of two evils. In many cases in which permanent repair is impossible, the teeth may receive such treatment as to render them comfortable and use-

ful temporarily. Under these circumstances, the operator is able to choose the time for their removal. On this point there is much difference of opinion, but most careful observers agree that the best arrangement of the features and the remaining teeth will be obtained when they are removed some time before the eruption of the second molars, or about the ninth to the tenth year. My own observation corroborates this opinion. At this time enough of the teeth in the front of the mouth will be in position to give the occlusion considerable support; the second molars, in erupting, will come forward nearly into the position of the lost first molars; somewhat less flattening of the face will occur than when they are removed earlier; the surfaces of the second molars will usually be in better occlusion and the interproximal contacts will be much better than when these teeth are removed later. My own observations, however, do not lead me to the opinion that, when there is no longer a hope for their permanent retention, there is a material gain in waiting to the ninth year that compensates for the dangers of suffering and discouragement to the patient in the treatment of these teeth in cases that promise much difficulty and pain. Therefore, in many of the cases presented, I should remove them at once as the lesser of two evils. It is especially desirable at this time that the little patients be not troubled with teeth that are frequently sore and interfering with the free use of the teeth in the mastication of food. To have a child in a condition of inability to masticate food in comfort for a considerable time because teeth are sore, establishes a habit of bolting food that is very damaging to the physical development of the person.

In the consideration of the question of permanent retention of these teeth, the superficial area of the decay is of secondary importance. The depth of the decay, its relation to the pulp of the tooth, and the condition of the pulp, are the important questions. In adults, if the pulp of the tooth becomes involved, we may remove it and retain the tooth in serviceable condition. With the first molars in patients eight or nine years old we are debarred, and under twelve years old we are likely to be debarred from root-filling because the apical foramina have not been narrowed by the completion of the growth of the roots. Really root-filling is decidedly unsafe before the fourteenth or fifteenth year. Even when done at from fourteen to sixteen my observation leads me to the conclusion that most of these teeth with root fillings are lost before the person is thirty years old. Therefore, if the pulp has become hopelessly involved, the tooth will be lost and

may as well be extracted at once. To retain the tooth for a few years, or even eight or ten, is bad management.

These considerations should lead to the utmost care in the management of these teeth. Whenever possible, cavities occurring in pits or fissures should be filled early — before considerable progress has been made — and should, if the self-control and physical condition of the child will permit, be filled permanently with gold. It is only necessary to uncover the decayed area, form the cavity with solid parallel walls, and follow out sharp grooves to good finishing points, no other extension being needed. The enamel in the neighborhood of these carious areas is not subject to decay because of the friction of mastication; therefore, a good filling once made is permanent. As I have been doing this generally for many years and noting results carefully, I feel free to say that the only question is in being able to make a good filling. Amalgam can be substituted for gold, but at this age of the patient the greatest degree of susceptibility is present, and this demands the best of material and the most careful operating, and gold is the safer material.

In deep cavities involving considerable dentin, especially if unusually sensitive, no attempt should be made to both excavate and fill at the same sitting for children under ten years old. In the first place, this is likely to be too much for the endurance and self-control of the child; and, second, thermal sensitiveness being somewhat aroused by the carious process, hyperemia of the pulp might readily be precipitated by completing the operation at one sitting. The better way is to make a temporary filling of red base-plate gutta-percha. The walls of the cavity should be well dried with absorbent cotton (no hot-air drying should be used) and saturated with eucalyptol to secure the cohesion of the gutta-percha. By this plan a perfectly tight filling can be made. The case may then be dismissed for twenty or thirty days. In that time the sensitiveness will be diminished and the danger of hyperemia of the pulp materially reduced, and, if the child is under good control, the permanent filling may be inserted. I would caution operators, however, about allowing gutta-percha fillings in these teeth to go for a longer time. Generally children who have not been forced into caution by the presence of highly sensitive cavities are vigorous chewers of food and will wear out gutta-percha fillings rapidly. Whenever there are reasons for longer delay the gutta-percha filling should be inspected and, if necessary, renewed.

Often in these cases, if cavities are not deep, there will be a

rapid improvement in the condition of sensitiveness, if the overhanging enamel is well removed, so as to give full, free admission of the fluids of the mouth to the cavity. These will dissolve out much of the acid and other irritating substances from the decaying mass, diminish their concentration and reduce the irritation to the dentinal fibrils, partially removing the cause which has aroused the hypersensitiveness. In many cases, those in which decay has not approached near the pulp, the saturation of the softened mass with a solution of silver nitrate and exposing it to a bright light until it becomes black is very effective. In this case the cavity may be left open for a month or more. The risk of some blackening of the dentin by the silver nitrate is justifiable if by this means it becomes possible to make a good filling. This remedy should never be used in deep cavities, because of the liability to produce intense pain.

In cases in which hyperemia of the pulp has occurred and there have been paroxysms of pain at frequent intervals, a thorough excavation of the cavity should be made. This may, if the sensitiveness of the tooth and the condition of the child require, be divided into several sittings, using an antiseptic and filling with gutta-percha for protection during the intervals. The excavation must finally be made complete, however, in every case, removing every particle of softened dentin before any attempt at permanent filling is made. It should be determined definitely whether or not caries has actually reached the pulp. If it has not, the case may safely be regarded as simple hyperemia, and even though there may have been very severe paroxysms of pain, the chances are favorable for recovery by simply keeping the cavity well filled with gutta-percha for several weeks or months. It is difficult to prevent children hurting these teeth by temperature changes. Parents should be instructed to withhold hot and cold foods and drinks, and, if the weather is cold, to keep them well housed or especially guarded against breathing cold air through the mouth when out of doors.

In the above we have considered only those forms of treatment looking to the early permanent filling of the first molars with gold. Many cases will occur in which this will not be the wisest course because of our inability to carry out the treatment successfully. In these it is best to use temporary fillings of such a nature as to give considerable time. These may be made of oxyphosphate of copper, of Hill's stopping, or of amalgam, with the understanding that they are expected to serve a temporary purpose only, awaiting the opportunity to make permanent fillings.

Accidental exposure of the pulp while excavating, if done according to rules given in technical procedures in filling teeth, while adding another serious complication, does not greatly add to the danger. After the application of "1-2-3," or oil of cloves, the exposure should be capped with oxyphosphate of zinc. To make a successful capping, it is required that all decayed material be removed from the cavity. Then take a bit of ordinary writing-paper and cut a piece that will cover the exposure and overlap well in every direction, or in this class of cavities it should cover the whole pulpal wall and fit fairly well. Be sure that everything is in perfect readiness, the rubber dam in place and the cavity dry. Having tried the prepared paper and found it of proper size, flood the cavity with oil of cloves, "1-2-3" or other equally non-irritating antiseptic. Then prepare some oxyphosphate of zinc, mix it rather thin and spatulate well, continuing the spatulation until stiffening is just beginning, so that a globule may be held on the bit of prepared paper. At this moment dry out the cavity and at once introduce the paper with the globule of cement directed toward the exposure and very gently tap it into position so as to spread the cement over the whole of the pulpal wall of the cavity and cover the exposure without unnecessary pressure. Leave this without disturbance of any kind for fifteen or twenty minutes, or until assured that the cement is well stiffened. Then place a good gutta-percha filling over it and allow this to remain for one month. If this has done well, reinforce the cement covering by an additional layer, before making a permanent filling.

Success in capping pulps depends, first, upon the selection of suitable cases, and, second, upon the accuracy of every detail in carrying out the procedure. The best cases are those in which the exposure has been made in cutting hard dentin with a broad blade, such as the 20-9-12 spoon, which will not drop into the pulp chamber and lacerate the pulp. If the pulp has been exposed while cutting with a bur, debris from the blades is apt to be forced into the pulp tissue. This makes the condition very bad. If the pulp is found exposed, and by this is not meant fully open to the saliva, but contact of carious material with the pulp, the case is of the gravest character. The pulp will certainly be infected and inflamed, whether there has or has not been paroxysms of pain, and with any treatment, over fifty per cent of the cases will be lost. In children, however, a sufficient minority of cases recover to demand that the effort be made in the more favorable cases. Much tinkering in the treatment should be

avoided. If the case does not do well after one or two straightforward efforts, abandon it without further worry to the child. In this class of cases every failure, or rather every period of hyperemic excitement, diminishes the chances of recovery and adds materially to the difficulty of controlling the child. The treatment giving me the greatest percentage of success has been given above. Sometimes, a second effort will succeed when the first has failed, but a third is not advisable.

When these cavities are presented to us in patients fifteen years old, or over, they present no more of difficulty than other pit cavities. Other teeth are not so often deeply decayed so early after presenting through the gums and do not demand attention when the child is so young. They are, therefore, not so frequently neglected, and when they do occur, the increased self-control of the patient makes the treatment easier and more certain. Decay involving the loss of the pulp in any tooth before the completion of the roots, involves the loss of the tooth for the reason that root fillings can not be successfully made. This fact should be ever present in the mind of the practitioner, and the time of the completion of the roots of the individual teeth as perfectly known as their variations will allow.

It not infrequently happens that the mesial surface of the first molar begins to decay while still in contact with the second deciduous molar, and this will be the first proximal cavity. In children of good self-control and endurance, these should be prepared and filled with gold when discovered, even as early as the eighth year. In the reverse conditions in which the teeth are excessively sensitive and the child very difficult to control, it is better to use gutta-percha, zinc phosphate or copper phosphate temporarily, await the shedding of the deciduous molar and seize the opportunity when the whole proximal surface is exposed to view to make the permanent filling. The operator must not be tempted by these favorable conditions into making this a simple cavity without due extension for prevention or without cutting the full retention seat in the occlusal surface. He must form the proximal surface and contact point to meet with the second bicuspid, which will be quickly in position. A principal point in the treatment will be to determine what will be the area of liability when the bicuspid is in position and include it in the area of the filling. Failure in either of these directions will be fatal to the future of the filling. If existing conditions will not allow these things to be very well done, it is better to use temporary expedients and await better opportunity for making permanent fillings.

All that I have said as to the management of the child, conditions of sensitiveness of dentin, of thermal sensitiveness, of pulp exposure and of the time of extracting when that is necessary, while speaking of occlusal cavities in these teeth, applies here.

Lingual pits of the lateral incisors, rarely in the centrals also, are the only other pit decays that are found at so early an age. These are not nearly so frequent as decays in the first molars, and, as a rule, occur somewhat later. Occasionally, however, these are found soon after these teeth are in position; and while the gums still overlap the enamel so much that it is very difficult to get the rubber dam placed without inflicting considerable pain. Nothing can be done without the dam, and this is often the most serious difficulty met with in these cases. The best plan is to say to the child: "This will hurt for a few minutes," force the ligature or special root clamp to position, being careful to be successful at the first effort, and hold it until the pain has abated. If a ligature is used, it must not be forced on the labial also and drawn tightly, as that will cause unnecessary pain and do injury by cutting the gums from the proximal surface of the tooth. Personally, I very much prefer to hold the dam in position with a special instrument in the left hand while making the filling with the right than to use either ligature or clamp. But in these cases the special root clamps used in treating and filling crownless roots will do good service. When the cavities have not made much progress, the actual excavation and filling present no great difficulty. Usually these are not so sensitive as the pit cavities in the first molars; they are less in area and the excavation and filling are more quickly done. Whenever the endurance of the child will possibly permit, these cavities should be excavated and filled permanently with gold at one sitting. The difficulty in placing the rubber dam seems to demand this. When patients are older and these teeth have protruded through the gums sufficiently to render the placing of the dam reasonably easy, they give but little difficulty. This cavity is, however, likely to approach the pulp closely where not apparently very deep, and especial care must be exercised, a matter that has been emphasized.

Proximal cavities in the incisor teeth may occur as early as the eighth year in children of very susceptible families, but it is seldom that we detect them so early. When they do occur, they are difficult of management, mainly on account of the tender age of the patient and the comparatively long period of sharp susceptibility which generally must follow. Often the crowns of the

teeth are still as much as one-third covered with gum tissue, making the adjustment of the rubber dam especially difficult and painful. No kind of filling, temporary or permanent, can be properly done without it. When the rubber dam can be held on the teeth by the contact points aided by bits of cotton, gutta-percha or cement, the difficulty of forcing the rubber dam down by ligatures will be averted. In these cases it is especially desirable to use a quick-setting cement, and, while holding the rubber well down on the lingual and labial, stick a globule on the tooth and hold it until it stiffens enough to hold the dam in place.

The requirement is that cavities be cut very wide toward the labio-gingival and linguo-gingival angles of the proximal surface so as to include the whole area of liability, or that extension for prevention be carried to its full limit and the prepared cavity solidly filled with gold. By this it is not meant that the cavity shall be cut over onto the labial surface so as to show much gold, but only so far toward the angle of the tooth as to relieve the margin of the filling from near contact with the proximating tooth. Extension for prevention does not call for the cutting of proximal cavities of incisors over onto the labial surface in any case, and this should never be done except when demanded by the extension of actual decay of the dentin and backward decay of the enamel. Whenever the condition of the patient as to courage and endurance will warrant this procedure, it should be done without hesitation or delay. Clinical results mark this course as being at once safe and reliable and so markedly the best as to speak most positively against the opinion so often expressed against using metallic fillings in the teeth of young children. The reason that these so commonly fail is that they are so commonly not well done; the extension for prevention is not carried out, nor is the filling well placed, the reasons being mainly that the difficulties are not overcome. Such operating is useless under these conditions and had better not be attempted. In any case of this nature, in which the operator can not see his way to carry out extension for prevention to the full limit and make a perfect filling, he will do better to fill temporarily with gutta-percha, or Hill's stopping, after making the best excavation the conditions will allow at the time and await better conditions. The temporary fillings must be carefully watched, and redone frequently, the patient encouraged in every way, and, at the first opportunity for successful work, the permanent fillings should be made.

In excavating, it should be especially remembered that at this time the pulp of the tooth is much larger than in the adult,

and the danger of its exposure correspondingly greater. Also that the roots of the teeth are still incomplete, making the removal of the pulp and root filling out of the question. The pulp of the tooth must be saved alive or the tooth will be lost. These considerations call for the most extreme care in every detail. Broad cavities are no bar to successful treatment. The pulps of these teeth are in less danger from thermal sensitiveness and hyperemia than in adult teeth. Depth of decay is most to be feared. The wide-open apical foramen gives less danger from strangulation of the blood vessels, and the pulps possess a greater power of recuperation. When exposed, they give a much larger percentage of success in capping. The further growth of dentin which is still fairly active on the wall of the pulp chamber soon covers over such an exposure with dentin — if capping is successful — making the cure complete and permanent. Still, it will be the general rule even with these, that pulps once fully exposed by decay will be lost. The rule that the courage and endurance of the child should not be broken down by any effort at conservative treatment holds in these cases, as in all others, notwithstanding the importance of the teeth under consideration.

Proximal surface decays, if lateral incisors, occur less frequently than similar decays in the central incisors at so early an age as eight or nine years. But cavities in these this early, or correspondingly soon after their eruption when they are late in their development, often present greater difficulty because of the smallness of the teeth. The fact that they frequently overlap the central incisors labially often causes broad cavities to occur in their mesial surfaces. It is depth of decay, however, that is most to be feared. In the management of very early decays in these teeth, it is especially important that the history as to the time of their eruption, as compared with the centrals, should be learned. The pulps of these teeth are very large as compared with the size of the teeth soon after eruption, but grow smaller quite rapidly. One or two years makes considerable difference as to the danger of pulp exposure in cutting to a given depth, and this is the important consideration in these early decays. The irregularity in the time of the development of the lateral incisors gives an uncertainty to their treatment that does not attach to the centrals, and greater caution is necessary.

Fortunately, not very many cases are met with in which any of the incisors are found decayed in persons so young as eight or nine years. But a few will be presented in every considerable practice, scattering along from eight to fourteen. All of these

must be regarded as children and treated accordingly. But the greater number of these cavities will be found in persons from fifteen to eighteen years old. These patients will have more self-control. The teeth are through the gums sufficiently so that the rubber dam and the separator can be applied without unusual pain and the conditions for operating are in every way improved. There are not often found in the general conditions sufficient reasons for temporary treatment. At this age, the patient will generally not have contracted mincing habits of mastication, unless caused by the interference of neglected decay of the deciduous teeth, and malleting will be reasonably well borne. It should be remembered, however, that our civilized habits of using the knife and fork for dividing our food and passing it into the mouth, robs our front teeth of their legitimate function of dividing the food to such a degree that their peridental membranes are not proportionately as strong as those of the back teeth. Also that the direction of force required in condensing gold is generally more or less across the axial line of the tooth, and not so well borne for that reason. Greater care is therefore necessary in the use of force. Still, most of these teeth will readily bear the full fifteen pounds mallet pressure required in condensing the gold, when necessary, if carefully applied from the beginning.

Open apical ends of root canals of the teeth during the childhood period is always a special menace in these operations, because root fillings can not be made in cases in which pulps are found exposed or are exposed by any accident in operating. This should be ever present in the mind of the dentist who attends to the teeth of children. It is as much his duty to use his influence in obtaining the opportunity of watching these children in order that he may do the required operations in good time, as it is to do the operations well. It is not always an easy matter to convince parents that everything possible has been done when they bring in the child with a widely exposed pulp at eight or nine years old and are told that the tooth will probably be lost in spite of all the dentist can do. A few months earlier a safe operation could have been made had the opportunity been given. This education is best and its effect is better when given by the dentist in his office directly to the parents. The pulps are being removed from these teeth and root fillings made much earlier than they should be in hundreds of cases, with the result that abscesses occur under conditions at the root apices which make them incurable. This happens oftener with the upper lateral incisor than

with the central. It is not very uncommon for the upper lateral incisors to be one or two years late in their development. They are often much later than any other teeth, except the third molars, and are in correspondingly greater danger. Usually when these teeth are much late in coming into place in the arch — one or two years later than the central incisors — they will be correspondingly late in the completion of the growth of the roots. In the great surgical clinic of Northwestern University Dental School, it has been particularly noted that a majority of the cases of alveolar abscess, or caries of bone, occurring in the upper jaw, arise from the lateral incisors.

THE PULPS IN THE LATERAL INCISORS ARE LARGE compared with the size of the teeth during the childhood period and for some time later. Therefore, they are oftener exposed by decay occurring soon after their eruption, and by accident in operating, than other teeth. For these reasons proportionately more of these teeth require root fillings early than other teeth. Because of their frequent later development, frequent irregular forms of their roots and also the frequent malposition to the labial, root fillings in these teeth are more difficult and are much more frequently made before the apical foramina have been narrowed down to small openings. For these reasons taken together, root fillings are more often imperfect in these than in the other front teeth. These are sufficient reasons for more frequent alveolar abscesses and their sequellæ. Their prominent position causes them to be retained, notwithstanding these adverse conditions.

There is now an unfortunate tendency among dentists to remove the pulps of teeth for very slight causes. This has been brought about, apparently, by the freedom with which healthy pulps are removed from teeth for the purpose of forming abutments for bridges. Much of this is necessary, but much of it is bad practice, and especially the effect of it is bad for the reason that it leads men to place much too low an estimate on the value of the dental pulp. Too many pulps are destroyed when other means would in the long run be better, and especially for young people. The value of a dental pulp should always be reckoned in inverse ratio to the age of the patient up to the age of twenty-five years. During the childhood period of the permanent teeth, the value of the pulp is equal to the value of the tooth. That is to say, if the pulp is lost before the apical foramen is well narrowed, the tooth will be lost. Of those root fillings made for patients between fifteen and sixteen years old which have proven successful for three months, more abscesses will occur later than

among those in which root fillings are made for patients between sixteen and seventeen. More of these latter will abscess than of those filled between seventeen and eighteen. This will continue progressively to patients who are about twenty-five or twenty-seven years old. Those root fillings made between the ages of twenty-five to twenty-seven, and forty years will give the longest average of service. After that age, there begins to be more frequent interference with successful root filling in the way of calcifications, extreme narrowing of root canals, etc., that renders the average endurance less certain. A strict account of root filling with its results in the endurance of the teeth without abscess will give results closely along these lines. Particularly the great loss of teeth from abscess when root fillings are made before persons are twenty years old, should warn us strongly to use every reasonable effort to avoid destroying pulps for young people. We must destroy pulps and make root fillings in the incisor teeth, as the least of two evils, when there is no hope of saving exposed pulps alive. The reduction of these cases of necessity can come only through greater care in gaining the opportunity to attend more closely to the care of the teeth of our people and make necessary operations earlier in the progress of caries. This means a better education of our people to the necessities of greater watchfulness over the teeth of the young.

GLOSSARY OF TECHNICAL TERMS AND PHRASES, WITH NOTES.

ABSCESS. A cavity containing pus.

ABSCESS, ALVEOLAR. See Alveolar Abscess.

ABSCESS, LATERAL. See Lateral Abscess.

ABSORB. To suck up, to take in, to remove by an absorbent.

ABSORBENT. An agent that takes up moisture. A specially prepared cotton — absorbent cotton, spunk, or bibulous paper, for drying cavities in teeth.

ABSORPTION. The act of sucking in; removal by sucking in, or taking up. The process by which the roots of the deciduous teeth are removed. The process by which the alveolar process is removed after the extraction of teeth, etc. Absorptions play an important part in the processes of life, animal and vegetable.

ACCRETION. Addition by growth, or by deposit, little by little; may be either amorphous, i. e., leaving no lines showing the form of growth; or stratified, showing lines of increase. The enamel of the teeth when reduced to microscopic sections in certain directions shows accretion lines or layers of added material. See Lines of Accretion.

ACCRETION LINES. See Lines of Accretion.

ADHESION. The union of substances that differ in their nature, as: adhesion of glue to wood, paste to paper, etc. To unite bodies by their surfaces.

AFTER CONDENSATION. Such condensation of the surface of a filling as may be made after the filling has been otherwise completed.

ALVEOLAR ABSCESS. An abscess located in the apical space, or within the tissue of the peridental membrane immediately surrounding the apex of the root of a tooth. Alveolar abscess is a distinct form of abscess occurring only after the death of the pulp of the tooth, and is a result of infection through the apical foramen. This should be distinguished sharply from lateral alveolar abscess which occurs on the side of the root, not involving the apical space and in which the pulp of the tooth may be alive.

ALVEOLAR PROCESS. The projection of the maxillary bones which envelops the roots of the teeth, and in which their alveoli are formed.

ALVEOLUS. (Pl. Alveoli). A socket: The cavity in the process of the maxillary bone in which the root of a tooth is fixed.

AMALGAM. A metal, a mixture, or an alloy of two or more metals, commuted and made into a mass by rubbing with, and in this manner, combining with mercury.

AMORPHOUS. A, without; morphous, form. A substance which has no form elements, or apparently has no form elements. A substance that is apparently amorphous to the naked eye may show form elements under the microscope.

ANCHORAGE. The points of fixation of fillings or artificial crowns or bridges.

ANESTHETIC. A drug capable of producing insensibility to pain.

ANGLE. The line, or point, where two or more surfaces of the teeth or walls of cavities join. The mesial and buccal surfaces join in the formation of the mesio-buccal angle; a line angle. The mesial, buccal and occlusal surfaces join in the

formation of the mesio-bucco-occlusal angle; a point angle. The so-called angles of the teeth are generally smoothly rounded but are named as if they were definite angles.

NOTE: The compound words formed from the adjectives ending in *al*, as buccal, labial, lingual, mesial, distal, gingival, axial, pulpal, occlusal, incisal, proximal, have in recent years assumed large proportions in usage in dental nomenclature because of their convenience in the accurate designation of angles of the teeth, margins and angles of surfaces of teeth, of naming complex cavities, cavity walls, cavity angles, directions on surfaces of teeth, etc., also in the adverbial forms ending in *ly*; as mesially, distally, etc., in compounds or in the simple forms, for indicating directions on, or in the teeth, or any directions in the mouth. In the use of these, hundreds of combinations have been employed, any of which can be used without confusion if used intelligently. This only requires care as to confusing with each other angles of teeth, angles of surfaces of teeth, angles of cavities in teeth and other similar things. At present there seems to be no need for the use of very many of these compound forms, but it is by no means certain that the time has come for forming rules for the limitation of their use. Something more than two-thirds of them are repetitions of the same meaning by changing the form of the compound, as: mesio-buccal and bucco-mesial angle of a tooth; such changes in the relation of the words give no change whatever in the angles named. Again, in naming the point angles of cavities, axio-mesio-gingival angle may also be written: axio-gingivo-mesial, mesio-axio-gingival, mesio-gingivo-axial, gingivo-mesio-axial or gingivo-axio-mesial. These varying forms each mean the same thing precisely and any one of them expresses the thought as perfectly as any other. The use of any one of them instead of any other one gives rise to no confusion whatever. A few very simple rules would cut off nearly all of this class of multiplication of compound forms. But I have always felt that this would place an additional tax on the student in learning the use of compound terms. I have, therefore, waited for custom, or ideas of euphony, to suggest a method of doing this. This book has been written without any effort in this direction. The rules in my mind may, however, be suggested here, but are given only as suggestions.

1. Whenever axial occurs, it should be placed first in the compound.
2. Wherever pulpal occurs in the absence of axial, it should be placed first.
3. Wherever mesial or distal occurs in the absence of axial or pulpal, the one occurring should come first in the compound.
4. Wherever the three-syllable words, gingival or occlusal, occur, they should be placed last.

As simple as these rules are, they would be a considerable tax on the student in the beginning of his use of compound terms, but there is no doubt but that with this restriction, the use of these terms would finally become easier.

Until recently I had supposed that the use of the adverbs of direction had been suggested first in dentistry, but it now seems that the botanists have the priority. The use made of them in botany is not essentially different. The adverbs of direction may be used freely as single words or in compound forms in which the last word only takes the *ly*, as mesio-distally; from mesial to distal, or mesio-lingually; a diagonal direction from mesial to lingual across or through a tooth, etc.

Generally but few of these compound words are used in any one cavity description, and they are in no way burdensome after one becomes accustomed to their use. They are the only terms in which cavities can be sufficiently described, or in which cavity preparation can be efficiently taught. There is often a tendency to the multiplication of these terms noticed among students by naming unessential parts of cavities, such as naming individually every cavo-surface line and point angle of a cavity; as bucco-occlusal cavo-surface angle, bucco-mesial cavo-surface angle, bucco-mesio-occlusal cavo-surface angle, etc. This is well enough as an exercise, but is a waste of energy in any essential cavity description. There has been no effort to include all of these compound terms in this glossary; only a few of the most essential are given.

ANGLES OF CAVITIES; RULES FOR NAMING. See Rules for Naming Angles of Cavities.

ANGLES OF SHANKS OF INSTRUMENTS. Named according to number and direction of angles, as monangle, binangle, triple-angle, contra-angle, etc.

ANGLES OF SURFACES OF TEETH. Each surface of a tooth has four angles. The angles of the occlusal surfaces of the bicuspids and molars are, the mesio-buccal, disto-buccal, mesio-lingual and the disto-lingual. The angles of the buccal and lingual surfaces are, the mesio-occlusal, disto-occlusal, mesio-gingival and disto-gingival. The angles of the mesial and distal surfaces are, the bucco-occlusal, linguo-occlusal, bucco-gingival and linguo-gingival. The angles of the labial and lingual surfaces of the incisors are, the mesio-incisal, disto-incisal, mesio-gingival and disto-gingival.

On account of the triangular form of mesial and distal surfaces of the incisors, these have but three angles; the labio-gingival, linguo-gingival and incisal angle. The incisal angle named here is an exception to the rules in that it is named in a single term. It is formed by the junction of the labial and lingual surfaces at the incisal edge. See Angles of Teeth, and note carefully the difference between angles of teeth and angles of surfaces of teeth.

ANGLES OF TEETH. The angles of the teeth are named as if the teeth were cubes, no matter how irregular or how much the angles may be rounded. In naming the angles of the teeth, compounds of the names of the surfaces are used. There are three sets of angles named. The first set is formed by the junction of the

axial surfaces with each other. These form line angles which reach from the occlusal surface to the gingival line. They are the mesio-buccal, disto-buccal, mesio-lingual and disto-lingual angles. The second set are also line angles, and are formed by the junction of the axial surfaces with the occlusal surface. They are the mesio-occlusal, bucco-occlusal, disto-occlusal and linguo-occlusal angles. The third set are point angles, formed by the junction of three walls at a point. They are the mesio-bucco-occlusal, mesio-linguo-occlusal, disto-bucco-occlusal and disto-linguo-occlusal.

The angles of the incisors and cuspids are: First set, mesio-labial, disto-labial, mesio-lingual and disto-lingual angles. The incisal edge of the incisors and cuspids has normally neither the second nor third set of angles complete in such form as to require names, except the mesio-incisal and disto-incisal angles. See Angles of Surfaces of Teeth.

ANNEAL. To soften by heat as in annealing a metal plate, gold, silver, etc. To clean by evaporation of condensed gases or salts on gold foil or crystal gold, for the development of the welding property. To change the mutual relation of an alloy for amalgam and the mercury with which it is to be combined. Aging the alloy, so called.

ANTISEPTIC. A substance or remedy which opposes the development of septic conditions; that opposes, delays, hinders or prevents those decompositions in which poisonous, septic, or disease-producing compounds are formed; such as the putrefactions, fermentations, etc.

In medicine, an agent or remedy for local or internal use which opposes, delays, hinders or prevents the development of, or the systemic effects from the absorption of, toxic compounds formed by those decompositions occurring in suppurating wounds, abscesses, ulcers, or similar conditions. See note on antiseptic, disinfectant and germicide.

NOTE: Antiseptic, Disinfectant, Germicide.

The words antiseptic and disinfectant were in general use before the relation of microörganisms to the decompositions and to disease, as now understood, was discovered. Though the old form of definition is generally retained in dictionaries, the idea of the meaning of the terms was different from that of the present time. An antiseptic restrains the activity of microörganisms and gives local parts time to recover and, by the vital powers of the tissues, to further restrain, or overcome their growth in the tissues on the one hand, or serves to ameliorate the effects of septic poisons already produced and absorbed into the circulation on the other. After this idea an antiseptic is a remedy of local or of systemic usefulness. To be useful locally, it must be decisively more poisonous to microörganisms than to animal tissues, a property exhibited in greatest degree by mild solutions of carbolic acid, "1-2-3," and mercuric bichlorid. For general systemic use, alcohol and cinchona are examples.

In the original use of the word disinfectant, the agent so named was supposed to destroy the noxious products of decomposition, to render them non-poisonous, or to destroy or remove foul odors or emanations from decomposing material. With increasing knowledge of the relation of microorganisms to the decompositions and to the formation of foul odors and of disease-producing poisons, or toxins, so called, the idea expressed by the word disinfectant has become changed to that of the removal or destruction of the actual microörganisms, plasmocites, etc., which constitute the virus of disease and are responsible for the decompositions and the formation of the noxious compounds. This may be done by any means at hand, as by washing them away from the hands or from instruments by soap and water with the brush, destroying them by heat or by use of chemical agents, such as germicides.

The word germicide is a later development and means an agent that actually destroys the life of microörganisms, plasmocites, etc., which constitute the actual virus of infectious diseases. All germicides are poisons. It is only when in attenuated solutions they are more poisonous to microorganisms than to the animal tissues or cells that they may be used as antiseptics. Inanimate substances, such as instruments, clothing, bedding, rooms, etc., may properly be disinfected with germicides when the chemical relations of the substances to each other are such that material injury to the articles disinfected will not occur. When sufficient heat can be used, it is usually the best and safest disinfectant. For certain purposes, gaseous germicides, such as sulphurous acid obtained by burning sulphur, or formalin may be employed. These are readily removed by the free admission of air after they have done their work in the disinfection of rooms, clothing, bedding, etc.

According to this view, an antiseptic is a medicinal agent which may be of use in topical applications or as an internal remedy. Disinfectants and germicides are extra medical, and are chemical, mechanical, or physical agents. There are, however, some special conditions in which it is wise to use a germicide on living tissues. As, for instance, if a person has broken the skin on the hand or a finger while handling a cadaver, or dangerous surgical material, it is much better to destroy at once the possible infectious material, together with a limited amount of tissue, as may be done with 95 per cent carbolic acid or with concentrated formalin, rather than run the risk of grave disease. Within such limits only can disinfectants or germicides be used as medicines.

APEX. The terminal end of a cone; a conical end. The terminal end of a root of a tooth.

APICAL. Pertaining to the apex or conical endings of the roots of teeth.

APICAL FORAMEN. The minute opening of the pulp canal at the apex of the root of a tooth.

APICAL SPACE. The space between the bone, or wall of the alveolus, and the apex of the root of a tooth. This space is filled with the soft tissues of the peridental membrane, and is the seat of alveolar abscess.

APPROXIMATE. Next to, nearest to. To draw near to. Occasionally employed to designate the distal or mesial surface of a tooth. See Proximal.

ARCH. An arc or portion of a circle. Any object in nature or art which is curved, like an arc. The dental arch, the arrangement of the teeth in a bow shape or arc.

ASEPTIC. The condition of freedom from sepsis or freedom from microörganisms which might possibly produce a condition of sepsis.

ASEPTIC OPERATING. To make the conditions such as to prevent the entrance of microörganisms during an operation.

ASEPTIC WOUND. A wound not infected with microörganisms.

ASPHYXIA. Suspended animation from suffocation.

ATROPHY. "Latin, Atrophia, without nourishment. A, without; trophia, nourishment."—Webster.

A result of defect of, or a failure of, nutrition of a part which limits its formation. A diminution of the size of a part, or a wasting due to defective nutrition. Of the teeth: a failure in the formation of certain parts of the enamel and dentin because of a failure of nutrition at the time those particular parts should have been formed. This results in a dwarfing of certain parts of the tooth and causes it to be malformed.

A wasting of certain parts or organs of the body because of disease affecting the trophic nerves. Under conditions on non-use of muscles from disease or accident they waste away from lack of nutrition. The term atrophy is applied to many conditions characterized by wasting of parts due to disease of the trophic nerves supplying the part and consequent failure of nutrition. Syn. Hypoplasia.

ATROPHY MARKS. The peculiar marks left on the teeth by reason of a failure of nutrition during their development.

AXIAL. Pertaining to the long axis of a tooth. See Axial Surface.

AXIAL ANGLES OF TEETH. The line angles that are parallel with the long axes of the teeth are called axial angles. They are the mesio-buccal and mesio-labial, disto-buccal and disto-labial, mesio-lingual and disto-lingual angles.

AXIAL CAVITIES. Cavities beginning in any of the axial surfaces of the teeth; as the mesial, buccal or labial, distal and lingual surfaces.

AXIAL SURFACES. Those surfaces of the teeth that are parallel with their long axes. They are labial or buccal, lingual, mesial and distal surfaces.

AXIAL WALL of cavities. A cavity wall that is parallel with the long axis of a tooth and covers the pulp chamber, is called the axial wall.

AXIAL WALLS of pulp chambers. Those walls that are parallel with the long axes of the teeth; the mesial, distal, buccal and lingual walls.

AXIO-BUCCO-LINGUAL PLANE. A plane passing through any part of a tooth from buccal to lingual parallel with its long axis. See Figure 11, Vol. 2.

AXIO-LABIO-LINGUAL PLANE. A plane passing through any part of an incisor or cuspid tooth from labial to lingual parallel with its long axis.

AXIO-MESIO-DISTAL PLANE. A plane passing through any part of a tooth mesio-distally parallel with its long axis. See also Mesio-distal Plane. See Figure 10, Vol. 2.

BACILLUS. (Pl. Bacilli.) A rod-shaped bacterium.

BACTERIA. A class of microscopic fungi destitute of chlorophyl. They follow more or less closely four forms: (1) the sphere, (2) the rod, (3) the spirilla, (4)

the thread forms. They are closely associated with the fermentations, putrefactions and other decompositions. They incite a number of special diseases in man.

BELL CROWNED. A tooth in which the mesio-distal diameter of the crown is much greater than that of the neck.

BEVEL. To cut a bevel angle; to slope the edge or surface of. To deviate or incline from an angle of 90 degrees, as a surface; to slant. (Webster.) To slope the outer edge of the surface of the enamel wall of a cavity. See Figure 103, A, Vol. 2. To grind the flat side of the blade of an instrument at an inclination to form a cutting edge.

BIBEVELED. Having a bevel on two sides of a blade. Bibeveled to a point, as in drills, for cutting while being rotated.

BIBULOUS PAPER. A specially prepared paper used as an absorbent for drying cavities in teeth.

BICUSPID. A tooth with two cusps. There are eight bicuspids; two on each side of the upper jaw, and two on each side of the lower jaw. They are named right and left upper first and second, and right and left lower first and second bicuspids. They are situated between the cuspids and molars. In the nomenclature of comparative dental anatomy the bicuspids are called premolars.

BITE. See The Bite.

BOLEY GAUGE. So named after the person who designed it. Originally a watchmaker's gauge. It has been found an especially convenient instrument for the dentist to use for all kinds of delicate measurements. It is in the metric system.

BONE CORPUSCLES. The soft cells that persist in bone after calcification.

BORDER OF THE ALVEOLAR PROCESS. The thin edge of the alveolar process surrounding the necks of the teeth.

BROACH. A delicate flexible steel instrument for cleaning pulp canals in teeth. There are several varieties; the barbed broach, smooth broach, spiral broach, etc.

BUCCAL. Pertaining to the cheek; toward the cheek; next to the cheek, etc.

BUCCAL CAVITIES. Cavities formed by decay beginning in the buccal surfaces of the teeth. They include buccal pit cavities and smooth surface, or gingival third buccal cavities.

BUCCAL SURFACE. The surface of a tooth next to the cheek.

BUCCO-GINGIVAL RIDGE. A prominent ridge near the gingival line on the buccal surface of the deciduous molars. It is especially prominent on the deciduous first molars.

BUCCO-LINGUAL. From the cheek toward the tongue; as the bucco-lingual diameter of the crown of a lower first molar.

BUCCO-LINGUALLY. A direction from the buccal toward the lingual.

BUCCO-LINGUAL PLANE. A contraction of axio-bucco-lingual plane.

CALCIFIC. Containing salts of calcium.

CALCIFICATION. The act of depositing calcific matter or calcium salts during growth. The bones and teeth become calcified. Also pathological calcifications occur in several parts of the body.

CALCIFICATION LINES OF RITZEUS. The accretion lines in the enamel were first described by Ritzeus. See Lines of Accretion.

CALCULUS. The calcium salts of the oral secretions deposited upon the exposed parts of the teeth and parts of roots denuded of their membranes; as, salivary

calculus and serumal calculus. A common medical term for stone, as "gall stone," renal calculus, etc.

CANAL. See Root Canal.

CARIES. Latin, caries. Only one form of the noun is used in English; it has no plural. The word was imperfect in its inflections in the Latin.

Rottenness, moldiness, decay, as of wood or timber. Anthon.

(*Med.*) Ulceration of bone; a process in which bone disintegrates and is carried away piecemeal, as distinguished from necrosis in which it dies in masses. Webster.

In dentistry: Decay of the teeth, in which cavities are formed in them by gradual decomposition. The only change of the form in the use of the word in English is the adjective carious, as a carious tooth. See Decay.

CARIOUS. A condition of tissue like enamel or dentin, or, of a tooth, affected with dental caries. In medicine it refers to a condition of suppurative disintegration of bone.

CATAPHORESIS. Introduction of medicine into the tissues through the unbroken skin, or the tubuli of the dentin of a tooth, by means of an electric current.

CAVITIES, BUCCAL. See Buccal Cavities.

CAVITIES, LINGUAL. See Lingual Cavities.

CAVITIES, OCCLUSAL. See Occlusal Cavities.

CAVITIES, PIT. See Pit Cavities.

CAVITIES, PROXIMAL. See Proximal Cavities.

CAVITIES, RULES FOR NAMING. See Rules for Naming Cavities.

CAVITIES, RULES FOR NAMING ANGLES OF. See Rules for Naming Angles of Cavities.

CAVITIES, SMOOTH-SURFACE. See Smooth-surface Cavities.

CAVITY. An opening in any substance which has but one outlet or is entirely closed. Any opening into a tooth formed by caries or artificially made.

CAVITY, COMPLEX. A cavity involving two or more surfaces of a tooth, as a disto-occlusal cavity.

CAVITY NOMENCLATURE. In dentistry, a system of nomenclature applied to cavities in teeth. Under this term is included all of the names of cavities, names of cavity walls, of angles of cavities and the terms of cavity description, together with the rules of their use.

CAVITY PREPARATION. Those operations necessary in forming cavities in teeth for the reception of fillings.

CAVITY WALLS, rules for naming. See Rules for Naming Cavity Walls.

CAVO-SURFACE ANGLE. The angle formed by the junction of the cavity wall and the surface of the tooth. Used particularly in indicating the form to be given this angle by beveling or otherwise, in any particular part of the line of the enamel margin. See Figure 8, C S, Vol. 2.

CEMENT. *n.* An adhesive filling material, like oxyphosphate, oxychlorid of zinc, etc.

CEMENT. *v.* To fasten by an adhesive substance. An inlay or cast filling is cemented in place.

CEMENTUM. A special calcified tissue which covers the roots of the teeth. It has lacunæ and canaliculi, but differs from bone in having no Haversian canals.

CENTIGRADE. One hundredth part of a circle. An angle of twenty-five centigrades is a right angle and equals ninety degrees of the astronomical circle, or eight points of the mariner's circle. One centigrade equals three and six tenths (3.6) degrees.

CERVICAL. *a.* Pertaining to the cervix or neck. Used formerly in a sense somewhat similar to that in which gingival is now used. See Gingival.

CERVIX. *n.* Neck. The portion of the crown of the tooth near its junction with the root has been called the cervix, or neck.

CHILDHOOD PERIOD. In dentistry this is reckoned from the first appearance of teeth until the roots of all of the permanent teeth, except the third molars, have been completely formed. It is only after that time that the teeth can be treated in all respects as the teeth of the adult. This is usually about the fifteenth or sixteenth year.

CHILDHOOD PERIOD OF THE PERMANENT TEETH. The period from the first appearance of the permanent teeth until their roots are fully completed, except the third molars. See Figure 187, Vol. 1.

CHITIN. The hard shell-like covering of insects.

CHITINOID. Chitin-like; resembling the hard covering of insects.

CHITINOUS. Consisting of or resembling the hard covering of insects.

CLAMP FORCEPS. A special forceps for placing the rubber dam clamp.

CLAMP, RUBBER DAM. An instrument made to set on teeth over the rubber dam to hold it in place, or over which the rubber dam may be thrown. It is made of spring steel, and, in applying it, it is opened with a special forceps, placed in position and allowed to close on the tooth with the force of its spring.

CLASSIFICATION OF CAVITIES INTO ARTIFICIAL GROUPS. In a classification of cavities, it is the intention to group together in classes cavities of decay that require a similar line of treatment, in order that these may be more closely associated.

Class 1. Cavities beginning in structural defects in the teeth; pits and fissures. These are located in the occlusal surfaces of the bicuspids and molars, in the occlusal two-thirds of the buccal surfaces of the molars, in the lingual surfaces of the upper incisors, and occasionally in the lingual surfaces of the upper molars.

Class 2. Cavities in the proximal surfaces of the bicuspids and molars.

Class 3. Cavities in the proximal surfaces of the incisors and cuspids which do not involve the removal and restoration of the incisal angle.

Class 4. Cavities in the proximal surfaces of the incisors which do require the removal and restoration of the incisal angle.

Class 5. Cavities in the gingival third — not pit cavities — of the labial, buccal or lingual surfaces of the teeth.

Classes 2, 3, 4 and 5 are all smooth-surface cavities. They all occur in positions in which the surfaces of the teeth are habitually unclean.

CLASS NAME, of an instrument. A name applied to a definite class of cutting instruments describing the form of blade; as hatchet, hoe, spoon, etc.

CLEAVAGE. The line of easy splitting of crystalline or stratified substances. To split along the length of the grain; as in splitting wood. The act of splitting the enamel in a certain direction following the length of the enamel rods which form its cleavage lines.

CLEAVE. To split.

CLEOID. (From cle, old Saxon for claw, and oid, like.) A claw-like instrument used in excavating cavities.

CLOT. *n.* A soft, semi-solidified mass, as of blood or lymph.

COAGULATE. *v.* To form a coagulum or clot.

COAGULATION. The process of forming a clot or coagulum.

COAGULUM. *n.* A clot. A soft semi-solidified mass, as of blood or lymph.

COCCUS. (Pl. Cocci.) A spherical or nearly spherical bacterium.

COHESION. The act or state of sticking together; close union. That form of attraction by which the particles of a body are united throughout the mass, particle to particle. This must be distinguished from adhesion, which unites bodies by their surfaces only. It is only bodies that have a common property, as simple elements, compounds or alloys formed of them, that cohere.

COHESIVE. A property of annealed gold (foil or crystal) which causes separate particles to stick to one another, as they are welded, when placed in contact by heavy hand or mallet pressure.

COHESIVE GOLD. Gold in the form of foil or crystals, the surfaces of which are clean and free from condensed gases or salts so that they may be brought into actual contact. Gold foil or crystals in which the welding property is partially or fully developed.

COMPLEX CAVITY. A cavity involving two or more surfaces of a tooth, as a disto-occlusal cavity.

CONTACT POINT. The point on the proximal surface of a tooth which touches a neighboring tooth.

CONTEMPORANEOUS CALCIFICATION LINES. The portions of the several teeth which are undergoing calcification at the same time. A representation of the portions of the several teeth undergoing calcification at the same time by drawing lines over pictures or diagrams of the teeth.

CONTOUR. *n.* The line bounding a figure or body, as the contour of a tooth.

CONTOUR. *v.* To make a contour or outline of. To restore the original outline of a carious tooth by filling.

CONTRA-ANGLE. Angles formed in the shank of an instrument, first backward from the direction of the cutting edge and then forward to form the blade in order that the working edge may be placed near the long axis of the handle. There are binangle and triple-angle contra-angles.

CONTRA-ANGLE HAND-PIECE, for the dental engine. A hand-piece with a contra-angle to enable one to reach positions difficult or impossible with a straight hand-piece. See Figure 25, Vol. 2.

CONVENIENCE FORM. In cavity preparation: Such special form as may be given to special points of the internal parts of cavities as will render the placing of the filling more convenient.

CONVENIENCE POINT. A small depression or undercut to make the starting of a filling more convenient. See Figures 170-173, Vol. 2.

CROWN. That portion of a tooth which is covered with enamel, and which projects from the tissues in which the root is fixed.

CULTURE MEDIA. (Pl.) Substances used to grow microörganisms upon, or in. They may be fluid or semi-solid.

CURLED ENAMEL. Enamel in which the enamel rods are much crooked and curled or intertwined with each other. See Figure 147, Vol. 1.

CUSP. A pronounced elevation, or point, on the surface of a tooth, more especially on the occlusal surface.

CUSPID. A tooth with one point, or cusp. There are four cuspids: one on

either side in each jaw, situated at the angles of the mouth. In the nomenclature of comparative dental anatomy these are called canine teeth.

CUTTING EDGE. The edge formed by the junction of the labial and lingual surfaces of the incisor and cuspid teeth. In the cuspids, the edge is raised to a point near its center. The edge of excavators, such as hatchets, hoes, etc.; or of other cutting instruments.

DECAY. Latin, Cadere, to fall. To decline, to fall, to become less; to pass gradually from a sound, prosperous or perfect state to one of imperfection, adversity or dissolution. To waste away, to decline, to fall, to become weak, corrupt or disintegrated; to rot; to perish; as, a tree decays; fortunes decay; hopes decay.—Webster.

Any wasting, disintegration, softening or deterioration by decomposition. Decay of the teeth is widely used as synonymous with caries of the teeth.

DECIDUOUS. That which will be shed. Deciduous teeth are those that are shed at periodical stages of growth of the person or animal. Applied to the teeth of childhood. They are also called temporary teeth.

DEFORMED. Out of the normal or correct form.

DEFORMITY. Misbuilding of any organ or part by which it is imperfectly formed; out of correct form.

DENTAL. Pertaining to the teeth.

DENTAL CARIES. A local disease of the teeth, in which the enamel is dissolved by the action of lactic acid as a waste product of microörganisms and the dentin is disintegrated by the vital activity of acid producing organisms penetrating the dentinal tubules. See Caries.

DENTAL ENGINE. A machine for the use of rotary motion in dental operations.

DENTAL INSTRUMENT GAUGE. An instrument designed especially for the measurement of dental instruments. See Figure 17, Vol. 2.

DENTAL NOMENCLATURE. The particular system of nomenclature used in dentistry. In many respects it is different from the nomenclature of comparative dental anatomy.

DENTIGEROUS. Containing or producing teeth, as a dentigerous cyst or tumor.

DENTIN. The tissue of which the main body of a tooth is formed.

DENTINAL FIBRILS. The living fibers filling the dentinal tubules. See Fibrils of Tomes.

DENTIN WALL. That portion of the wall of a cavity that is composed of dentin. See Figure 8, DW, Vol. 2.

DENTITION, THE. The teeth of the person or animal as a whole. The dentition of the monkey is very similar to that of the man.

DENTO-CEMENTAL JUNCTION. The line of junction of dentin and cementum.

DENTO-ENAMEL JUNCTION. The line of junction of the dentin and enamel. See Figure 8, DE, Vol. 2.

DEVELOPMENTAL GROOVES. Fine depressed lines in the enamel of a tooth which mark the junction of its lobes.

DEVELOPMENTAL LINES. See developmental grooves.

DIAGNOSIS. The art or process of determining the nature, location and causes of a disease.

DIALYZE. To cause soluble salts to pass through an animal membrane to separate them from gummy substances with which they are associated in a solution.

DIALIZER. An apparatus for dializing.

DIALYSIS. The passing of soluble salts through animal membranes to free them from colloid or gummy material with which they are mixed.

DIATHESIS. A particular habit or disposition of body. A certain natural constitution of body, cells and fluids, by which a person is predisposed to certain particular diseases; as the Hemorrhagic diathesis, a tendency toward profuse bleeding from slight cause; Gouty diathesis, a predisposition toward gout, etc.

DIATHETIC. Pertaining to diathesis.

DIFFERENTIAL DIAGNOSIS. The distinguishing between two similar diseases by comparison of their symptoms.

DISINFECTANT. An agent — mechanical, physical, chemical or medicinal — that removes or destroys the virus of infectious or communicable diseases or of pus formation. As a brush, soap and water; a boiling temperature, the germicides, etc. See note on antiseptic, disinfectant and germicide under Antiseptic.

DISK OR DISC. Any flat circular plate. Disks used by dentists are thin, circular pieces of paper, cloth or other substance charged with abrasive powder for cutting or polishing teeth and fillings. They are used in the dental engine.

DISTAL. Away from the median line of the face following the curve of the dental arch. The surfaces of the teeth most distant from the median line are called distal surfaces.

DISTAL ANGLE. A contraction of disto-incisal angle. Used, also, instead of disto-bucco-occlusal angle (q. v.)

DISTAL CAVITIES. Cavities beginning in the distal surfaces of the teeth.

DISTALLY. *adv.* A direction away from the median line of the face following the curve of the dental arch.

DISTO-BUCCAL ANGLE. (a) The angle formed by the junction of the distal and buccal surfaces of the bicuspids and molars. (b) An angle formed by the junction of the distal and buccal walls of a cavity.

DISTO-BUCCO-OCCLUSAL ANGLE. The angle of a bicuspid or molar tooth formed by the junction of its distal, buccal and occlusal surfaces at a point.

DISTO-INCISAL ANGLE. The angle of an incisor or cuspid tooth formed by the junction of the distal surface and cutting edge, or incisal surface. See Incisal surface.

DISTO-LABIAL ANGLE. The angle formed by the union of the distal and labial surfaces of incisors and cuspids.

DISTO-LINGUAL ANGLE. (a) The angle formed by the junction of distal and lingual surfaces of any of the teeth. (b) The angle formed by the junction of the distal and lingual walls of a cavity.

DISTO-LINGUO-OCCLUSAL ANGLE. The angle of a bicuspid or molar tooth formed by the junction of its distal, lingual and occlusal surfaces at a point.

DISTO-OCCLUSAL ANGLE. The angle formed by the junction of the distal and occlusal surfaces of the bicuspids and molars. It forms the distal marginal ridge of the occlusal surfaces of these teeth.

DRILL. A cutting instrument for boring holes. Usually bibeveled, but may be square ended.

DYNAMOMETER. An instrument for the registration of force in its application in mechanics, or in testing the strength of materials. See Figures 164, 165, Vol. 1.

ENAMEL. The tissue covering the dentin of the crown portion of the tooth.

ENAMEL CAP. The covering of the crown of the tooth, composed of enamel.

ENAMEL, CURLED. See Curled enamel.

ENAMEL MARGIN. The junction of a wall of a cavity with the surface of the tooth. It is continuous, forming the outline of the cavity. See Cavo-surface angle, and Outline form.

ENAMEL RODS. The form elements of which the enamel is made up. They are in the form of minute rods of extremely hard calcific material. These are cemented together in a solid mass by an intervening cement substance that leaves no openings. The general course of the enamel rods is from the dento-enamel junction to the surface of the tooth. On all parts the ends of the enamel rods are presented to the surface of the tooth.

ENAMEL RODS, INCLINATION OF. Used in describing either normal or abnormal inclination of the enamel rods from a direction perpendicular to the surface of the tooth. See Inclination.

ENAMEL, STRAIGHT. See Straight enamel.

ENAMEL WALL. That portion of the wall of a cavity which is composed of enamel. See Figure 8, EW, Vol. 2.

ENZYME. Any digestive body, or digestive fluid, such as pepsin, trypsin, ptyalin, pancreatin, etc.

EPULIS. A tumor upon the gum.

EROSION. A defect in a surface of a tooth characterized by a progressive loss of substance, leaving a polished or smooth surface which can not be accounted for by abrasion.

ESTHETIC. Pertaining to the science of esthetics, which treats of the pleasing and beautiful.

ETIOLOGY. The science of the causes of disease. This includes predisposing and exciting causes, remote and near, general and local, hereditary and immediate, or acquired.

EXCAVATING BUR. A moderately coarse cut bur designed for use in the preparation of carious cavities in teeth for filling.

EXCAVATOR. A cutting instrument having a sharp blade, shank, and shaft or handle, for use in the preparation of cavities in teeth for the reception of fillings.

EXTENSION FOR PREVENTION. Extension for the prevention of the recurrence of decay after a filling has been made. This extension is always to be made in the preparation of proximal and gingival third cavities. In each case the extension is toward the axial line angles of the tooth for the reason that the regions of these angles are the least liable to the beginnings of caries of any portion of the circumference of the tooth near the free margins of the gingivæ.

FACET. On the teeth; a worn spot made by the rubbing of the proximal surfaces of adjoining teeth. A slight loss of the substance of the enamel in the beginning of erosion, etc. A facet may also be made by grinding with a fine stone. Facets occur on the occlusal surfaces of the teeth from wear.

FERMENT. A substance which causes chemical and physical changes in fermentable substances with which it comes in contact. Certain soluble ferments, as pepsin, pancreatin, ptyalin, etc., induce an action similar or identical with digestion; but do not induce further changes. The living ferments, microörganisms, carry the process to its ultimate ends by converting the fermentable substances into other chemical compounds.

FERMENTATION. Chemical and physical changes induced by certain microorganisms. A form of decomposition. There are a number of distinct fermentations, as vinous fermentation, lactic fermentation, acetic fermentation, etc.

FESTOON. An enlargement of that part of the interproximal gingivæ occupying the embrasures at the angles of the teeth buccally and lingually, but more commonly only the buccal portion.

FIBRILS, DENTINAL. The fibrils occupying the dentinal canals. See Fibrils of Tomes.

FIBRILS OF TOMES. The prolongations from the odontoblasts which occupy the dentinal canals. They reach from the pulp chamber to the enamel or cementum. See Dentinal fibrils.

FILLING. *n.* The material placed in a cavity in a tooth; the resultant of the act of placing a filling. Syns.: A plug; a stopping.

FILLING. *v.* The act of placing filling materials into a cavity of the tooth or roots of teeth. Syns: Plugging; stopping.

FINGER POSITIONS. The positions of the fingers in performing dental operations. A systematization of the nomenclature of finger positions. See Figures 46-61, inclusive, Vol. 2.

FISSURE. A fault in the surface of a tooth caused by the imperfect joining of the enamel of the different lobes. Fissures occur along the lines of the developmental grooves, and more rarely along the lines of supplemental grooves.

FISSURE BUR. A bur in the form of a solid cylinder with even, straight or parallel surfaces. See Figure 137, Vol. 2.

FISSURE CAVITY. A cavity beginning along the line of a fissure. The terms "pit cavities" and "fissure cavities" are often used.

FISTULA. [L] A reed, or pipe. An abnormal opening from a normal cavity to the surface for the discharge of a normal secretion.

"In pathology, a narrow passage or duct, formed by disease or injury, leading from an abscess to a free surface, or furnishing an abnormal means of egress from some normal cavity, as in vesico-vaginal fistula." Century Dictionary.

"(Medical.) A long, sinuous pipe-like ulcer, with a narrow orifice and without disposition to heal. Hoblyn. Fistulæ have different names according to the discharge which they afford, and the organs in which they are seated, as lachrymal, biliary, salivary, synovial, urinary. Dunglison." Worcester.

"(Medical.) A permanent abnormal opening into the soft parts with a constant discharge; a deep, narrow, chronic abscess; an abnormal opening between an internal cavity and another cavity or on the surface, as, a salivary fistula; an anal fistula, a recto-vaginal fistula." Webster.

"(Pathology.) Any abnormal opening into a natural canal or hollow organ. A long, narrow canal caused by diseased action and not disposed to heal because of morbid conditions." Standard Dictionary.

"An unnatural channel leading from a cutaneous or mucous surface to another free surface or terminating blindly in the substance of an organ or part." Foster's Medical Dictionary.

"An abnormal tube-like passage in the body." Gould.

"A narrow track or canal leading from a free surface, and extending more or less deeply to some seat of local irritation; or it may be constituting an abnormal communication between two or more cavities, as in the case of a vesico-vaginal fistula." Quain.

NOTE: It will be noticed from the above that the word fistula is used with two distinct meanings; one, an abnormal passage for the discharge of a normal secretion from a normal cavity, as a salivary or urinary fistula; the other, an abnormal passage for the discharge of an abnormal secretion (pus) from an abnormal (abscess) cavity. The first of these meanings seems to be the favored one, and in view of the fact that the definition of the word sinus as applied to such a tract, is identical with the second meaning of fistula, it would seem to be very desirable to use the word sinus in speaking of such a tract from which pus is discharged, and the word fistula in speaking of such a tract from which a normal secretion is discharged.

FORMULA NAMES. A system of naming dental instruments based on the measurement of their working parts. See text.

FOSSA. (Pl. Fossæ.) A round, or angular depression in the surface of a tooth.

Fossæ occur mostly in the occlusal surfaces of the molars, and in the lingual surfaces of the incisors.

FUNGOUS. Pertaining to the fungi.

FUNGUS. (Pl. Fungi.) The lowest order of plants. They are destitute of chlorophyl and grow in the dark as well as in the light. Microörganisms belong to this class.

GELATINOID. Gelatin-like. Having the appearance of gelatin. Used in describing masses that have the general appearance of gelatin but which are not of the composition of true gelatin.

GELATINOID PLAQUES. Masses of microörganisms in zoöglea form, or inclosed in a gelatinoid substance and attached to the teeth. See Zoöglea.

GERMICIDE. Any agent that destroys germs, as microörganisms, plasmocites, etc., or the virus of infectious diseases; as the boiling temperature, mercuric bichlorid, formalin, carbolic acid, etc. See note on antiseptic, disinfectant and germicide under Antiseptic.

GINGIVA. (Plural, Gingivæ.) That portion of the gum tissue covering the alveolar process, surrounding the borders of the enamel of the teeth next to the cementum and filling the interproximal spaces. Gums, is often used as the synonym of gingivæ. But gums includes the firm fibrous tissue covering the palatal processes, while gingivæ is restricted to the gum tissue close about the teeth.

NOTE: This word is very generally used in the plural form. It is derived from the Latin: Gigno, genui, genitum, which was probably obtained from the Greek. In varying forms it seems to have maintained a place in the Latin throughout its active use as a spoken language. A large number of English words are derived from the various Latin forms. Latin dictionaries define the original words thus: To beget; to bear; to bring forth; to produce. In the passive form; to be born; to spring; arise; proceed, etc. "Quacumque animal parrient in capita gignunt. Pliny, 10, 64, Bring forth their young head foremost." Harper's Latin-English Dictionary.

The word gingiva, or the plural gingivæ, seems to have had a wide use, and had special reference to that portion of the gums which gave birth to, or produced, teeth; or lay immediately about them, as in this idiomatic expression, "Interdentum et gingivam. Celcus, 6, 13"; literally, between the gums and the teeth; but meaning in a close place. This is akin to "by the skin of his teeth," sometimes heard in English.

The Standard Dictionary — Twentieth Century Edition — gives the plural form only and authorizes the spelling gingivæ instead of gingivæ: The gums; gingival, of or pertaining to the gums. Produced by aid of the gums; as gingival sounds.

The American Illustrated Medical Dictionary, 1902, gives Gingiva, Pl. Gingivæ: The gums; the fleshy structure that covers the alveolar border of the jaw. Gingival, pertaining to the gum or gums.

Gould's Medical Dictionary: "Gingival. Pertaining to the gums. Gingival line. A blue or purplish line along the gums where they meet the teeth, indicative of chronic lead poisoning. Also a reddish line along the gums, sometimes seen in tuberculosis. Gingival margin. The line, or edge of the gums where they meet the teeth; the free edge of the gums."

Dorland's Medical Dictionary gives the definition of gingivæ: "That portion of the gum close about the teeth."

In looking up examples of the use of the word in the Latin, it is found that the plural form was used much more frequently than the singular, and this is true in English. It is the same in the use of gum and gums.

In the French language, the word is gencieve, gum or gums.

Probably if we had an English adjective derived from the word gum, as gumal, we would not have needed the Latin term, but as practically all of the adjectives ending in *al*, used in dental nomenclature, are of Latin origin, such an adjective form of the old Saxon word, gum, would look a bit out of place. An adjective is a necessity.

The word neck, and the Latin equivalent cervix, have had some use in dentistry in which cervical has been the adjective form. This word was used to represent a constriction or a supposed constriction between the crown of the tooth and its root. As used, its meaning was much too vague to serve the purposes of modern dentistry. Cervical is now practically obsolete, but the word neck is occasionally used in a few phrases.

These notes have been written after the book proper was printed, and I find that the use of the word is always with reference to that portion of the gum tissue close about the teeth. The word gum is used as synonymous in many places. In a good many expressions it is preferred. Wherever an adjective form is necessary, however, gingival is the only word used.

Gingival line is always used to represent the normal line of the attachment of the gum tissue to the tooth, and the adjective gingival always refers to that line. This is at the junction of the enamel and cementum. The adverb, gingivally, is always used when the reference is to the crown of a tooth, a direction toward the gingival line. If it is used with reference to the root of a tooth, it is also toward the gingival line.

I have generally, but not always, used "free margin of the gum," instead of free margin of the gingivæ, to represent that portion lapping onto the enamel of the teeth. Gum line, as used, means the line of the extreme edge of the free margin of the gingivæ that laps upon the enamel of the teeth.

The fact that a few authors and a few dictionaries have used "gingival line," to represent the line of dark color on the gingivæ frequently present in lead poisoning, can cause no confusion in the use of these words in dentistry. This can not be said to be in general use in medical literature.

GINGIVAL. Pertaining to the gingival line; as the curvature of the gingival line; gingival margin; gingival wall, etc. Pertaining to that portion of the gums covering the alveolar processes surrounding the borders of the enamel next to the cementum and filling the interproximal spaces.

GINGIVAL CURVATURE. The deviation of the gingival line from the horizontal in its course around the neck of a tooth; especially of the incisors and cuspids.

GINGIVAL LINE. The line around the neck of a tooth at which the gingiva is attached. The line of junction of the enamel and cementum.

GINGIVALLY. A direction from any part of the crown toward the gingival line of a tooth.

GINGIVAL MARGIN. The portion of the crown, or a surface of the crown of a tooth next to the gingival line. The margin of a cavity that is toward or next to the gingival line.

GINGIVAL MARGIN TRIMMERS. Instruments for beveling the cavo-surface angles of the gingival walls of proximal cavities in the bicuspids and molars.

GINGIVITIS. Inflammation of the gingivæ. See Ulitis. While the term gingivitis should be limited to inflammation of the soft tissues immediately about the teeth and covering the borders of the alveolar processes, the term ulitis includes the wider inflammation areas that include the roof of the mouth and other parts.

GLUTINOID. Glutin-like. Any semisolid which resembles glutin, or is glutinous; sticky, adhesive.

GNATHODYNAMOMETER. An instrument for measuring in pounds, kilograms, etc., the force exerted in closing the teeth. See Figures 162, 163, Vol. 1.

GOLD FOIL. Thin sheets of gold prepared for filling teeth. The thickness is expressed in numbers, 1, 2, 3, 4, etc., up to 120. The numbers express the number of grains of gold in a sheet four inches square. Light foils are those below No. 10. The heavy foils are those above No. 10.

GOLD, NON-COHESIVE. Gold in the form of foil or crystals in which the welding property is obscured, usually by the condensation of some gaseous substance upon it, or a film of a salt from the union of two or more gases.

GRASPS, INSTRUMENT. See Instrument grasps.

GRASPS, RUBBER DAM. See Rubber dam grasps.

GROOVE. A long-shaped depression in the surface of a tooth.

GUMS. The harder fleshy covering of the bones of the mouth, particularly of the roof of the mouth and the alveolar processes. See Gingiva.

GUM SEPTUMS. That portion of the gums or gingivæ that occupies the interproximal spaces.

HATCH CLAMP. So called after the person who designed it. A rubber dam clamp of special pattern for use in treating gingival third cavities. It may be used on all teeth except the molars.

HAVERSIAN BONE. Bone composed of Haversian systems.

HAVERSIAN CANAL. *Histology.* A canal which occupies the center of a Haversian system.

HAVERSIAN SYSTEM. *Histology.* A long, cylindrical area in bone, usually placed lengthwise of the long bones, composed of a central canal surrounded by a number of concentric rings or layers of bone corpuscles.

HEMORRHAGE. Escape of blood from the blood vessels. Capillary H., from the capillaries. Venous H., from the veins. Arterial H., from the arteries.

HEMOSTATIC. A medicinal agent that checks or arrests the flow of blood.

HORIZONTAL PLANE. A plane through any part of a tooth at right angles to its length. See Figure 9, Vol. 2.

HORN. A slender, or blunt pointed process of the pulp of a tooth extending toward the point of a cusp is called a horn of the pulp, or a pulpal horn.

HORN OF THE PULP. A process of pulp tissue extending toward the cusp of a tooth.

HORN OF THE PULP CHAMBER. The projection of the pulp chamber of a tooth toward a cusp. It is, in normal conditions, occupied by the horn of the pulp.

HYPEREMIA. An excess of blood in the blood vessels of a part. Active hyperemia, an excessive inflow of blood to a part. Passive hyperemia, diminished outflow of blood from a part; or a filling of the tissues of a part with blood because of some interference with the circulation of the blood through the part. These are also called arterial hyperemia and venous hyperemia.

HYPERESTHESIA. Abnormally increased sensitiveness to painful impressions.

HYPERSENSITIVE. Excessive sensibility to irritation, thermal, chemical or mechanical. Hypersensitive pulp. Hypersensitive dentin. See Hyposensitive.

HYPERSENSITIVENESS. A condition of abnormally increased sensitiveness to pain, or abnormally increased pain from definite causes which usually excite pain. See Hypoesthesia.

HYPOESTHESIA. Diminished sensitiveness to impressions which usually excite pain.

HYPOPLASIA. Abnormally diminished growth of a part. A partial failure of development because of lack of the ordinary full and complete growth. Syn. Atrophy.

HYPOSENSITIVENESS. Abnormally diminished pain from definite causes which excite pain.

HUTCHINSON TOOTH. An incisor tooth presenting a notch or defect in the central portion of the incisal edge, caused by atrophy.

IMMEDIATE ROOT FILLING. Root filling inserted immediately after removal of the pulp of the tooth.

IMMOBILE. The opposite of mobile. The features of the person present less than the usual flexibility of muscular motion in speaking, laughing, etc. See Mobile.

IMPACTED TEETH. Teeth confined in the jaw and prevented from erupting. Teeth that have taken a wrong direction and have failed to erupt.

IMPLANTATION. The operation of forming an artificial alveolus in the alveolar process and inserting in it a natural tooth.

INCISAL. Pertaining to the cutting edges of the incisors and cuspids, which in the use of the word incisal are regarded as incisal surfaces.

INCISAL MARGIN. That margin of a surface of an incisor or a cuspid tooth formed by the incisal surface or cutting edge; as the incisal margin of the labial surface of the central incisor; the cavo-surface angle of the incisal wall of a labial or lingual cavity, etc.

INCISAL SURFACE. The cutting edge of the incisors and cuspids are sometimes called incisal surfaces.

INCISOR. A tooth with a cutting edge. There are four incisors in the upper jaw, and four in the lower jaw. They are called the upper and lower right and left central, and the upper and lower right and left lateral incisors.

INCLINATION. Of a tooth: The deviation of the long axis of a tooth from the perpendicular line; as the mesial inclination of the incisors. Of a surface: The

deviation of a portion of the surface of a tooth from the general plane of that surface. Inclinations of the teeth become abnormal when they are such as to disturb the harmony of the positions of the teeth in the arch. Used also in describing the angles with the surface of the tooth at which the walls of a cavity may be cut, or of the relation of opposing walls to each other, as outward inclination, inward inclination, etc. Also, inclination of enamel rods from a line perpendicular to the surface of a tooth.

INCLINATION OF ENAMEL RODS. Used in describing either normal or abnormal inclinations of the enamel rods from a direction perpendicular to the surface of the tooth.

INCLINE. See Inclination.

INLAY. A porcelain or metal filling for inserting in a cavity prepared for it in a tooth; and retained by cement.

INSTRUMENTATION. All uses of instruments in dentistry are included under this term.

INSTRUMENT GRASPS. Definite ways of grasping instruments suited to their uses, such as the pen grasp, thrust grasp, etc.

INTERGLOBULAR SPACES. Spaces left without calcium salts during the development, or growth, of the dentin. Many of these appear as spaces between imperfectly fused globules.

INTERPROXIMAL. Between adjoining surfaces. The space between adjoining teeth as they stand in the line of the arch.

INTERPROXIMAL SPACE. The V-shaped space bounded by the proximal surfaces of adjoining teeth, and the border of the septum of the alveolar process between their necks. Normally this space is filled with gum tissue.

INVERTED CONE BUR. A bur head in the form of a cone, the apex of which forms the attachment with its shaft. See Figures 170, 171, Vol. 2.

INVERTED PEN GRASP. In this the fingers are so bent as to invert the ordinary position of the instrument. Used in some special positions. See Figure 55, Vol. 2.

INWARD INCLINATION. In comparative dental anatomy, a tooth that is inclined lingually. In dentistry, lingual inclination should be used.

LABIAL. Pertaining to the lips. Toward the lips.

LABIAL CAVITIES. Cavities beginning in the labial surfaces of the incisors and cuspids.

LABIAL INCLINATION. An inclination or leaning of a tooth labially.

LABIALLY. A direction toward the lips.

LABIAL SURFACE. The surface of a tooth next to the lips. The incisors and cuspids have labial surfaces.

LABIO-LINGUAL. From the lips toward the tongue; as the labio-lingual diameter of the central incisor.

LABIO-LINGUALLY. A direction from the lips toward the tongue.

LANCET. An instrument with small blade for incising soft tissues.

LATERAL ALVEOLAR ABSCESS. An abscess located in the peridental membrane anywhere along the sides of the root of a tooth and not involving the apical space. The pulp of the tooth may be alive. Lateral alveolar abscesses occur most frequently in phagedenic pericementitis but may occur from accidental causes, such as thrusting a spicula of wood from a toothpick into the peridental membrane, etc.

LIGATURE. Anything that binds. A cord or thread for tying blood vessels, or for tying around the teeth.

LIGATURES. Threads of floss or twisted silk used as aids in adjusting the rubber dam, tying it in place, tying on matrices, etc.

LINE ANGLES. Of the teeth: Those angles formed by the junction of two surfaces along a line; as the mesio-buccal angle, disto-buccal angle, etc. Of cavities: Those angles formed by the junction of two cavity walls along a line; as disto-buccal angle or axio-gingival angle. See Sets of Line Angles.

LINES OF ACCRETION. The lines of accretion or of contemporaneous growth seen in the enamel of the teeth. They are also known as the lines of Ritzeus, the person who first described them. See Accretion.

LINGUAL. Next to, or toward the tongue; as lingual surface.

LINGUAL CAVITIES. Cavities beginning in the lingual surfaces of the teeth.

LINGUAL INCLINATION. Said of teeth when they are inclined toward the tongue, or of a cavity wall that inclines toward the tongue; anything inclined toward the tongue.

LINGUALLY. A direction toward the tongue.

LINGUAL SURFACE. A surface of a tooth next to the tongue. All of the teeth have lingual surfaces. In comparative dental anatomy these are called inner surfaces.

LINGUO-DISTAL INCLINATION. An inclination of the teeth to the lingual and distal often seen in the lower bicuspids when a lower first molar has been lost in childhood or youth. Anything inclined linguo-distally.

LINGUO-GINGIVAL FISSURE. A fissure occurring occasionally in the lingual surface of the upper incisors. It usually separates the lingual lobe from one of the marginal ridges and extends into the cementum.

LINGUO-GINGIVAL RIDGE. A ridge near the gum on the lingual surface of the incisors and cuspids. It is on the lingual lobe.

LOBE. A division of a tooth formed from any one of the separate points of the beginning of calcification.

MALOCCLUSION. An occlusion of the teeth that is not in accordance with the usual anatomical rule, or form.

MALPOSED. Out of the correct or normal position.

MALPOSITION. Any wrong position; abnormal position.

MAMMELONS. The three rounded prominences seen on the cutting edges of the incisors when they first come through the gums.—Magitot.

MANDREL. A shaft or spindle in which a disk or stone is held for rotation. Used in the dental engine.

MARGINAL LINES, of a cavity. The lines of the cavity outline.

MARGINAL RIDGE. The ridges, or elevations of enamel on the margins of the occlusal surfaces of the bicuspids and molars, and on the mesial and distal margins of the lingual surface of the incisors and cuspids.

MASSAGE. Systematic friction for the purpose of preventing or curing disease. Friction of the gums with the finger, or specially designed brush, as a prophylactic measure.

MASTICATE. *v.* To chew food. To reduce food to a pulp by trituration and mixing with solvents, as in chewing and in the insalivation of food in the mouth.

MASTICATION. *n.* The act of chewing; the triturating of the solid foodstuffs between the teeth, by which they are reduced to a pulpy mass. One of the functions of the teeth.

MATRIX. A mold in which anything is formed. A thin sheet of metal closely fastened on a tooth to form a fourth surrounding wall of a proximal cavity in a tooth. A platinum or gold lining of a cavity in which a porcelain or gold inlay is baked or fused. The mold formed of an investment into which gold or other metals are cast.

MEDIAN LINE. The anterior-posterior perpendicular central line of the body.

MESIAL. Toward the median line. Those surfaces of the teeth which, as they stand in the arch, and following its curve, are toward the median line, are called mesial surfaces.

MESIAL ANGLE. A contraction of mesio-incisal angle, also of mesio-bucco-occlusal angle (q. v.)

MESIAL CAVITIES. Cavities in the mesial surfaces of the teeth.

MESIAL INCLINATION. An inclination or leaning of a tooth mesially.

MESIALLY. A direction toward the median line following the curve of the arch formed by the teeth.

MESIO-BUCCAL ANGLE. The angle formed by the union of the mesial and buccal surfaces of the bicuspids and molars.

MESIO-BUCCO-OCCLUSAL ANGLE. The angle formed by the junction of the mesial, buccal and occlusal surfaces of the bicuspids and molars at a point.

MESIO-DISTAL. From mesial to distal; as, the mesio-distal diameter of the lower first molar.

MESIO-DISTALLY. A direction from the mesial toward the distal following the curve of the dental arch.

MESIO-DISTAL PLANE. A contraction of axio-mesio-distal plane (q. v.).

MESIO-INCISAL ANGLE. The angle formed by the junction of the mesial surface and cutting edge, or incisal surface, in the incisors and cuspids.

MESIO-LABIAL ANGLE. The angle formed by the union of the mesial and labial surfaces of the incisors and cuspids.

MESIO-LINGUAL ANGLE. The angle formed by the union of the mesial and lingual surfaces of the teeth.

MESIO-LINGUAL GROOVE. A developmental groove running from the mesial surface diagonally to the lingual surface in upper first molars that have the fifth cusp.

MESIO-LINGUO-OCCLUSAL ANGLE. The angle formed by the junction of the mesial, lingual and occlusal surfaces of the bicuspids and molars at a point.

MESIO-OCCLUSAL ANGLE. The angle formed by the union of the mesial and occlusal surfaces of the bicuspids and molars. It forms the mesial marginal ridge of the occlusal surfaces.

METABOLISM. The sum of the nutritive processes in cells and organs of living things. It includes the vital phenomena of absorption, assimilation and nutrition on the one hand and the biochemical changes in the liberation of waste products on the other.

MICROMETER. An instrument for the measurement of very minute divisions of space. They are made to measure divisions of one thousandth or one ten-thousandth of an inch; one hundredth, or one thousandth of a millimeter, etc.

MICROPHOTOGRAPH. A photograph of microscopic size made of any ordinary object. In this the image produced is very much smaller than the object.

MOBILE. Having wide movements, as mobile features, mobile lips, etc. The features of a person may be very mobile so that the teeth come prominently into view in laughing and speaking. This does not mean prominent teeth. See Immobile.

MUCIN. An albuminoid substance, the chief constituent of mucus. It is insoluble in water and is precipitated by alcohol, alum and acids. Mucin is present in saliva, mucous secretions, the bile, and in certain cysts. Dorland.

MUCUS. A thick viscid secretion from the mucous follicles situated in the mucous membranes of the mouth. A somewhat similar mucus is found on other mucous membranes.

NAMES OF ANGLES OF CAVITIES AND SETS OF CAVITY ANGLES. The first set of line angles is formed by the junction of the surrounding walls of a cavity with each other. In occlusal cavities these will be the mesio-buccal, mesio-lingual, disto-buccal and disto-lingual angles. In simple mesial or distal cavities they will be the bucco-gingival, linguo-gingival, bucco-occlusal and linguo-occlusal angles. In simple buccal or lingual cavities, they will be the mesio-gingival, disto-gingival, mesio-occlusal and disto-occlusal angles.

A second set of line angles will be formed in occlusal cavities by the junction of the surrounding walls with the pulpal wall. And in mesial, distal, buccal and lingual cavities by the junction of the surrounding walls with the axial wall. In occlusal cavities these will be the pulpo-mesial, pulpo-buccal, pulpo-distal and pulpo-lingual angles. In simple mesial or distal cavities these will be the axio-gingival, axio-buccal, axio-occlusal and axio-lingual angles. In buccal or lingual cavities these will be the axio-gingival, axio-distal, axio-occlusal and axio-mesial angles.

The point angles in occlusal cavities will be the pulpo-mesio-buccal, pulpo-disto-buccal, pulpo-mesio-lingual and pulpo-disto-lingual. In simple mesial and distal cavities these will be the axio-bucco-gingival, axio-linguo-gingival, axio-bucco-occlusal and axio-linguo-occlusal angles. In simple buccal or lingual cavities these will be the axio-mesio-gingival, axio-disto-gingival, axio-mesio-occlusal and axio-disto-occlusal angles.

In any case in which a mesial, distal, buccal or lingual cavity is cut into the occlusal surface forming a complex cavity, the angles toward the occlusal are missing and the angles that are formed in the step portion will be named as in simple occlusal cavities. In this case, and in any of these cavities, the junction of the axial and pulpal walls will form the axio-pulpal line angle. In mesio- or disto-occlusal cavities the junction of this with the buccal and lingual walls will form the axio-pulpo-buccal and the axio-pulpo-lingual point angles. In bucco- or linguo-occlusal cavities the axio-pulpo-mesial and axio-pulpo-distal point angles are formed in a similar way. See Note on Compound Words following definition of Angle.

In incisor or cuspid mesial or distal cavities, the first set of line angles will consist of the labio-gingival, linguo-gingival and incisal angles. The second set will be the axio-labial, axio-gingival and axio-lingual angles. The point angles will be the axio-labio-gingival, axio-linguo-gingival and the axio-incisal. This latter is usually called the incisal angle and is regarded as an exception to the rules of naming angles of cavities.

In incisor or cuspid labial or lingual cavities the first set of line angles will be the mesio-gingival, disto-gingival, mesio-incisal and disto-incisal. The second set will be the axio-mesial, axio-distal, axio-gingival and axio-incisal.

The point angles will be the axio-mesio-gingival, axio-disto-gingival, axio-mesio-incisal, axio-disto-incisal.

NAMES OF CAVITY MARGINS. Cavity margins take the names of the margins of the surfaces of the teeth in which they occur; or each cavity margin takes the name of the cavity wall of which it forms the margin or cavo-surface angle. Therefore, cavity walls, cavity margins, cavo-surface angles and margins of surfaces of teeth, take the same names, the difference being only the specification as to which they belong.

NAMES OF CAVO-SURFACE ANGLES OF CAVITIES. Each cavo-surface angle of a cavity takes the name of the cavity wall to which it belongs. See Names of Cavity Margins.

NAMES OF MARGINS OF SURFACES OF THE TEETH. These take the names of the surfaces of the teeth toward which they are placed. In the bicuspids and molars these are the mesial, buccal, distal and lingual margins of occlusal surfaces; the mesial, occlusal, distal and gingival margins of buccal and lingual surfaces; the buccal, occlusal, lingual and gingival margins of mesial and distal surfaces. In

the incisors and cuspids these are the mesial, incisal, distal and gingival margins of labial and lingual surfaces. Proximal surfaces of the incisors, because of their triangular form, have but three margins: the labial, gingival and lingual. The incisal surface or edge is not supposed to have margins ordinarily requiring names, but in case of any necessity, especially in cases of considerable abrasion, the margins would be named on the same plan as the above.

NAMING OF CAVITIES, rule for. See Rules for Naming Cavities.

NAMING OF CAVITY WALLS, rules for. See Rules for Naming Cavity Walls.

NAYSMITH'S MEMBRANE. A membrane-like glaze covering the enamel of a tooth, discovered by Naysmith. It may be parted from the enamel by careful digestion in weak solutions of acids. It is worn away from the parts of the teeth exposed to friction very early in life.

NECK. That portion of the tooth which forms the junction of the crown and root.

NECROSIS. Local death of a part of a tissue, especially of bone, in a mass.

NECROTIC. Pertaining to necrosis or local death of tissue, particularly of bone.

NERVE. "Nerve of a tooth." Once a common name for the dental pulp. Obsolete.

NEURITIS. Inflammation of a nerve, or of nerves.

NEUROSIS. A functional disease of the nerves.

NIB. That part of a working end of a plugger point that corresponds to the blade of an excavator.

NOMENCLATURE. A system of naming things or acts. Each profession or business has its own system of naming things or acts pertaining to it.

NOMENCLATURE OF CAVITIES. In dentistry, a system of nomenclature applied to cavities in teeth. Under this term is included all of the names of cavities. Names of cavity walls, of angles of cavities and their terms of cavity description, together with the rules of their use.

NON-COHESIVE GOLD. Gold in the form of foil or crystals in which the welding property is obscured, usually by the condensation of some gaseous substance upon it, or a film of a salt from the union of two or more gases.

OBLIQUE RIDGE. A ridge running obliquely across the occlusal surface of the upper molars. It is formed by the union of the triangular ridge of the disto-buccal cusp with the distal portion of the ridge forming the mesio-lingual cusp.

OCCLUDE. To shut; to close.

OCCLUSAL. *a.* The surfaces of the teeth which come together when the jaws are closed, are called occlusal surfaces.

OCCLUSAL CAVITIES. Cavities formed by decay beginning in the occlusal surfaces in the bicuspids and molars. They are all pit or fissure cavities.

OCCLUSAL SURFACE. *n.* That surface of a bicuspid or molar tooth that makes contact with a tooth of the opposite jaw when the mouth is closed.

OCCLUSION. The act of closing or shutting. The closing of the teeth. "Correct occlusion," the normal contact of the teeth of each jaw when the mouth is closed.

ODONTOBLASTS. A layer of oblong cells that line the pulp chambers of the teeth. They are the dentin forming cells. Processes from the odontoblasts pass through the dentinal canals to the dento-enamel junction, and to the junction of the dentin and cementum. See Fibrils of Tomes.

ODONTOCLASTS. The giant cells which are the active agents in the absorption of the roots of the deciduous teeth.

"ONE-TWO-THREE." "1-2-3." A local antiseptic composed of oil of cassia, 1 part, carbolic acid (melted crystals) 2 parts, oil of wintergreen, 3 parts. The oils should be mixed and the melted crystals of carbolic acid added.

OPERATIVE DENTISTRY. Those operations upon the natural teeth and the soft parts connected with them that are usually performed by the dentist for their conservation, or cure of disease. It includes the employment of such drugs or remedial agents as may be necessary.

ORAL. Pertaining to the mouth, as Oral Surgery.

ORDER NAMES, of instruments. A name given to any group of instruments which designates their use, as excavators, pluggers, etc.

ORDINARIES, as applied to cutting instruments. The usual hatchets and hoes used by dentists in excavating cavities.

ORTHODONTIA. The moving of malposed teeth to correct positions. The art of regulating the position of malposed teeth.

OSMOSIS. The act of the passage of soluble salts through animal membranes.

OSTEOBLASTS. The cells which form bone.

OSTEOCLASTS. The giant cells which effect the absorption and removal of bone.

OUTLINE FORM. In cavity preparation; the form of the area of tooth surface included in the prepared cavity.

OUTWARD INCLINATION. Said of cavity walls when they diverge from each other in approaching the surface of the tooth.

PACKER. See Plugger.

PALATAL. Pertaining to or directed toward the palate. "Palatal surfaces of the teeth." Obsolete.

PALM-AND-THUMB GRASP. The instrument shaft is grasped in the palm of the hand and the working point brought into opposition to the thumb as a counteracting force. Used in positions in which an instrument can be applied to one side or portion of a tooth, or other object, while the thumb of the same hand is rested upon it, or upon adjacent teeth. See Figure 29, Vol. 2.

PALM THRUST GRASP. The end of the instrument handle is placed in the hollow of the palm of the hand and grasped by the fingers. Used for making a powerful thrust. See Figure 30, Vol. 2.

PEN GRASP. A grasp of dental instruments closely resembling the usual grasp of a pen used in writing. In the use of dental instruments the pulps of the thumb, first and second fingers should be on the instrument shaft. See Figure 26, Vol. 2.

PERICEMENTUM. The membrane covering the cementum of the roots of teeth. See Peridental Membrane.

PERIDENTAL MEMBRANE. The membrane surrounding the root of a tooth and forming its attachment to the walls of its alveolus. It is composed of fibers which are built into the cementum on the one side and into the bone on the other. Among these fibers there is an abundant network of blood vessels, nerves and cellular elements.

PERIOSTEAL BONE. Bone laid down by the osteoblasts of the periosteum as distinguished from Haversian systems bone.

PERMANENT TEETH. The teeth of adult age as distinguished from the temporary, or deciduous teeth.

PERMANENT TEETH, CHILDHOOD PERIOD OF. The period from the first appearance of the permanent teeth until their roots are fully completed, except the third molars. See Figure 187, Vol. 1.

PERSONAL EQUATION. When one person accomplishes any certain result which another fails, or in part fails to do, and the differences in opportunity and method seem inexplicable, the difference is said to be a personal equation. As these differences are being occasionally explained by more acute observation or by physical measurements, they are found to be due to personal physical conditions, or to differences in mental grasp of requirements.

PHAGODYNAMOMETER. An instrument by which the force required in crushing different examples of foodstuffs is determined. See Figure 166, Vol. 1.

PHOTOMICROGRAPH. A photograph of a tissue or other prepared object taken by transmitted light with a microscopic lens. This should be distinguished from a photograph made by reflected light by a microscopic lens of low power such as the photograph of a tooth in which the object is enlarged from two to eight or ten diameters. Photomicrographs may have an enlargement anywhere from two or three diameters to a thousand or more.

PIT. A sharp, pointed depression in the enamel. Pits occur mostly where several developmental grooves join; as in the occlusal surfaces of the molars, at the endings of the buccal grooves on the buccal surfaces of the molars; occasionally in the lingual surfaces of the incisors.

PIT CAVITIES. Those cavities that begin in pits. Cavities formed by decay that begins in pits of any kind or in any position. See Figures 68, 69, 70, 71, 75, 76, 77, Vol. 1.

PLANES of the teeth. Any planes cutting the teeth in definite directions, as the axial plane, horizontal plane, etc.

PLAQUE. A flat circumscribed area or plate; a flat plate made up of a colony of microörganisms in zoöglea form, clinging to enamel of the teeth.

PLASTICS. Materials like cements, gutta-percha and amalgam for filling cavities in teeth; a material for any purpose that may be easily modeled and built into form.

PLUG. A filling placed in a prepared cavity in a tooth is often called a plug. In England the word stopping is used. See Filling.

PLUGGER. An instrument for condensing gold or other material in cavities in teeth. These are sometimes called packers or packing instruments.

PLUGGING INSTRUMENTS. See Plugger.

POINT ANGLES. Of the teeth: Those angles formed by the junction of the angles of three surfaces at a point; as the disto-bucco-occlusal angle, the mesio-bucco-occlusal angle, etc. Of cavities: Those angles formed by the junction of three cavity walls at a point; as the axio-bucco-gingival angle.

POINT OF PROXIMAL CONTACT. The point at which the proximal surface of a tooth touches the proximal surface of a neighboring tooth. See Contact Point.

POSITIONS AT THE CHAIR. Those positions which the dentist should assume in doing dental operations. A systematized nomenclature of positions at the chair. See Figures 34-45, inclusive, Vol. 2.

PREPARATION OF CAVITIES. Those operations required in forming cavities in teeth for the reception of fillings.

PROGNATHISM. Abnormal protrusion of one or both jaws.

PROGNATHOUS. Having projecting jaws.

PROGNOSIS. A prediction as to the progress and result of a disease.

PROPHYLACTIC. Tending to prevent disease; guarding against disease. A medicine or preparation which defends or protects against disease. Something applied to healthy tissue to prevent disease.

PROPHYLAXIS. Preventive medicine. Oral prophylaxis: Preventive measures against diseases of the mouth.

PROXIMAL. Latin; proximus, near; propior, nearer; propious, next or nearest.

NOTE. This is the oldest form of the word in the Latin. In use in the Latin, proprius became obsolete; in time the word went through many changes and proximus was used as the superlative adjective, meaning nearest — next in line before or after. But in following the word through the time of the active use of the Latin language, we find it used in a variety of subjects, as: Time, next day, next month, or next year. Relationship, next of kin, next neighbor. Of things, next house. Of a series, the next preceding or following, etc. Quotations from Harpers' Latin Dictionary. Proximus: of place, nearer, nigher; of time, nearer, later, more recent; of relationship, nearer, more nearly related; of resemblance, more nearly resembling, more like; of relation or connection, more nearly related, of greater import, closer, more intimate.

In later composition. Proximus: The nearest, next, one's nearest neighbor, close by, next door. The next preceding or following; the previous, the last; the next, the following, ensuing; time, recently, last of all, next day, next month, next year, etc.

Webster defines proximal thus: "Toward or nearest, as to a body or center of motion or dependence. Proximate. (*Biol.*) (a) Situated near the point of attachment or origin; as the proximal part of a limb, twig or leaf. (b) Of or pertaining to that which is proximal; as the proximal bones of a limb. Opposed to distal."

Dentistry: That surface of a tooth that is toward, nearest, or in contact with another tooth to the mesial or distal as the teeth are arranged in the arch.

NOTE. The word proximal has been much used in anatomy and botany as the opposite of distal, or as next to a thing understood; as the central body, or trunk. The proximal end of a bone is that nearest the central line of the body. The distal end, that which is farthest from the central line of the body. In botany, it is used in a similar sense, the portion of the limb of a tree nearest the trunk is the proximal portion. It is used in the same manner in the description of twigs and leaves. It is also used in the adverbial form (proximally) to express direction along a limb, twig or leaf. This meaning has been acquired in recent time and is not quite in harmony with the Latin use of the adjectives of proximare, near to or next to anything or object preceding or following.

John Tomes gave us the word mesial as the opposite to distal instead of proximal for naming surfaces of the teeth. In this use, mesial designates the surface of a tooth toward the median line, and distal the surface farthest from the median line. Much difficulty was experienced by many persons in the use of these words until the definition of their meaning, when applied to the surfaces of the teeth, was extended by the additional words italicized in the following definition. By mesial is meant those surfaces of the teeth which, *as they stand in the arch, and following its curve*, are toward the median line. This seemed satisfactory and the use of the words, mesial and distal, in place of proximal and distal, has become fully established. But there was a real necessity for a word that would designate collectively the surfaces defined as mesial and distal and the usage of many persons in the dental profession has clung tenaciously to the term proximal, as meaning next, or next to, which is really its Latin signification, in spite of the fact that it has been used in a special sense in biology as next to the central part or point of origin, understood, but generally not mentioned except in definitions. In dentistry its use is nearer the original Latin meaning of the words from which the recent English adjective form has been derived.

Harris, in his writing, seems to have used proximal, proximate, approximate, approach, approaching, etc., in phrases describing proximal surfaces, but evidently did not regard any of these as assuming the force of nomenclature words, for he did not include any of them in his dictionary of terms.

In the literature pertaining to this, articles will be found in the *Dental Cosmos*, 1880, page 84 and page 139; 1890, page 325; which show in part one of the reasons for the confusion that still exists because of the introduction of the awkward term, approximal. Personally, I made objection then to the use of this term, foreseeing that it would give rise to much difficulty in compounding terms which were sure to come with advances in dental nomenclature. In conversation with Dr. James W. White, who was then editor of the *Dental Cosmos*, I obtained the history of this effort to substitute the word approximal. After a study of this, Dr. White decided to favor this word and applied to several persons who were then engaged in the revision of dictionaries, asking that the word be inserted with a definition he had written. This was not granted, because there was no literature showing the use of the word. Dr. White then wrote one or more articles using the word, caused them to be printed and presented them as evidence of its use in the literature. In this way he succeeded in having it inserted in Thomas' Medical Dictionary. It seems not to have been placed in other dictionaries. Dr. White should be credited with an earnest endeavor to improve dental nomenclature. I still think his choice of this word unfortunate.

The word is obnoxious because of the addition of the unnecessary syllable, ap, and particularly so in such compounds as interproximal gum tissue, interapproximal becomes cumbersome. The fact is, many in the profession have held to the use of the word, proximal, in spite of every effort to displace it. I understood the full meaning of the incongruity of the use of the word proximal after its use in a changed signification from the Latin proximus, from next in line before or after, to next to the central trunk. I expressed this clearly in my report on dental nomenclature to the Columbian Dental Congress in 1893, and I continued the use of the word proximate, which had formerly been used by the *Dental Cosmos*. The editor of the *Dental Cosmos*, after making this choice, in editing articles for its pages changed all words used by writers and speakers to designate these surfaces to approximal. Many others have supported this effort, and yet the word proximal has not been displaced. This evident and persistent disposition of the dental profession to use the word, proximal, renders it the better word in spite of its use in a different sense from the original Latin adjective in biology. The bootblack makes a noun out of a verb — "Have a shine, sir," and the philologist must submit. Therefore, in this book the word proximal has been used.

PROXIMAL CAVITIES. Cavities beginning in the proximal surfaces of the teeth. As both mesial and distal cavities are included under this term, it is used only when it is intended to include mesial and distal cavities collectively, or when the position, mesial or distal, is not determined, or mentioned; as proximal cavities in the incisors.

PROXIMAL CONTACT. The contact, or touching, of the proximal surfaces of neighboring teeth.

PROXIMAL SURFACE. The surface of a tooth which lies next to another tooth, to the mesial or to the distal.

PROXIMATE. Formerly used instead of proximal. See Proximal.

PROXIMATING. A tooth or portion of the surface of a tooth making near approach to another tooth or portion of the surface of another tooth.

PROXIMATION. The near approach, or contact, of the proximal surfaces of the teeth.

PULP. The soft tissue that fills the pulp chambers and root canals of the teeth. It is the formative organ of the dentin.

PULP CANAL. The central opening lengthwise in the root of a tooth leading from the pulp chamber or bulb of the pulp in the crown portion of a tooth to the apical end of the root. Syn. Root Canal.

PULP CHAMBER. The central opening in the dentin of the crown portion of a tooth which is occupied by the pulp of the tooth. In the double and triple-rooted teeth, the pulp chambers are very distinct from the root canals, but in teeth having but one root the pulp chamber is not distinctly divided from the root canal.

PULPITIS. Inflammation of the dental pulp.

PUTREFACTION. Putrefactive fermentation. Decomposition with a foul odor of animal or vegetable matter, effected by the action of microörganisms. The true putrefactions occur only when oxygen is excluded, but decompositions of a somewhat similar nature occur in the presence of oxygen.

PUTRESCENT. A state of decomposition with emission of foul odor.

PYOGENIC. Said of a microörganism that generates pus, or causes pus formation. The staphylococcus albus, staphylococcus aureus, streptococcus longus, etc., are pus-generating microörganisms. They are therefore pyogenic.

PYORRHEA. A flow of pus. "Pyorrhea alveolaris." A flow of pus from the alveoli of the teeth.

QUADRANGLE. In instrument nomenclature designates an instrument with four angles or curves in the shank.

RANGE. Sizes of instruments or angles of their blades on definite comparative gradations.

RE. In the matter of, referring to. Murray.

RESISTANCE FORM. In cavity preparation; the shape given to the internal parts of a cavity to afford such a seat for the filling as will best enable it to withstand great stress without movement.

RESORPTION. The act of absorbing again. There has been an effort to use this word in a special sense, or to apply it to special kinds of absorptions, which seems not to have been very successful. Some writers use it in speaking of the absorption of the roots of the deciduous teeth.

RETENTION FORM. In cavity preparation; the form of the internal parts of a cavity provided to prevent the displacement of the filling by force.

RIDGE. A long-shaped elevation on the surface of a tooth.

RITZEUS, CALCIFICATION LINES OF. See Lines of Accretion.

ROOT. That portion of the tooth that is fixed in the alveolus, or socket, and is covered with cementum.

ROOT CANAL. The opening through the center of the long axis of the root of a tooth from the crown to the apex, which under normal conditions contains the root portion of the dental pulp. Syn. Pulp Canal.

ROPY SALIVA. Saliva that may be drawn out in threads by touching it with the finger and pulling away. See Viscid Saliva.

ROUND BUR. A bur, the head or cutting part of which is spherical in form.

RUBBER DAM. A thin sheet of very elastic rubber used for keeping the teeth, and especially cavities in the teeth, dry and clean while performing such operations as filling, removing pulps, filling pulp canals, etc.

RUBBER DAM CLAMP. An instrument made to set on teeth over the rubber dam to hold it in place, or over which the rubber dam may be thrown. It is made of spring steel, and, in applying it, it is opened with a special forceps, placed in position and allowed to close on the tooth with the force of its spring.

RUBBER DAM GRASPS. The forms of grasp of the rubber dam best suited to its application to teeth in different parts of the mouth. Of these there are five, numbered first, second, etc. See Figures 66-83, inclusive, Vol. 2.

RUGAE. A series of irregular ridges in the roof of the mouth.

RULES FOR NAMING CAVITIES. (1) Cavities in teeth take the names of the surfaces of the teeth in which they occur; as occlusal cavity, mesial cavity, etc. (2) When, from extension of decay or by cutting in cavity preparation, a second surface becomes involved, or two decays beginning in separate surfaces have become united, the names of the two or more surfaces involved are united in naming the cavity; as mesio-occlusal cavity, mesio-occluso-distal cavity. See Figure 3, Vol. 2.

RULES FOR NAMING CAVITY WALLS. (1) The surrounding walls of a cavity take the names of those surfaces of the teeth adjoining the surface decayed toward which they are placed; as, mesial wall, buccal wall, etc., of an occlusal cavity. See Figures 1, 3, Vol. 2.

(2) That wall of a cavity which is to the occlusal of the pulp, and in the horizontal plane, or at right angles to the long axis of the tooth, is called the pulpal wall. See Figures 1, 3, Vol. 2. In case the pulp of the tooth is removed and the cavity thus extended to the floor of the pulp chamber, it is called the sub-pulpal wall.

(3) That wall of a cavity in an axial surface of a tooth that covers the pulp is called the axial wall. See Figures 3, 7, Vol. 2. If the pulp of the tooth is removed, the cavity is extended to include the pulp chamber, the wall takes the name of the wall of the pulp chamber; as, the distal wall, in a mesial cavity.

(4) When one of the walls of a cavity is missing by extension of decay, or by extension by cutting in the preparation of a cavity for filling, so as to involve another surface of the tooth, a complex cavity is formed, and the remaining walls extend to the new surface involved.

SALIVA. The fluid poured into the mouth from the salivary glands. Usually when the saliva is spoken of without restricted definition, the mixed fluid as found in the mouth is meant. It is composed of the saliva proper from the parotid, submaxillary, sub-lingual and other smaller glands, and the secretion of the mucous follicles, which open into the mouth.

SCALER. A dental instrument for removing calculus from the teeth.

SCALING. The removal by special instruments of scale-like depositis of calculus from the crowns and roots of the teeth. A curetting process.

SENILE. Pertaining to old age.

SENSITIVENESS. The quality or capability of being sensitive to painful impression.

SEPARATOR. An instrument or mechanical appliance designed for forcibly separating teeth for obtaining space between proximal surfaces for examinations, excavation of cavities, finishing fillings, etc.

SEPSIN. A soluble poison (ptomain) present in putrid blood, flesh, or in proteid compounds.

SEPSIS. Poisoning of the system by the introduction of sepsin into the blood.

SEPTIC. Pertaining to poisonous matter produced by microörganisms; especially in connection with persistent pus formation.

SEPTUM. (Pl. Septa.) A partition; that portion of the alveolar process which lies between the roots of the teeth separating their alveoli. See Gum Septums.

SERUMAL. Pertaining to the serum of the blood. Derived from serum. Serumal calculus: Calculus on the roots of teeth derived from the blood.

SETS OF LINE ANGLES. First set: The line angles formed by the junction of the surrounding walls of cavities with each other; as, bucco-distal angle, linguo-gingival angle. See Figure 4, Vol. 2. Second set: The line angles formed by the junction of the surrounding walls of a cavity with (a) the pulpal wall in occlusal cavities; as pulpo-buccal angle; (b) the axial wall in axial cavities; as, axio-buccal angle, in a mesial or a distal cavity.

SIDE INSTRUMENTS. Such instruments as may be introduced into any regular set, but which do not follow the regular order of the nomenclature of the other instruments in the set.

SINUS. [L.] An opening; a hollow; a bending. An abnormal opening from an abnormal cavity to the surface, for the discharge of an abnormal secretion. See note following definition of fistula.

"In pathology, a narrow passage leading to an abscess or other diseased locality; a fistula." Century Dictionary.

"(Surgery.) A long, narrow, hollow tract leading from some abscess, etc. Dunglison." Worcester.

"(Medical.) A narrow, elongated cavity, in which pus is collected; an elongated abscess with only a small orifice." Webster.

"(Surgery.) Any long, narrow opening leading to an abscess or to a diseased structure." Standard Dictionary.

"A long, narrow pathological canal communicating with an abscess or a diseased tract." Foster's Medical Dictionary.

"An abnormal pathway or canal, usually the result of ulceration." Gould.

"Pathologically, sinus means a narrow tract of variable length, leading from a chronic abscess to a free surface." Quain.

SMOOTH-SURFACE CAVITY. A cavity formed by caries beginning in any smooth surface of a tooth, or portion of a surface free from pits or fissures. The term is confined to cavities beginning in the axial surfaces of the teeth.

SPECIALS, as applied to cutting instruments. Such instruments as are designed for doing special things in the preparation of cavities, as enamel hatchets, spoons, etc.

SPLIT TEETH. Teeth sawed through and the cut surfaces polished for showing the penetration of caries of enamel and dentin.

SPRUE. A piece of wood or metal used by a molder in casting metals, to form the ingate for the molten metal; used to form the passage or ingate for making an inlay of cast metal, gold, etc. Invested as attached to the wax model of an inlay and drawn out when the investment is "set."

STERILE. Not containing microörganisms; aseptic.

STERILIZATION. The process of freeing a substance from microörganisms and their spores.

STERILIZE. To thoroughly cleanse; to make an instrument or the hands and nails and tissues aseptic. To remove absolutely or destroy the life of all microörganisms and their spores; to make the hands and instruments surgically clean.

STOMATITIS. Inflammation of the mucous membranes of the mouth.

STOMATOLOGY. The sum of scientific knowledge concerning the mouth.

STOPPING. In England a filling in a tooth is called a stopping.

STRAIGHT ENAMEL. Enamel in which the enamel rods lay parallel with each other and usually are straight from the dento-enamel junction to the surface of the enamel. See Figure 146, Vol. 1. See Curled Enamel.

SUB-CLASS NAME. A name prefixed to a class name which describes the form of the shank of an instrument, as binangle hatchet, contra-angle hoe, etc.

SUB-ORDER NAME. A prefix to an order name designating the manner or place of use; as mallet plugger, hand-plugger, enamel hatchet, etc.

SUBPERIOSTEAL BONE. Bone lying under the periosteum. Bone formed from the periosteum as distinguished from Haversian systems bone.

SUCCEDANEOUS TEETH. The teeth which succeed to, or take the places of the deciduous teeth after the latter have been shed: The incisors, cuspids and bicuspids.

SULCATE GROOVE. A groove following the bottom of a sulcus.

SULCUS. (Pl. Sulci.) A notable long-shaped depression in the surface of a tooth, the inclines of which meet at an angle. A sulcus has a developmental groove at the junction of its inclines.

SUPPLEMENTAL GROOVE. A shallow long-shaped depression in the surface of a tooth, generally with a smoothly rounded bottom. Supplemental grooves differ from developmental grooves in that they do not mark the junction of lobes.

SUPPLEMENTAL LOBE. A lobe that does not belong to the typical form of the tooth; an additional lobe.

SUPPLEMENTAL RIDGE. A ridge on the surface of a tooth that does not belong to the typical form of the tooth; an additional ridge.

SUPPURATION. The act of pus formation. The formation of pus.

TEMPORARY TEETH. See Deciduous Teeth.

THE BITE. The power of force with which the teeth may be closed in the crushing of food, is called the strength of the bite, or simply, the bite. It is measured with the gnathodynamometer.

THICK-NECKED. A tooth in which the mesio-distal diameter of the neck is nearly equal to that of the crown. See Bell-crowned.

NOTE. The word neck and the Latin word cervix, the neck, have had some use in dentistry in which cervical has been the adjective form. The word cervical was used to represent a constriction, or a supposed constriction, between the crown of a tooth and its root, and, as used, its meaning was much too vague to serve the purposes of modern dentistry. Cervical is now practically obsolete.

THIRDS. Division of a crown of a tooth; as to length, into occlusal, or incisal third, middle third and gingival third; as to mesio-distal breadth, into mesial third, middle third, and distal third.

TINE. A tooth, a spike, as of a fork; a prong, as of an antler. (Webster.) A slender pointed instrument; as an exploring tine.

TOILET OF THE CAVITY. Consists in freeing the internal surfaces of the cavity from all chips or fine dust. The final cleaning of cavity walls before beginning a filling.

TRANSVERSE RIDGE. A ridge formed of two triangular ridges, which join to form a continuous ridge across the occlusal surface of a tooth.

TRIANGULAR RIDGE. A ridge running from the point of a cusp toward the central portion of the occlusal surface of a tooth.

TRYPSIN. One of the enzymes. See Enzyme.

TUBERCLE. A slight rounded elevation on the surface of a tooth. Tubercles occur frequently on the linguo-gingival ridge of the incisors, and occasionally upon various parts of other teeth. They are deviations from the typical tooth forms.

TUBULES. (Pl. Tubuli.) The minute tubular canals which radiate from the pulp chamber and canals through the dentin to the dento-enamel junction in the crown and to the dento-cemental junction in the root of the tooth.

ULITIS. A general inflammation of the gums as distinguished from gingivitus, which is confined to the free margins of the gums and immediate neighborhood.

VISCID SALIVA. Saliva that is noticeably thick or gummy. Usually the saliva is a very thin, watery fluid, but some persons have saliva that has so large a proportion of mucus that it is thick and tenacious to a very noticeable degree. See Ropy Saliva.

WHORLS. Circular forms or segments of circular forms with the form elements arranged somewhat after the plan of the spokes of a wheel. Or form elements arranged around a center.

ZONES OF INJURY. Said particularly of the injuries of the teeth in atrophy. These injuries are spread in sheets or zones through certain parts of the enamel and dentin.

ZOÖGLEA. A colony of microörganisms imbedded in a viscous gelatinous substance.

INDEX OF VOLUME I.

Abrasion, treatment by filling of platinum-gold, 201.
Abrasive action of food in relation to beginning decays of enamel, 85, 89.
Abscess, lateral, 187.
Absorbents, in drying cavity walls, 192.
Absorption of interproximal gum tissue, 103, 106.
  results of, 103, 106.
Absorption of interproximal gum tissue as a result of proximal decays, 101.
Absorption of roots of deciduous teeth, 127, 238, 239.
  accidents during, 241.
  variation in, 240.
Absorption of roots of permanent teeth, 127.
Absorption, process of, as cause of erosion, 49, 54.
Accidental exposure of pulp of first permanent molar during the childhood period, 270.
Accidents during absorption of roots of deciduous teeth, 241.
  delayed eruption of permanent teeth by, 243.
  failure of absorption, 241.
  injuries to crowns of permanent teeth by abscesses, 243.
  retained deciduous cuspids, 245.
  retained deciduous molars, 245.
  roots of deciduous molars remaining unabsorbed, 242.
  use of X-ray in treatment, 246.
  variations in the process of absorption, 244.
Accretion, lines of, in atrophy, 14, 16.
Acid as a cause of erosion, 49, 52.
Acid fermentation and caries as a result of absorption of interproximal gum tissue, 103.
Acidity of the saliva, 134.
  effect of on dental caries, 135.
Alkaline fluids as cause of erosion, 49, 55.
Amalgam as a filling material, 199.
Angles of teeth crossed by superficial spreading of caries, 113.
Antitoxins, 116.
Apical ends of root canals of the teeth open during the childhood period, 275.
Apical foramina, completion of, 260.
Apical space, tenderness in, from diseased tooth pulps, 169.
Application of extension for prevention, 143.
Area of liability, of gingival third cavities, 85, 113, 227.
  of proximal cavities, 81, 85, 113, 210.
Artificial cleaning of the teeth, 143, 154.
  in relation to superficial spreading of caries of enamel, 89.
  prophylactic treatment of dental caries, 188.
Asepsis of mouth impossible, 158.
Atrophy of the teeth, 6.
  accretion, lines of, in, 14, 16.
  an arrest of growth, 15.
  Baume, re, 19.
  blackened pits in incisors and cuspids, 29.
  calcification of first permanent molars, re, 8, 23.
  calcification of incisors, re, 8.
  Callow's case of general deformity of enamel, 32.
  care in filling blackened pits in incisors and cuspids, 29.
  caries of incisors as result of, 8.
  caries of first permanent molars as result of, 25, 125.
  case presenting general absence of cementing substance between enamel rods, 35, 36.
  caused by condition of malnutrition, 11.
  cementing substance absent between enamel rods, 35, 36, 38.
  character of injuries to teeth, in, 14, 23.
  color of teeth in, 11.
  danger of pulp exposure in, 24.
  decay of incisors as result of, 8.
  decay of first permanent molars as result of, 25.
  definition, 6.
  deformities of enamel other than, 32.
  dentin between enamel and pulp less than normal, in, 24.
  diagnosis of, 6, 185.
  discoloration of teeth, on account of, 18.
  due to malnutrition, 38.
  enamel, spots in, 30, 38.
    telescoping of, 15.
  etiology, 11.
  filling in treatment, 25.
  first permanent molars, 8, 23.
    frequence of, 23.

Atrophy of the teeth (continued).
general deformity of the enamel, 32.
gold cap for first molars, 27.
histological characters in, 14.
Hutchinson, re, 11.
Hutchinson teeth, 7, 11.
illness, effect of, 6.
illustrations of, statement re, 7.
incisors, 7, 8.
injury to dentin, 17.
injury to enamel, 8, 15.
interglobular spaces in dentin, in, 17.
introduction, 2.
inverted finger nail deformity, 10.
lines of contemporaneous calcification as modified by, 14.
location of, on the teeth, 7, 10, 14.
Magitot, re, 11.
malnutrition as cause of, 11.
measles as cause of, 13.
modification of the curve of the line of the dento-enamel junction in, 18.
observations of cases, 12.
overlapping of enamel in, 15.
oxyphosphate of copper cement in filling, 26.
permanent fillings in first molars, 28.
pits in the enamel, 30, 38.
portion of the teeth affected by, 7.
Prunty's case, white enamel, 35.
pulps of, closer to enamel than normal, 29.
rapid progress of caries in atrophied first permanent molars, 25.
recurve of line of dento-enamel junction, 18.
repair in human teeth, no process of, 6.
result of measles, 13.
no special disease, 11, 13.
scarlet fever, 13.
syphilis, 7, 11, 13.
whooping cough, 13.
Ritzeus, lines of, in, 14, 16.
root, atrophy of, 20.
roots of teeth well developed in, 11.
scarlet fever as cause of, 13.
shortening of teeth in, 17.
Smith's case of general deformity of enamel, 34.
syphilis as cause of, 7, 11, 13.
teeth affected by, 7.
telescoping of enamel in, 15.
temporary treatment of first molars, 26.
incisors, 29.
treatment of, 25, 28.
Walkhoff, re, 19.
Wedl, re, 19.
white enamel, 35.
white spots in the enamel, 34.
whooping cough as cause of, 13.
Zsigmondy, re, 19.
Author's experiments re cause of erosion, 53.
Author's studies of hardness and softness of teeth, 119.
general summary of results, 120.
Author's studies of the microörganisms of the mouth, 138.
Axial angles of teeth, immunity of, 88, 90.

Bacillus alba, 139.
Backward decay of enamel, 66.
Baume, re atrophy, 19.
Beginnings of dental caries, necessity of closer study of, 143.
Bell, re dental caries, 62.
re etiology of erosion, 50.
Bicuspid teeth, see Childhood period of permanent teeth, Gingival third cavities, Pit and fissure cavities, Proximal cavities.
Bite, force of, 161.
tests of, 163.
Bone, comparison of physiological conditions of, with teeth, 126, 191.
Brush, for the teeth, 155.
Brushing the teeth, 155.
Buccal and labial cavities. See Gingival third cavities.
Buccal and labial surfaces, examination of, 181.
value of artificial cleaning by patient, 189.

Cacochymic saliva, 130.
Calcic inflammation of gums, 186.
Calcification of deciduous teeth, 238.
of first permanent molars, 8, 23.
of incisors, 8.
of permanent teeth, 258.
of permanent teeth as modified in atrophy, 14.
Calcium salts of dentin dissolved out in advance of microörganisms, 70.
Calcium salts of teeth, no changes in, 126, 191.
variation in amount in different teeth, 119, 120.
Callow's case of general deformity of enamel, 32.
Capping of pulps of first permanent molars during childhood period, 270.
Care in filling blackened pits in atrophied incisors and cuspids, 29.
Care in operating, not to arouse thermal sensitiveness, 151.
Care of the eyes of the dentist, 172, 173.
Caries fungus, 139.
Caries of the teeth, 2, 60.
abrasive action of food, in relation to beginnings of, 85, 89.
absorption of interproximal gum tissue, resulting in, 103.
acidity of saliva, effect of, 135.
angles of teeth crossed by superficial spreading, 113.

Caries of the teeth (continued).
angles of teeth immune, 88.
application of extension for prevention, 143.
areas of liability to, 81, 85, 113, 210, 227.
arrest of, by cleaning by patient, 182.
artificial cleaning in relation to superficial spreading, 89.
atrophy of first permanent molars, caries in, 25, 125.
author's studies of hardness and softness of teeth, 119.
axial angles of teeth generally immune, 90.
backward decay of enamel, 66.
beginnings of, necessity of closer study, 143.
Bell, re, 62.
buccal decays, see Gingival third decays.
calcium salts of dentin, dissolved in advance of microörganisms, 70.
calcium salts, variations in amount of, 119, 120.
cause of, 68.
cavities, tenderness of, as a cause of tenderness of peridental membrane, 169.
chemical theory of, 63.
cleaning, artificial, re, 89, 143, 154, 182, 188.
clinical features of, as a whole, 91.
differences between proximal decays in bicuspids and in molars, 98.
divorcement from pathology, 91.
gingival third decays, 109.
occlusal and proximal decays in bicuspids, 97.
occlusal decays in molars, 92.
pit and fissure decays, 92.
proximal decays in incisors, 107.
proximal decays in molars, 93.
contact, relation of proper restoration of, to recurrence of decay, 90, 222.
crowding of food between the teeth, results of, 103.
curative effect of fillings, 193.
deciduous incisors and cuspids, treatment of, 248.
deciduous molars, occlusal surfaces of, 253.
proximal surfaces of, 254.
definition of, 65.
dentin, caries of, 66, 68, 74, 91, 142.
conical area of caries of, 70.
disappearance of division walls of tubules, 71.
enlargement of tubules, 71.
etiology, 68.
microörganisms in, 69, 71, 73.
slowness of progress of, 72.
swellings of tubules, 71.
dentinal fibrils, how destroyed by, 148.
dento-enamel junction, spreading along, 69.
dialysis of saliva, re, 69.
disease, a, of youth, 117.
Duddei, Augustin, German translation of Fouchard, re, 62.
embrasures, relation of width of, to proximal decays, 87.
enamel, caries of, 65, 74, 83, 91, 142.
backward decay of, 66.
beginning in pits and fissures, 76.
beginning in smooth surfaces, 80.
closer examination of injury to, 83.
etiology, 68.
localizations of beginnings of, 74.
microörganisms in, 74.
penetration of, in buccal and labial surfaces, 90.
penetration of, in pits and fissures, 76.
penetration of, in proximal surfaces, 77.
penetration of, in smooth surfaces, 77.
preparation of specimens, 83.
swelling of decayed area, 101.
enamel, faults of, re, 124.
fissures in, re, 124.
esthetic consideration in treatment, 232.
etiology of, 68.
examinations for, 180.
extension for prevention, application of, 143.
faulty structure of teeth, re, 124.
filling, effect of, on superficial spreading, 89.
first permanent molars, during childhood period, 265.
fissures, decay in, 124.
Fouchard, re, 62.
Fox, re, 62.
fungus, caries, cause of, 73.
gelatinous masses on the teeth, 129.
plaques in relation to gingival third decays, 111.
general statement, re, 65.
gingival third decays in labial and buccal surfaces, 109.
clinical features, 109.
conditions favoring, 109.
intermittent progress of, 111.
management of, 225.
relation of gum margin to, 89.
relation of occlusion to, 85.
saliva, effect of, favoring certain deposits, 111.
several teeth often attacked, 90.
glutinous deposits from the saliva, 136.
granular layer of Tomes, re, 69, 125.
gum margin, relation of, to beginning decays, 87, 89.
hardness of teeth, re, 118.

Caries of the teeth (continued).
hereditary predisposition to, 116.
conditions that influence, 116.
stronger in youth, 117.
historical, 60.
Hunter, John, re, 62.
hyaline area of Tomes, 93, 95, 108.
illustrations of, statement re, 70.
immunity to, 3, 115, 130.
of axial angles of teeth, 88, 90.
changes in, 118.
conditions of, 130.
recognition of, 137.
sulphocyanids in saliva, influence of, 131.
incisor teeth, caries in, as a result of atrophy, 8.
injuries to the enamel by, examination of, 83.
interglobular spaces in dentin, re, 69, 125.
interproximal gum tissue, absorption of, resulting in, 103.
interproximal wear, resulting in, 106.
Köeker, re, 62.
labial decays, see Gingival third decays.
lateral incisors, lingual pits of, during childhood period, 272.
Leber and Rottenstein, re, 64.
lingual pits of lateral incisors, during childhood period, 272.
localization of beginnings of caries of enamel, 74.
location of nidus of each beginning of, 89.
lodgments which do not cause, 111.
Magitot, re, 64.
mastication, cleaning power of, 167.
Michaels, re, 129.
microörganisms, in caries of dentin, 71, 73.
in caries of enamel, 74.
limit of superficial spreading of, 89.
Miles and Underwood, re, 64.
Miller, W. D., re, 65, 71, 91, 142.
near approach of surfaces in relation to form of proximal decays, 86.
necessity of closer study of beginnings of, 143.
New York State Dental Society, Committee of, studies re, 131, 136.
nidus of beginning of, 89.
occlusal surface decays, clinical features, 92.
importance of early discovery of, 97.
in bicuspids, 97.
in molars, 92.
occlusion, relation of, to, 85.
oldest writing of, 60.
order of occurrence of cavities of various classes, 203, 208, 216, 225.
osmosis, re, 68.
pain caused by, 144.
pathology of, divorcement from clinical features, 91.
penetration of dentin by microörganisms, 69.
of enamel in buccal and labial surfaces, 90.
of enamel in pits and fissures, 76.
of enamel in proximal surfaces, 77.
of enamel in smooth surfaces, 77.
peridental membrance, disease of as result of, 103.
permanent teeth, during childhood period, 265.
physical characters of the teeth, re, 118.
physical examinations of the teeth, re, 120.
pits, decay in, 124.
points of beginning of, 75.
predisposition to, 115.
pregnant women, 117.
preparation of specimens, 83.
prevention of secondary extensions gingivally of proximal decays, 102.
principle governing beginnings in enamel, 75.
prophylactic treatment, 143, 182, 188.
proximal surface decays, conditions which cause food lodgments, 102.
in bicuspids, 97.
in incisors and cuspids, 107.
in incisors during childhood period, 272.
in molars, 93.
misplacement of beginnings, 100.
relation of form of to near approach of surfaces, 86.
relation of gum margin to, 87, 89.
relation of occlusion to, 85.
progress in dentin, 69.
limited by breaking of wall of cavity, 72.
limited by dead pulp or discharge of abscess through canals, 72.
limited by putrefactive decomposition, 72.
slowness of, 72.
progress in enamel, 74.
rapid progress of, in atrophy of first permanent molars, 25.
rare position of lingual decay, 112.
recession of gums, caries in cases of, 230.
treatment by filling, 231.
treatment with silver nitrate, 231.
recognition of susceptibility and immunity to, 137.
recurrence of, relation of restoration of proper contact to, 90.
Regnard, re, 63.
relation of form of proximal decays to areas of near approach of surfaces, 86.

Caries of the teeth (continued).
relation of gum margin to beginning decays of enamel, 87, 89.
relation of occlusion to beginning decays, 85.
relation of proximal surfaces to each other, 86.
relation of restoration of proper contact to recurrence of, 90.
relation of width of embrasures to proximal decay, 87.
resulting from absorption of interproximal gum tissue, 103.
resulting from interproximal wear, 104.
Robertson, re, 62.
ropy saliva, effect on, 136.
Röse, re, 131.
Rottenstein and Leber, re, 64.
roughening of surface of decayed area, 101, 102.
saliva, in relation to, 111, 129, 132.
salts dialized from, 69.
secondary extensions gingivally of proximal decays, 101.
sensitiveness caused by, 144.
separating files, decay resulting from use of, 103.
signs of susceptibility and immunity to, 137.
silver nitrate in treatment, 231, 248, 253.
softness of teeth, re, 118.
spreading, along dento-enamel junction, 69.
around the teeth, 113.
on proximal surfaces of bicuspids and molars, 81.
on smooth surfaces, 77.
on surface of enamel, 75.
staphylococcus, cause of, 73.
streptococcus, cause of, 73.
streptococcus media, cause of, 73.
studies of, 3.
utility of, 142.
sugar dialized from a solution, 69.
sulphocyanids in saliva, influence of, 131.
superficial spreading on surfaces of teeth, 81, 89, 113.
surfaces cleaned by friction of mastication, 85.
surfaces not cleaned by friction of mastication, 85.
susceptibility to, 115, 130.
changes in, 118.
conditions of, 130.
recognition of, 137.
swelling of decayed area of the enamel, 101.
swellings of tubules in caries of dentin, 71.
systemic conditions, effects of, 115, 121.
technical procedures in treatment of, 4.
Tomes, John, re, 63.
treatment of, 2, 188.
deciduous incisors and cuspids, 248.
deciduous molars, occlusal surface decays of, 253.
deciduous molars, proximal surface decays of, 254.
fillings, 190.
management of cavities by classes, 203.
prophylactic, by artificial cleaning, 188.
Underwood and Miles, re, 64.
utility of studies of, 142.
viscidity of the saliva, re, 136.
vital phenomena in, 144.
Williams, J. Leon, studies re, 128.
zigzag coccus, cause of, 73.
zoöglea aggregations, re, 111.
Cataphoresis, 149.
Cavities, classification of, 203.
management of by classes, 203.
first class, 204.
second, third and fourth classes, 208.
fifth class, 225.
Cavity walls, importance of dryness of, in filling, 192.
Cement, in filling atrophied first molars, 26.
in filling deciduous teeth, 252, 254.
in pulp capping, 206.
Cementing substance, between enamel rods, atrophy of, 35, 36, 38.
Changes in dentin and enamel resulting from early loss of pulp, 148.
Character of injuries to teeth in atrophy, 14, 23.
Chemical theory of dental caries, 63.
Chewing food, training in, to strengthen peridental membrane, 170.
Chewing foods, force used in, 161.
Childhood period of the permanent teeth, 258.
caries during, 265.
completion of apical foramina, 260.
eruption of the permanent teeth, 258.
growth of roots of the permanent teeth, 258.
intercusping of the first permanent molars, 262.
lingual pits in lateral incisors, 272.
open apical ends of root canals during, 275.
pulp removal often bad practice, 276.
removal of pulps in cases of delayed eruption, 261.
root filling, relation of age of patient to prognosis, 276.
special functions of the first permanent molars, 263.
succedaneous teeth, 259.
Child movement, 195.

Children's teeth, absorption of roots of deciduous teeth, 238, 239.
accidents during absorption of roots of deciduous teeth, 241.
a word as to handling of children, 251.
calcification of the deciduous teeth, 238.
cases which have been neglected until toothache has occurred, 256.
incisors and cuspids, treatment of decays of, 248.
by filing and silver nitrate, 248.
by temporary fillings, 252.
caution re use of silver nitrate, 251.
management of, 235.
molars, treatment of occlusal decays, 253.
by filling, 254.
by silver nitrate, 253.
molars, treatment of proximal decays, 254.
by filing, 254.
by filling, 255.
premature eruptions of teeth, 238.
proximity of pulps of deciduous teeth, 256.
psychic influence, 236.
relation of growth and shedding of the deciduous teeth to their treatment, 237.
retained deciduous cuspids, treatment of, 245.
retained deciduous molars, 245.
roots of deciduous teeth may be filled, when, 239.
treatment of, 247.
treatment of neglected cases, 256.
use of X-ray in treatment, 246.
Classification of cavities, 203.
Cleaning, artificial, prophylactic treatment of caries, 188.
by patient, in arresting caries, 143, 182.
which patient should do, 154.
Cleaning power of mastication, 167.
Cleanliness of proximal surfaces increased by changes of form, 219.
of the teeth, 154.
Clinical features of dental caries, as a whole, 91.
differences between proximal decays in bicuspids and molars, 98.
divorcement from pathology, 91.
gingival third decays, 109.
occlusal and proximal decays in bicuspids, 97.
occlusal decays in molars, 92.
pit and fissure decays, 92.
proximal decays in incisors, 107.
proximal decays in molars, 93.
Clinical thermometer in dental examinations, 178.
Color of teeth in atrophy, 11.
Comparative dental anatomy, nomenclature of, 4.
Composition of enamel, 122.
Composition of normal saliva, 133.
Contact, value of form of, in proximal fillings, 90, 222.
Crowding of food between the teeth, results of, 103.
Crowns and fillings cut by erosion, 47.
Crowns in treatment of erosion, 58.
Crystals of saliva, examinations of, 130.
Curative effect of fillings, 193.
Curled enamel, 123.
Cuspid teeth, see Incisor teeth.

Darby, re etiology of erosion, 54.
Deciduous teeth, see Children's teeth.
Definition of atrophy, 6.
of dental caries, 65.
of erosion, 39.
Deformities of the enamel other than atrophy, 32.
Dental caries, see Caries.
Dental nomenclature, 4.
Dentin, amount between enamel and pulp less than normal in atrophied teeth, 24.
caries of, 66, 68, 74, 91, 142.
conical area of caries in, 70.
disappearance of division walls of tubules in caries of, 71.
enlargement of tubules in caries of, 71.
failures in development of, 1.
hyperesthesia of, 217.
injuries during development of, 1.
injuries in atrophy, 17.
no change in, after once formed, 128.
obtunding sensitive, 148.
softened, filling over, 205.
Dentinal fibrils, effect of, on integrity and quality of dentin and enamel, 147.
how destroyed by caries, 148.
studies of, by Röse, 146.
Deposits on the teeth, 129.
Development of enamel and dentin, failures in, 1.
injuries during, 1.
Development of face, effect of first permanent molars on, 263.
Development of teeth, failure of, 6.
Diagnosis, 178.
atrophy, 6, 185.
caries, 180.
erosion, 40, 185.
facial neuralgia, 184.
food lodgments, 183.
gingival margin, disease of, 185.
hyperemia of pulp, 184.
mucous membrane, disease of, 179.
pain, 183.
thermal sensitiveness of peridental membrane, 184.
Dialysis of saliva, 69.
Discoloration of atrophied teeth, 18.

Disease beginning at gum margin, as cause of tenderness of peridental membrane, 169.
Disease of gingival margin, diagnosis of, 185.
Disease of peridental membrane as a result of absorption from interproximal wear, 106.
Disease of peridental membrane, etiology, 169.
Diseased glands, secretion of, as cause of erosion, 49, 53.
Diseased tooth pulps, as cause of tenderness of peridental membrane, 169.
Dish-shaped areas of erosion, 42.
Dryness of cavity walls, importance of, in filling, 192.
Duddei, Augustin, German translation of Fouchard, 62.

Education of the public by the dentist, 154.
Embrasures, relation of width of, to proximal decays, 87.
Enamel, backward decay of, 66.
caries of, 65, 74, 83, 91, 142.
composition of, 122.
curled, 123.
deformities of, other than atrophy, 32.
difference in hardness and softness of, 122.
injuries during development, 1.
injuries to, in atrophy, 8, 15.
no change in, after once formed, 128.
spots in, in atrophy, 30, 38.
straight, 122.
telescoping of, in atrophy, 15.
Enzyme of microörganisms as cause of erosion, 49, 55.
Erosion of the teeth, 39.
absorption, as cause of, 49, 54.
acid, as cause of, 49, 52.
alkaline fluids, as cause of, 49, 55.
author's experiments re cause of, 53.
Bell, re cause of, 50.
crowns and fillings cut by, 47.
crowns in treatment of, 58.
Darby, re cause of, 54.
definition, 39.
diagnosis, 40.
diseased glands, secretion of, as cause of, 49, 53.
dish-shaped areas, 42.
enzyme of microörganisms as cause of, 49, 55.
etiology, 49.
faults in formation of tissues during growth as cause of, 49, 50.
figured areas, 46.
fillings and crowns, cut by, 47.
fillings in treatment of, 57.
final statement re cause of, 56.
flattened areas, 44.
forms of, 42.
Fox, re cause of, 50.
frequence of, 41.
friction as cause of, 49, 50.
Garretson, re cause of, 50.
gouty diathesis, acid associated with, as cause of, 49, 54.
Hunter, John, re cause of, 50.
illustrations, selection of cases for, 48.
irregular areas, 46.
"Keilformege defecte," 43.
Kirk, E. C., re cause of, 54.
Koch, C. R. E., re cause of, 50, 55.
Microörganisms as cause of, 49, 55.
Miller, W. D., re cause of, 51, 52.
position of, 39.
Preiswork, re cause of, 55.
progress of, 39.
proximal surfaces, of, 48.
secretion of diseased glands as cause of, 49, 53.
sensitiveness, treatment of, 58.
Tomes, John, re cause of, 50.
treatment, 57.
treatment of sensitiveness, 58.
wedge-shaped areas, 43.
Eruption of permanent teeth, 258.
Eruptions of deciduous teeth, premature, 238.
Esthetic considerations in treatment of caries, 232.
Etiology of atrophy, 11.
of caries, 68.
of erosion, 49.
Examinations of the mouth, 178.
Exposure and capping of pulp of first molar during childhood period, 270.
Extension for prevention, application of, 143.
limitations of, 214.
of gingival third cavities, 227.
of proximal cavities, 211.
of proximal cavities in incisors during childhood period, 273.
Evaporation in drying cavity walls, 192.
Eyes of the dentist, care of, 172, 173.

Face, growth and development of, effected by first permanent molars, 263.
Facets produced by interproximal wear, 105.
Facial neuralgia, diagnosis, 184.
Failure in development of the teeth, 1, 6.
Faults in formation of tissues during growth as a cause of erosion, 49, 50.
Faults in the structure of the enamel, 124.
Faulty structure of teeth not a cause of decay, 124.
Festoons of gums, swellings of, 185.
Figured areas in erosion, 46.
Filing in treatment of decays of deciduous incisors and cuspids, 248.
molars, 254.

Filling, effect of, on superficial spreading of caries, 89.
in cases of atrophy, 25.
in cases of recession of gums, 231.
operations, esthetic considerations in, 232.
over softened dentin, 205.
requirements in, to be successful, 191.
Fillings, cut by erosion, 47.
in treatment of atrophy, 25.
in treatment of dental caries, 190.
curative effect of, 193.
must be watertight, 191.
prophylactic value of, 194.
selection of material for, 198.
what should be considered permanent, 195.
in treatment of erosion, 57.
First permanent molars, atrophy of, 8, 23.
caries of, during childhood period, 265.
deep cavities in, 268.
exposure and capping of pulp during childhood period, 270.
hyperemia of pulp of, 269.
importance of early filling of pit and fissure cavities, 268.
intercusping of, 262.
mesial surface cavities in, 271.
relation of depth of decay to pulp, 267.
special functions of, 263.
time of loss important, 266.
Fissure and pit cavities, clinical features, 92, 97.
conditions under which fillings should not be made, 207.
importance of early treatment, 207.
in bicuspids, 206.
in molars, 204.
management of, 204.
penetration of enamel in, 76.
Fissures in the enamel, 124.
caries in, 124.
Flattened areas in erosion, 44.
Food, force required in mastication of, 165.
lodgments, causing pain as a result of chewing, 183.
lodgments, in the interproximal space, 220.
Foods, force used in chewing, 161.
Foramina, apical, completion of, 260.
Force required in the mastication of food, 165.
used in chewing foods, 161.
used in mastication in relation to strength and health of peridental
Form of decays of dentin, 70.
Form of decays of dentin, 70.
of enamel beginning in pits, 77.
of enamel, beginning in smooth surfaces, 80.
Forms of erosion, 42.
Fouchard, re dental caries, 62.
Fox, re etiology of erosion, 50.
re dental caries, 62.
Frequence of atrophy, 23.
of erosion, 41.
Friction as a cause of erosion, 49, 50.
Functions, special, of the first molar, 263.
Fungus, caries, 73.

Garretson, re etiology of erosion, 50.
Gelatinous masses on the teeth, 129.
Gelatinous plaques in relation to gingival third decays, 111.
General deformity of enamel, 32.
General statement re dental caries, 65.
Gingival margin, diseases of, diagnosis, 185.
Gingival third cavities, area of liability, 85, 113, 227.
extension for prevention, 227.
in cases of recession of gums, 230.
in middle age, 229.
in young persons, 227.
management of, 225.
Gingival third decays, 109.
intermittent progress of, 111.
relation of gelatinous plaques to, 111.
relation of gum margin to, 89.
relation of occlusion to, 85.
saliva, effect of, favoring certain deposits, 111.
several teeth often attacked, 90.
Gingivitis, simple, 186.
Glasses for the eyes of the dentist, 173.
Glossary, 279.
Glutinous deposits from the saliva, 136.
Gnathodynamometer, records on, 163.
Gold as a filling material, 198.
Gold cap for atrophied first permanent molars, 27.
Gold fillings, when peridental membranes are abnormally sensitive, 169.
Gouty diathesis, acid associated with, as cause of erosion, 49, 54.
Granular layer of Tomes, 69, 125.
Growth and development of face, effect of first permanent molars on, 263.
Growth and shedding of deciduous teeth in relation to their treatment, 237.
Growth of roots of permanent teeth, 258.
Gums, calcic inflammation of, 186.
recession of, caries in case of, 230.
treatment by filling, 231.
treatment with silver nitrate, 231.
swellings of festoons of, 185.
Gutta-percha, filling deciduous teeth, 252.

Hardness of teeth, 118.
to cutting instruments, 122.
Haversian systems in bone, 126.
Hereditary predisposition to caries, 116.
conditions that influence, 116.
stronger in youth, 117.
Hereditary predisposition to disease, 116.

Historical, caries of the teeth, 60.
Hill's stopping in filling deciduous teeth, 252.
Histological characters in atrophy of the teeth, 14.
Howship, lacunæ of, 127.
Hunter, John, re dental caries, 62.
re etiology of erosion, 50.
Hutchison, re atrophy, 11.
Hutchinson teeth, 7, 11.
Hyaline area of Tomes, 93, 95, 108.
Hyper-acid saliva, 130.
Hyperemia of pulp, 184.
of first permanent molar during childhood period, 269.
Hyperesthesia of dentin, 217.
Hypersensitiveness of peridental membranes, 168.
Hypersensitiveness to thermal changes, 150.
Hypertrophy of the gingivæ, 186.
Hypo-acid saliva, 130.
Hypoplasia of the teeth, 6.

Illness, effect of, on the development of the teeth, 6.
Immunity to dental caries, 3, 115, 130.
changes in, 118.
influence of sulphocyanids in saliva, 131.
of axial angles of the teeth, 88, 90.
recognition of, 137.
Imperfect formation of the teeth, 6.
Incisor teeth, see Atrophy, Childhood period of permanent teeth, Children's teeth, Gingival third cavities, Proximal cavities.
Injuries by interproximal wear, 104.
Injury by use of the tooth brush, 157.
Intercusping of first permanent molars, 262.
Interglobular spaces in dentin in atrophy, 17, 24.
in caries, 69, 125.
Interproximal contact, value of form of, 222.
Interproximal gum septum, health of, 222.
Interproximal gum tissue, absorption of, 103, 106.
Interproximal space, food lodgments in, 220.
Interproximal wear, caries as result of, 106.
injuries by, 104.
Introduction, 1.
Inverted finger nail deformity in atrophy, 10.
Irregular areas in erosion, 46.
Irregularities caused by failure of proper intercusping of first permanent molars, 262.

"Keilformege defecte" (wedge-shaped defects), in erosion, 43.
Kirk, E. C., re etiology of erosion, 54.
Koch, C. R. E., re etiology of erosion, 50, 55.
Köeker, re dental caries, 62.

Labial and buccal cavities, see Gingival third cavities.
Labial and buccal surfaces, examinations of, 181.
value of artificial cleaning by patient, 189.
Lateral abscess, 187.
Lateral incisors, lingual pits in, during childhood period, 272.
pulps large compared with size of teeth, 276.
Leber and Rottenstein, re dental caries, 64.
Leptothrix buccalis, 140.
Leptothrix of Vignon, 140.
Ligature, for cleaning the teeth, 158.
in examinations for proximal cavities, 181.
Light, management of, 172.
Limitations of the force of the occlusion, 162.
Lines of accretion in atrophy, 14, 16.
Lines of contemporaneous calcification of the teeth as modified in atrophy, 14.
Lingual pits in lateral incisors during childhood period, 272.
Localizations of beginnings of caries in enamel, 74.
Location of nidus of each beginning of caries, 89.
Locations of atrophy on the teeth, 7, 10, 14.
Lodgments of food in the interproximal space, 220.
Lodgments which do not cause gingival third decays, 111.
Loss of length of arch by interproximal wear, 104.

Magitot, re atrophy, 11.
re dental caries, 64.
Malnutrition as cause of atrophy, 11.
Management of cavities by classes, 203.
Management of children's teeth, 235.
Management of light in dental operations, 172.
Management of patients, 153.
Mastication, cleaning power of, 167.
force used in, 161.
lack of proper and normal, as cause of tenderness of peridental membrane, 169.
of food, force required in, 165.
Measles as a cause of atrophy, 13.
Mesio-distal breadth of teeth, importance of restoration of, in filling, 222, 223.

Method of preparing specimens of caries, 83.
Michaels, Joseph P., re sialo-semeiology, 129, 133.
Micrococcus irregularis, 140.
vaginatus, 140.
Microörganisms, as cause of erosion, 49, 55.
exclusion of, does not prevent recurrence of decay, 191.
in caries of dentin, 71, 73.
in caries of enamel, 74.
limit of superficial spreading of colonies of, 89.
of the mouth, 138.
Miles and Underwood, re dental caries, 64.
Miller, W. D., re dental caries, 65.
re etiology of erosion, 51, 52.
re experiments, growth of microörganisms of caries, 71.
re investigations of dental caries, 91.
re microörganisms of mouth, 139.
re studies of dental caries, 142.
re tooth powders, 157.
Misplacement of beginning proximal decays, 100.
Modification of the curve of the line of the dento-enamel junction in atrophy, 18.
Moisture, removal of, from cavity walls, 192.
Molar teeth, see Atrophy, Childhood period of permanent teeth, Children's teeth, First permanent molars, Gingival third cavities, Pit and fissure cavities, Proximal cavities.
Mouth, examinations of, 178.
not rendered aseptic by antiseptic washes, 158.
washes, 157.
Mucous membranes of mouth, examination of, 179.

Near approach of surfaces in relation to form of proximal surface decays, 86.
Necessity of closer study of beginnings of caries, 143.
Neuralgia, facial, diagnosis, 184.
New York State Dental Society, studies of saliva by committee of, 131, 136.
Nidus of each beginning of caries, location of, 89.
Nomenclature, of comparative dental anatomy, 4.
dental, 4.
Normal saliva, 130.
Numbers of species of microörganisms of the mouth, 138.
Nutrition, effect of, on the development of the teeth, 6.
Nutritional changes in bone, 126.

Observations of cases of atrophy, 12.
Obtunding sensitive dentin, 148.
Occlusal surface cavities, management of, 204.
clinical features, 92.
conditions under which fillings should not be made, 207.
examination for, 181.
importance of early discovery and treatment, 97, 207.
in bicuspids, 97, 206.
in molars, 92, 207.
Occlusion, force of, 161.
Occlusion, relation of, to beginning decays of enamel, 85.
Oldest mention of gold for filling teeth, 61.
Oldest writing of dental caries, 60.
Open apical ends of root canals during childhood period, 275.
Order of occurrence of cavities of various classes, 203, 208, 216, 225.
Osmosis, 68.
Overlapping of enamel in atrophy, 15.
Oxyphosphate of copper cement for filling atrophied first molars, 26.
for filling children's teeth, 254.
Oxyphosphate of zinc as pulp capping, 206.

Pain caused by dental caries, 144.
in chewing food, as a result of food lodgments, 183.
in oral region, diagnosis, 183.
Pathology, divorcement of, from clinical features of caries, 91.
Patients, cleaning of teeth by, 154.
management of, 153.
management of children, 235.
Penetration of dentin by microörganisms, 69.
Penetration of enamel in buccal and labial surfaces, 90.
in pits and fissures, 76.
in proximal surfaces, 77.
in smooth surfaces, 77.
Pericementitis, phagedenic, 186.
Peridental membrane, danger of injury to, by ligatures around incisors, 107.
disease of, as result of absorption of interproximal gum tissue, 103.
disease of, as result of interproximal wear, 106.
disease of, in relation to force of bite, 162.
hypersensitiveness of, 168.
sensitiveness of, 168.
strength and health of, in relation to force used in mastication, 161.
tenderness of, 169.
thermal sensitiveness of, 184.
training in chewing food to strengthen, 170.
Permanence of fillings, conditions affecting, 195.

Permanent fillings, in atrophied first molars, 28.
Permanent fillings, meaning of, 195.
Permanent teeth, caries of, during childhood period, 265.
childhood period of, 258.
delayed eruption of, by deciduous teeth, 243.
injuries to, by abscesses of deciduous teeth, 243, 244.
Phagedenic pericementitis, 186.
Phagodynamometer, records on, 165.
Physical characters of the teeth, 118.
Physical examinations of the mouth, 178.
of the teeth, 120.
Physiological and pathological differences between bone and dentin, 126, 191.
Physiological conditions of teeth and bone compared, 191.
Physiological repair in dentin, no process of, 128.
Pit and fissure cavities, clinical features, 92, 97.
conditions under which fillings should not be made, 207.
importance of early treatment, 207.
in bicuspids, 206.
in molars, 204.
management of, 204.
penetration of enamel in, 76.
Pits in enamel, 124.
caries in, 124.
in atrophy, 30.
Photograph, note re use of word, 16, 77.
Photomicrograph, note re use of word, 16, 77.
Platinum-gold foil in treatment of abrasion, 201.
Points in localization of beginnings of caries of enamel, 75.
Porcelain inlay as a filling material, 201.
Portion of the teeth affected by atrophy, 7.
Position of erosion, 39.
Powders for the teeth, 157.
Predisposition to dental caries, 115.
to disease, 115.
Pregnant women, caries in teeth of, 117.
Preiswerk, re etiology of erosion, 55.
Prevention of secondary extension gingivally of proximal decays, 102.
Principle governing beginnings of caries of enamel, 75.
Prisms, use of, for the eyes, 177.
Progress of caries in dentin, 69.
limited or stopped how, 72.
Progress of caries of enamel, 76.
Progress of erosion, 39.
Prophylactic treatment of caries, 143.
by artificial cleaning, 188.
by patient, 182.
Prophylactic value of fillings, 194.
of form in proximal fillings, 222.
Prophylaxis, 154.
mastication as factor in, 167.
Proximal fillings, prophylactic value of form in, 222.
Proximal surface cavities, area of liability, 81, 85, 113, 210.
conditions which cause food lodgments, 102.
examinations for, 181.
extension for prevention, 211.
food lodgments in interproximal space, 220.
form of surface in relation to cleanliness, 219.
in bicuspids and molars, clinical features, 93, 97.
importance of early discovery, 98.
in highly susceptible persons, 215.
in incisors and cuspids, clinical features, 107.
danger of pulp exposure, 273.
during childhood period, 272.
importance of early attention to, 109.
open apical ends of root canals, 275.
in middle age, 217.
limitation of extension for prevention, 214.
management of, 208.
misplacement of beginnings, 100.
prophylactic value of form in proximal fillings, 222.
Proximal surfaces, erosion of, 48.
Prunty's case of white enamel, 35.
Psychic conditions in patients, 153.
Public, education of, by the dentist, 154.
Pulp, danger of exposure in atrophy, 24.
death of, from thermal sensitiveness, 152.
disease of, as cause of tenderness of peridental membrane, 169.
hyperemia of, 184.
importance of early removal of, after death from thermal sensitiveness, 152.
loss of, in relation to force of bite, 162.
of atrophied incisors and cuspids closer to incisal edge than normal, 29.
of deciduous teeth, proximity of, to enamel, 256.
of first permanent molar, relation of to depth of decay, during childhood period, 267.
capping, during childhood period, 270.
hyperemia of, during childhood period, 269.
of incisors, danger of exposure during childhood period, 273.
of upper lateral incisors, 274, 276.
oxyphosphate of zinc capping for, 206.
removal of, in cases of delayed eruption, 261.
removal of, often bad practice, 276.
Pulse, in dental examinations, 178.

Putrefaction, 141.
Putrefactive decomposition and disease of peridental membrane as result of absorption of interproximal gum tissue, 103.
as result of interproximal wear, 106.
Pyorrhea alveolaris, 186.

Rapidity of progress of caries of dentin, 72.
Rare position of lingual decay in a cuspid, 112.
Reaction of the mucus of the mouth, 132.
Reaction of the saliva, 132.
Recession of gums, 186.
caries in cases of, 230.
treatment by filling, 231.
treatment with silver nitrate, 231.
Recessional line of pulpal horn, 95.
Recognition of susceptibility and immunity to dental caries, 137.
Recurve of line of dento-enamel junction in atrophy, 18.
Redness, general, of gingivæ, 185.
Regnard, re dental caries, 63.
Relation of form of proximal decays to area of near approach of surfaces of the teeth, 86.
Relation of growth and shedding of the deciduous teeth to their treatment, 237.
Relation of gum margin to beginning of decays of enamel, 87, 89.
Relation of occlusion to localization of caries, 85.
Relation of proximal surfaces of teeth to each other, 86.
Relation of restoration of contact and mesio-distal breadth to recurrence of caries, 90.
Relation of width of embrasures to proximal decays, 87.
Repair in human teeth, no process of, 6.
Repair of absorptions of portions of teeth, 127.
Results of absorption of interproximal gum tissue, 103.
Results of interproximal wear, 104.
Retained deciduous teeth, 245.
Ritzeus, lines of, in atrophy, 14, 16.
Robertson, re dental caries, 62.
Root, atrophy of, 20.
Root canals of teeth, apical ends open during childhood period, 275.
Root fillings, in deciduous teeth may be made when, 239.
relation of age of patients to success, 276.
Roots of permanent teeth, growth of, 258.
Roots of teeth well developed in atrophy, 11.
Ropy saliva, 135.
effect of, on dental caries, 136.
Röse, Carl, studies of dentinal fibrils, 146.
studies of saliva, 131.
Rottenstein and Leber, re dental caries, 64.
Roughening of surface of decayed area, 101, 102.
Rubber bands for cleaning teeth, 158.

Saliva, 132.
effect of, favoring deposits on the teeth, 111.
examination of crystals, 130.
salts dialized from, 69.
studies of, by Dr. Michaels, 129.
Salts dialized from saliva, 69.
Scarlet fever as cause of atrophy, 13.
Secondary extensions gingivally of proximal decays, 101.
Secretion of diseased glands as cause of erosion, 49, 53.
Selection of filling material, 198.
Self-limiting diseases, 117.
Sensation in dentin, 146.
Sensitiveness, caused by dental caries, 144.
in erosion, 40, 58.
of normal dentin, 145.
of peridental membrane, 168.
thermal, 219.
Separating files, results of use of, 103.
Shedding and growth of deciduous teeth in relation to their treatment, 237.
Shortening of teeth in atrophy, 17.
Sialo-semeiology, 129.
Signs of susceptibility and immunity to dental caries, 137.
Silver nitrate, treatment of decays of deciduous incisors and cuspids, 248.
caution re use of, 251.
treatment of caries in cases of recession of gums, 231.
treatment of occlusal decays of deciduous molars, 253.
Simple gingivitis, 186.
Slowness of progress of caries of dentin, 72.
Smith's case of general deformity of enamel, 34.
Smooth surface cavities, see Gingival third cavities, Proximal surface cavities.
Softened dentin, filling over, 205.
Softness of teeth, 118.
to cutting instruments, 122.
Soft tissues of mouth, examination of, 179.
Specimens showing injury to enamel, method of preparing, 83.
Spreading of dental caries, along dento-enamel junction, 69.
around the teeth, 113.
on smooth surfaces, 77.
on surface of enamel, 75, 113, 114.
Staphylococcus, cause of caries, 73.

Straight enamel, 122.
Streptococcus buccalis, 139.
Streptococcus, cause of caries, 73.
Streptococcus continuosum, 140.
Streptococcus media, 139.
  as cause of caries, 73.
Subperiosteal bone, 126.
Succedaneous teeth, 259.
Sugar, dialized and crystallized, 69.
Sulphocyanids in saliva, influence of, 131.
Superficial spreading of caries around angles of teeth, 113.
  effect of falling away of enamel rods on, 89.
  on smooth surfaces, 77.
  on surface of enamel, 75, 113, 114.
  relation of artificial cleaning to, 89.
Surfaces of teeth cleaned by mastication, 85.
Surfaces of teeth not cleaned by mastication, 85.
Susceptibility to dental caries, 115, 130.
  changes in, 118.
  influence of sulphocyanids in saliva, 131.
  recognition of, 137.
Swelling of decayed area of enamel, 101.
Swelling of tubules in caries of dentin, 71.
Syphilis as cause of atrophy, 7, 11, 13.
Systemic conditions, affecting dental caries, 115, 121.

Tape for cleaning teeth, 158.
Technical procedures in treatment of caries, 4.
Teeth, comparison of physiological conditions of, with bone, 191.
  examination of, 178.
Telescoping of enamel in atrophy, 15.
Temperature, in dental examinations, 178.
Temporary teeth, see Children's teeth.
Tenderness of carious cavities cause of tenderness of peridental membrane, 169.
Tenderness of peridental membrane, causes of, 169.
Tests of force of bite, 163.
Tetrogenous, 140.
Thermal sensitiveness, 150, 219.
  of peridental membrane, 184.
Thermometer, clinical, in dental examinations, 178.
Tomes, John, re dental caries, 63.
  hyaline area of, 93, 95, 108.
  re etiology of erosion, 50.
Tooth brush, injury by use of, 157.
  use of, 155.
Tooth pick, 158.
Tooth powders, 157.
Treatment, of atrophied teeth, 25.
  of children's teeth, 235.
  of erosion, 57.
  of dental caries, 188.
  of interproximal wear, 105, 106.
  of sensitive dentin, 148.
  of sensitiveness in erosion, 58.
  of tenderness of peridental membrane, 169.
  of thermal sensitiveness, 151.
Tubules of dentin, disappearance of division walls in caries, 71.

Underwood and Miles, re dental caries, 64.
Use of teeth in relation to force of bite, 162.
Utility of studies of dental caries, 142.

Variations, as to deposits from saliva, 133.
  in quantity of saliva, 131.
  in salts of saliva, 131, 133.
  in viscidity of saliva, 133.
Viscidity of saliva, 135.
  effect of, on dental caries, 136.
Vision, of the dentist, 173.
Vital phenomena in caries, 144.
Vitality of the teeth, effect of, on dental caries, 144.

Walkhoff, re atrophy, 19.
Washes, mouth, 157.
Water, removal of, from cavity walls, 192.
Wedge-shaped areas in erosion, 43.
Wedl, re atrophy, 19.
White enamel, 35.
White spots in enamel, 34.
Whooping cough as cause of atrophy, 13.
Williams, J. Leon, studies re dental caries, 128.

X-ray, use of, in treatment of deciduous teeth, 246.

Zigzig coccus, 140.
  as cause of caries, 73.
Zoöglœa aggregations, in relation to gingival third decays in buccal and labial surfaces, 111.
Zsigmondy, re atrophy, 19.

Date Due

Demco 293-5

YALE MEDICAL LIBRARY
3 9002 01121 9897

Accession no.
Author
Black, Greene
A work on
operative dentistry.
I. Pathology...
Call no.
Hist AK 501
B63
1908
1
Locked